



## Management of Horizontal Root Fracture: A Case Report

Neda Jafarzadeh<sup>1</sup>, Maryam Zare Jahromi<sup>2\*</sup>, Leila Ebrahimian<sup>3</sup>

Received: 2024-08-13/ Accepted: 2025-01-04 / First publication date: 2025-05-20

© The Author(s) 2025

### Abstract

**Background:** A horizontal root fracture features a fracture line perpendicular or oblique to the root's long axis, affecting less than 3% of dental injuries. Classification, diagnosis, and prognosis depend on the root's developmental stage, the number and location of fracture lines, and fragment displacement. This case report discusses the clinical and radiographic findings of two successfully managed horizontal root fractures in maxillary incisors using different treatment approaches.

**Methods:** A 16-year-old boy who had a motorcycle accident 4 months ago was referred to us with a tooth abscess. Both right and left central incisors showed a fracture line at the junction of the middle and apical thirds without dislocation. Based on the condition of the pulp in each tooth, two different treatment options were recommended. The left incisor was non-vital, had intra oral swelling and a draining sinus tract; therefore, it was treated endodontically with an MTA plug, gutta-percha and sealer. In contrast, the right incisor was vital, and the treatment plan for this tooth was simply to monitor its vitality. Both teeth were monitored clinically and radiographically over the course of one year. Success was assessed by the absence of pulpal and periapical inflammation, as well as the presence of a functional and healthy periodontium along the fracture lines of both fragments, despite the differing treatment plans.

**Conclusion:** This case report underscores the importance of performing an intraoral clinical examination, as well as vitality and periradicular tests, in conjunction with radiographic evaluation whenever a root fracture is detected.

**Keywords:** Incisors; Maxilla; Root canal therapy; Tooth Fractures

### Introduction

Dental traumas are injuries to the teeth, periodontium, and surrounding soft tissues. They are quite common in dentistry. Children and adolescents experience mild or severe dental traumas from various causes (1, 2). According to Andersson, the prevalence of traumatic dental injuries (TDIs) in children and adolescents is approximately 20% and varies little (3). Petti et al (4) found that traumatic

dental injuries occur in both primary and permanent dentitions, although the prevalence in primary dentition is higher. Prevalence differs with age and sex, with a global male-to-female ratio of 1.43, suggesting that men are more likely to develop TDI than are women.

Traumatic dental emergencies include tooth fractures, luxations, and avulsions. Tooth fractures in permanent teeth are relatively rare, making up about 0.5% to 7% of reported dental trauma cases (5). Root fractures are identified through clinical evaluations and radiographic examinations. The treatment for these fractures varies based on the fracture's location, the degree of root involvement, accurate diagnosis, clinical management, and the need for follow-up imaging (6).

Horizontal root fractures are defined by a fracture line that runs perpendicular to the long axis of the root. Horizontal root fractures occur in less than 3%

Corresponding author: Maryam Zare Jahromi

Department of Endodontics, Faculty of Dentistry ,Isf.C, Islamic Azad University, Isfahan, Iran  
Email: maryamzare@iau.ac.ir

<sup>1</sup> Department of Endodontics, Faculty of Dentistry ,Isf.C, Islamic Azad University, Isfahan, Iran

<sup>2</sup> Department of Endodontics, Faculty of Dentistry ,Isf.C, Islamic Azad University, Isfahan, Iran

<sup>3</sup> Department of Endodontics, Faculty of Dentistry ,Isf.C, Islamic Azad University, Isfahan, Iran

of all dental injuries, of which the most common were fractures at the middle third of the root (57%), followed by the apical third of the root (34%) and cervical third of the root (9%) (7). Due to the position of the maxillary central incisor in the dental arch, the chance of occurrence of traumatic dental injuries is higher in these teeth (approximately 68%). This is followed by maxillary lateral incisors (27%) and mandibular incisors (5%) (6).

Although the outcome of a root fracture treatment is generally favorable (60–84% cases), complications such as pulp necrosis, radicular resorption, and pulp canal obliteration can arise (7). Andreasen et al. (8, 9) in their study found that necrosis of pulp after horizontal root fracture occurs in nearly 25% of the cases. The prognosis is directly related to coronal fragment displacement, stage of root and pulp development, type of splinting, and fracture localization (7).

In a classic study, noted four types of healing after horizontal root fractures, and only one was associated with pathology (1):

1. Hard tissue healing, most commonly found in root-fractured teeth, in which the coronal fragment is not or is only slightly dislocated.
2. Connective tissue healing, with a bone-like structure between the fragments.
3. Connective tissue healing without bone, often resulting from lateral dislocation or extrusion of the coronal fragment.
4. Granulation tissue interposition occurs as a result of infected or necrotic pulpal tissue, causing an inflammatory reaction in the fracture line (7).

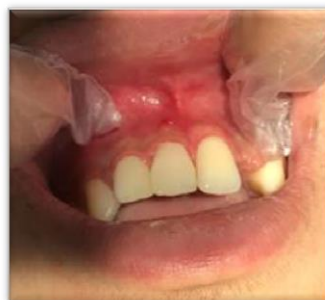Root-fractured teeth in children and adolescents, or root-fractured teeth with a minimum dislocation of the coronal fragment, regardless of the patient's age, should not be treated endodontically prophylactically. Rather, pulp healing should be carefully observed for a minimum of one year (7). Splinting of teeth is done whenever required by repositioning and stabilizing the teeth in their correct position. Following this injury, periodic checking of teeth is done to evaluate the vitality of the pulp. But evaluation of pulp vitality can be difficult in these cases because actual pulp vitality can be determined even after several months and vitality test does not indicate the true status of the pulp (6).

This article presents management of left and right central horizontal root fractures. The right and left central incisors received a fracture at the junction of the middle and apical thirds, with almost no

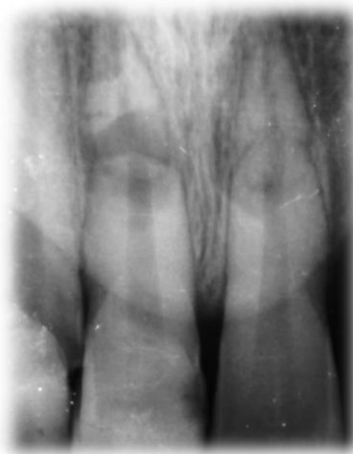dislocation. Based on the pulpal condition of each tooth, two treatment methods were performed: The left incisor revealed an intra-oral local swelling and draining sinus tract. Due to the nonvitality of this tooth, we decided to treat it endodontically. But as the right incisor was vital, the treatment plan for this tooth was just monitoring its vitality in each visit.

### Case report

A 16-year-old boy was referred to the Faculty of Dentistry of Islamic Azad University with a Chief complaint of tooth abscess after a motorcycle accident 4 months ago. Intraoral and radiographic examination revealed a local swelling and draining sinus tract (Figure 1), teeth #8,9 had no history of caries, restorations and RCT but tooth #7 had a Composite filling, and tooth #10 was missing (Figure 1, 2), which was mobile due to accident and extracted in hospital. lip stitches were seen consistent with the place of extraction. He had no history of systemic disease, hospitalization or drug use, or allergic reaction.



**Figure 1.** Intraoral view of the swelling



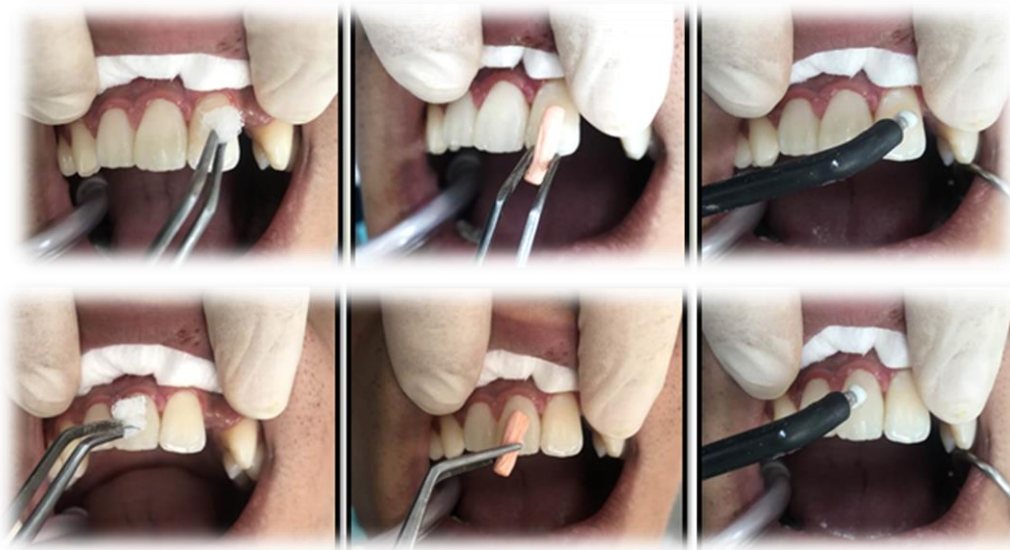**Figure 2.** Initial radiographic view of the swelling area.

Vitality test and periradicular tests were performed for maxillary and mandibular anterior teeth (Table 1, Figure 3). A cold test was done with Cold spray (Luber Cool, Iran), and EPT was done with Digitest

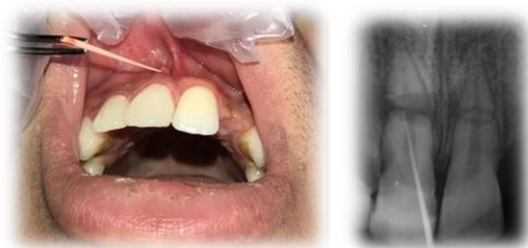II Digital Pulp Vitality Tester (Parkell, America). In addition, tracing with gutta-percha #25 was done, and it showed a lesion of tooth #8 in the location of root fracture (Figure 4).

**Table 1.** Vitality test and periradicular tests.

Mobility	Tooth number	Palpation	Percussion	EPT	Heat test	Cold test
normal	8	-	+	10	-	-
normal	9	-	-	3	-	+
normal	7	-	-	2	-	+
normal	24	-	-	2	-	+



**Figure 3.** Left column: cold test, middle column: heat test, right column: EPT.

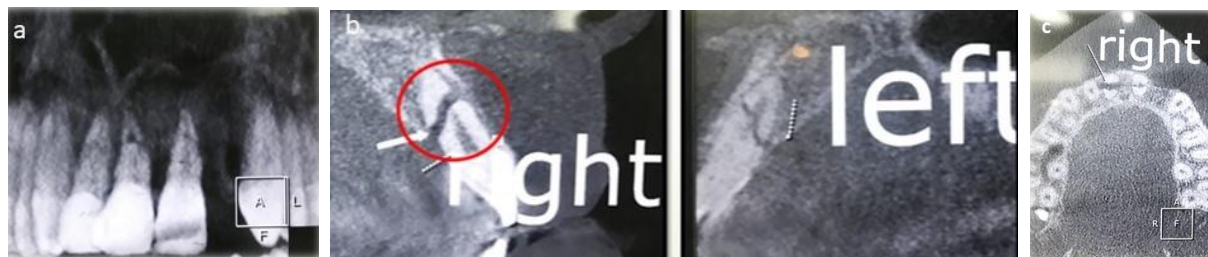


**Figure 4.** Tracing of the lesion.

After multiple evaluations, we found that the coronal part of tooth #8 was necrosed, and periradicular diagnosis for this tooth was chronic apical abscess.

Teeth #7, 9 were vital, and they had normal periradicular tissues.

The initial radiographic exam was done, and CBCT was requested. Sagittal view showed that the coronal part of tooth #8 was separated from the apical part. Distance and space due to root fracture and root resorption, and bone loss in tooth#8 were obvious, but coronal and apical segments of tooth#9 did not show dislocation (Figure 5b). Fracture line was seen in axial view of both teeth#8,9, but it was larger in tooth#8. Root resorption and bone loss were clear in tooth #8 (Figure 5c ).

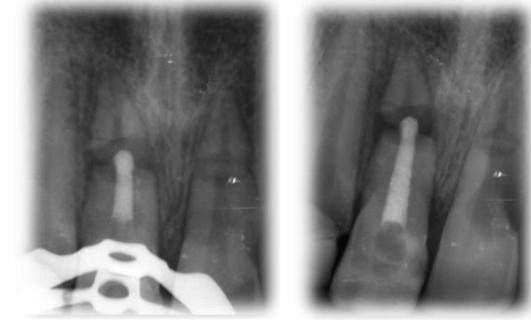


**Figure 5.** a) Coronal view. b) Sagittal view. c) Axial view.

Treatment plan for tooth #8 was nonsurgical root canal treatment (MTA plug, MTA Angelus, Brazil) and long-term follow-up, occlusal adjustment, and composite filling of the access cavity. In the treatment procedure, cleaning and shaping were done up to #80 hand k-file, and irrigation was done with 0.5% NAOCL in the coronal part of a tooth. we considered tooth #8 as an open apex tooth, and MTA condensation was done to a length of 4 mm. According to the guidelines of Andreasen and Cohen's pathways textbook, the apical part of the tooth might remain vital, so we did not do any treatment for it, and only follow-up was required (9-12). Then sealer was applied to the remaining part of the canal and gutta-percha was injected with fast fill obturator (Eighteenth fast fill obturator, China) up to cement enamel junction level (Figure 6)(13).

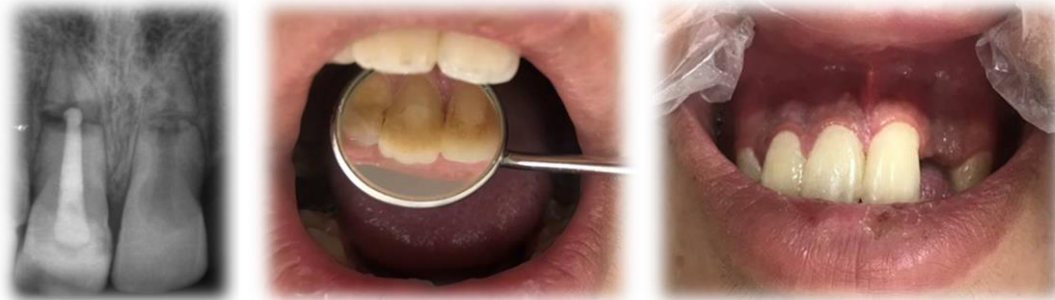Treatment plan for tooth #9 was just follow up and performing vitality test in each visit, because it was asymptomatic, and pulp and periradicular tests in this tooth were normal. On the other hand, this tooth did not show any mobility, so it did not need tooth splinting or any other treatment. For the space of tooth #10, consultations were done with the periodontics and restorative departments. Considering the young age of the patient, we decided to postpone the implant treatment, and the space of tooth #10 was filled with FRC Bridge (Angelus FRC Interlig, Brazil, and Tokuyama composite, Japan) in the restorative department. To enhance the bridge's durability, we

ensured it was not placed in occlusal contact.



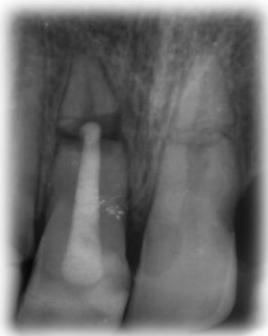**Figure 6.** MTA plug & canal obturation

According to AAE guidelines, follow-up for root fractures should be performed at week 4, week 6-8, and then 4 months, 6 months, and 1 year. These guidelines are generally recommended for recent fractures. But our patient did not cooperate with follow-up visits, and we had to perform the necessary tests whenever the patient was able to visit. Therefore, our patient follow-up sessions are slightly different from the suggested program. After 2 months of clinical and radiographic follow-up, tooth #8 had no signs or symptoms and no evidence of ankylosis. The extent of radiolucency was reduced, but still present. The sinus tract was closed, and periapical mucosal tissues were normal. Vitality test of tooth #9 was normal, the fracture line did not change and the tooth had no mobility (Figure 7).



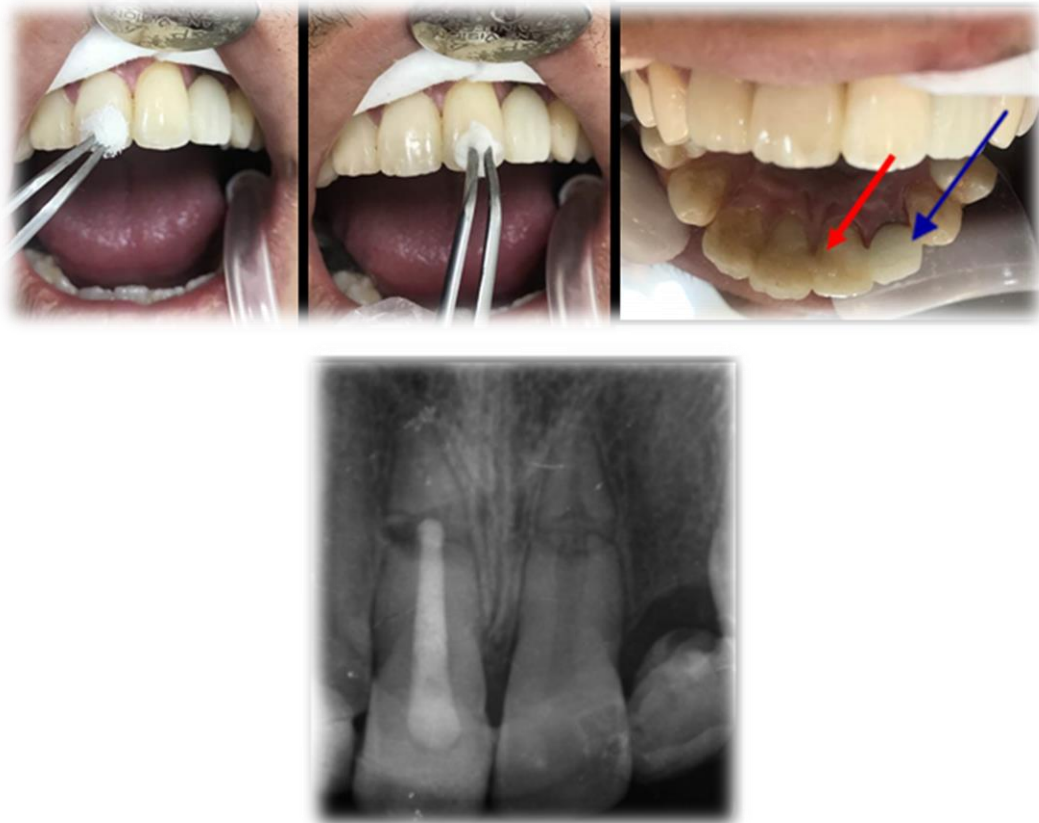**Figure 7.** 2-month clinical and radiographic follow-up.

In the 3-month follow up bone and lamina dura were formed around tooth #8 (Figure 8).



**Figure 8.** 3 months follow-up radiography.

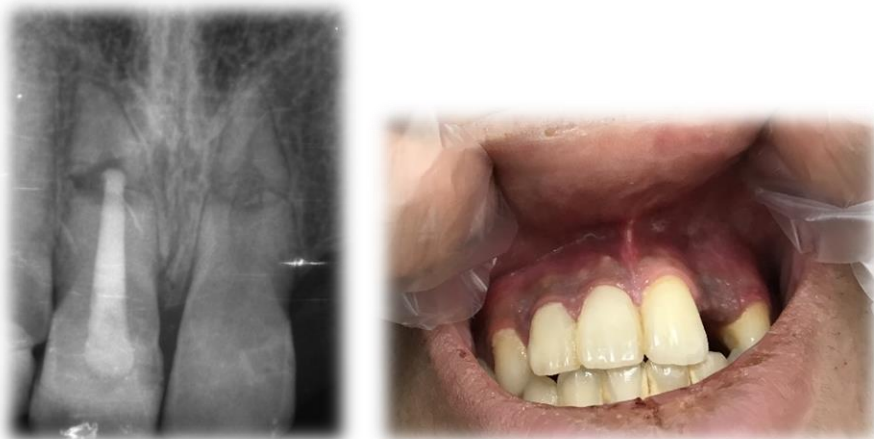
In the 6-month follow up, tooth #8 had any signs or symptoms and the vitality test of tooth #9 was normal but the patient stated that he had another accident and the tooth had a little mobility. The FRC bridge was prepared for tooth #10 (blue arrow), and it adhered to tooth #9, at the other side, tooth #9 splinted to tooth #8 with composite (Figure 9).



**Figure 9.** 6 months clinical and radiographic follow-up.

After a 1-year clinical and radiographic follow-up, tooth #8 was asymptomatic, radiolucency was reduced, more bone was formed, and periapical mucosal tissues were normal. Percussion and palpation tests of tooth #8 and tooth#9 were normal,

and tooth#9 had no mobility, but the FRC Bridge of tooth #10 was detached. (Figure 10). Cold tests and heat test was done for maxillary anterior teeth. All of them were normal except tooth #8, which was endodontically treated.



**Figure 10.** 1 year clinical and radiographic follow-up.

### Discussion

The maxillary central incisors are in an exposed position in the dental arch and are more prone to be

affected by traumatic injuries in both the primary and permanent dentitions (14).

According to the International Association of Dental Traumatology guidelines, a correct care plan should

be performed through clinical and radiographic examinations, followed by a vitality test and patient care instructions. If the fracture line is in communication with the oral cavity, the immobilization is difficult, and microbial contamination of the pulp with subsequent pulpal necrosis is almost inevitable (15).

Orhan et al (16) reported that the time elapsed between trauma and treatment, stage of root development, signs and symptoms of mobility and pain may influence the type of healing. The prognosis is directly related to coronal fragment displacement, stage of root and pulp development, type of splinting and fracture localization.

Successful management of root fractures often involves a multidisciplinary combination of endodontic, orthodontic, periodontic, and prosthetic therapy. Many investigators have suggested that the reversal of vitality of root-fractured teeth varies between a few months and 2 years (14). In a recent study, Andreasen investigated the healing of 400 root fractures, and the results showed that the type of splints appeared to have no association with the healing outcome and also stated that the location of the root fracture does not affect pulp survival (7).

The most frequent treatment method for the permanent dentition was splinting (25.3%), followed by temporary restoration of the fractured tooth with GIC. This finding contrasts with some previous findings where, in cases of delayed referral to a clinic, root canal treatment was the most common treatment method. In the study of Antipovienė et al (1), the most common (48.3%) treatment method among patients with traumatic dental injuries (TDI) in the primary dentition was tooth extraction, possibly due to efforts to avoid complicated operative treatment and to save the permanent teeth buds in cases of serious TDIs involving the primary teeth. Other reports identified follow-up as the most frequent procedure after TDI, where as in Antipovienė et al study(1), follow-up took place in less than half of the cases.

Root canal therapy is indicated when a vitality test reveals non-vital pulp tissue, or if the patient complains of pain or discomfort of the tooth, such as tooth #8 in this report, that was necrosed, and periradicular diagnosis for this tooth was chronic apical abscess. MTA is a highly recommended material for teeth that have necrotic pulp and an open apex. Various studies have compared the apical closure using calcium hydroxide and MTA. And it

has been observed that the success rate, as seen clinically and radiographically, is higher with MTA in terms of fracture resistance, hard tissue formation, and inflammation. Therefore, MTA was selected for this case to hopefully improve the outcome of the treatment (6, 17).

Healing of root fractures without treatment is also presented in many reports (7). As illustrated in our cases, after 1 year, tooth#9 is still vital without any complications such as pulp necrosis, radicular resorption, and pulpal canal obliteration that may occur after root fracture.

Extraction of the tooth and its replacement with an osseointegrated implant should always be considered the last treatment option after all other plans for preserving the natural tooth fail (6).

### Conclusion

This case report reinforces the importance of an intraoral clinical examination, performing vitality tests and periradicular tests, and radiographic examination whenever root fracture occurs. Besides, a regular and rigorous follow-up of the traumatized tooth is essential for successful outcomes. Clinical and radiographic monitoring is fundamental to help dental professionals decide the best treatment and to minimize potential complications.

### References

1. Antipovienė A, Narbutaitė J, Virtanen JI. Traumatic Dental Injuries, Treatment, and Complications in Children and Adolescents: A Register-Based Study. *Eur J Dent.* 2021;15(3):557-562.
2. Glendor U. Aetiology and risk factors related to traumatic dental injuries--a review of the literature. *Dent Traumatol.* 2009;25(1):19-31.
3. Andersson L. Epidemiology of traumatic dental injuries. *Pediatr Dent.* 2013;35(2):102-105.
4. Petti S, Glendor U, Andersson L. World traumatic dental injury prevalence and incidence, a meta-analysis-One billion living people have had traumatic dental injuries. *Dent Traumatol.* 2018;34(2):71-86.
5. Cantore S, Ballini A, Crincoli V, Grassi FR. Treatment of horizontal root fracture: a case report. *Cases J.* 2009;2:8101.
6. Taori P, Nikhade P, Chandak M, Ikhar A, Mahapatra J. Management of Untreated Horizontal Root Fracture: A Case Report. *Cureus.* 2022;14(8):e28133.
7. Andreasen JO, Andreasen FM, Mejäre I, Cvek M. Healing of 400 intra-alveolar root fractures. 1. Effect of pre-injury and injury factors such as sex, age, stage of root development, fracture type, location of fracture and severity of dislocation. *Dent Traumatol.* 2004;20(4):192-202.

8. Hartmann RC, Rossetti BR, Siqueira Pinheiro L, Poli de Figueiredo JA, Rossi-Fedele G, S Gomes M, et al. Dentists' knowledge of dental trauma based on the International Association of Dental Traumatology guidelines: A survey in South Brazil. *Dent Traumatol.* 2019;35(1):27-32.
9. Yeng T, O'Sullivan AJ, Shulruf B. Medical doctors' knowledge of dental trauma management: A review. *Dent Traumatol.* 2020;36(2):100-107.
10. Andreasen JO, Andreasen FM, Andersson L. Textbook and color atlas of traumatic injuries to the teeth. 5<sup>th</sup> ed. Hoboken: Wiley-Blackwell, 2019
11. Berman LH, Hargreaves KM. Cohen's pathways of the pulp. 12<sup>th</sup> ed. St. Louis: Elsevier. 2021
12. Yazdanpanahi N, Behzadi A, Zare Jahromi M. Long-term pH Alterations in the Periradicular Area Following the Application of Calcium Hydroxide and MTA. *J Dent (Shiraz).* 2021;22(2):90-95.
13. Molammaei E, Zare Jahromi M, Bagheri F. Effect of Calcium Hydroxide and Triple Antibiotic Paste on the Bond Strength Sealer to Dentin. *J Isfahan Dent Sch* 2024; 20(1): 52-60.
14. Altun C, Cehreli ZC, Güven G, Acikel C. Traumatic intrusion of primary teeth and its effects on the permanent successors: a clinical follow-up study. *Oral Surg Oral Med Oral Pathol Oral Radiol Endod.* 2009;107(4):493-498.
15. Diangelis AJ, Andreasen JO, Ebeleseder KA, Kenny DJ, Trope M, Sigurdsson A, et al. International Association of Dental Traumatology guidelines for the management of traumatic dental injuries: 1. Fractures and luxations of permanent teeth. *Dent Traumatol.* 2012;28(1):2-12.
16. Orhan K, Aksoy U, Kalender A. Cone-beam computed tomographic evaluation of spontaneously healed root fracture. *J Endod.* 2010;36(9):1584-1587.
17. Nasri Z, Jahromi MZ, Aminzadeh A. Clinical and histological response of human pulp tissue to direct pulp capping with mineral trioxide aggregate, Biodentine and propolis. *Dent Res J (Isfahan).* 2022;19:40.