



Evaluation of Different Variations of Facial Artery Based on Computerized Tomography Angiographic Findings

Zeinab Barzegarpour¹, Mohammad Javad Saeedi-Borujeni^{2*}, Mehdi Abrishami³

Received: 2024-08-13/ Accepted: 2025-01-04 / First publication date: 2025-05-20

© The Author(s) 2025

Abstract

Background: Understanding the anatomical pathway and variations of the facial artery helps maxillofacial surgeons and otolaryngologists reduce surgical complications. This study aimed to investigate anatomical variations in the facial artery pathway and to determine sex differences.

Materials and Methods: This descriptive-analytical study was conducted in 2021 at Ali Ibn Abi Taleb Hospital, Rafsanjan, on 150 patients who underwent CT angiography. The arterial path was evaluated and classified into four types: (1) termination in the upper lip, (2) nasolabial fold, (3) nasal ala or corner of the eye, and (4) two terminal branches. Percentage frequency was used to determine the dominant pattern, and the chi-square test was applied to assess sex differences ($\alpha = 0.05$).

Results: The mean age of participants was 58.69 ± 9.15 years; 21.3% were women and 78.7% men. On the right side, the most common arterial pattern was type III (40.7%), and the least common was type IV (7.3%). On the left side, the most frequent pattern was also type III (40%), and the least was type IV (7.3%). No statistically significant differences were found between males and females ($P = 0.45$ and $P = 0.35$, respectively).

Conclusion: The predominant termination pattern of the facial artery was at the nasal ala or corner of the eye (angular artery). Awareness of these variations is important in surgical procedures, especially when angiographic evaluation is not feasible, to prevent iatrogenic vascular injury.

Keywords: External Carotid Artery; Anatomic Variation; Angiography

Introduction

Anatomical variations refer to atypical anatomical structures that, in most cases, do not cause significant functional dysfunction in individuals (1). Studying these variations and being prepared to encounter them

during surgeries play a crucial role in reducing unintended surgical complications. Although no precise studies have been conducted to determine the prevalence of variations based on tissue type, considering the chronology of embryological development, vascular variations—particularly venous ones appear to have a higher prevalence compared to other variations such as neural, muscular, or skeletal variations (2, 3). The facial artery branches off from the external carotid artery slightly above the lingual separation (above the greater horn of the

Corresponding author: Mohammad Javad Saeedi-Borujeni

Department of Medical Basic Sciences, Faculty of Dentistry, Isf.c, Islamic Azad University, Isfahan, Iran
Email: j.saeedi@iau.ac.ir

¹ Faculty of Dentistry, Isf.c, Islamic Azad University, Isfahan, Iran

² Department of Medical Basic Sciences, Faculty of Dentistry, Isf.c, Islamic Azad University, Isfahan, Iran

³ Department of Oral & Maxillofacial Radiology, Faculty of Dentistry, Isf.c, Islamic Azad University, Isfahan, Iran

hyoid). This artery passes deep into the posterior belly of the digastric and stylohyoid muscles and enters the digastric triangle. It then ascends from the posterior side of the submandibular gland and enters the face by crossing the inferior side of the mandible. In the face, it ascends in front of the masseter and buccinator muscles and ends at the medial angle of the eye as the angular artery. The branches of the facial artery are divided into two groups: the cervical branches and the facial branches. The cervical branches of the facial artery include: ascending palatine, glandular, tonsillar, and submental, and the facial branches include the upper labial, lower labial, alar, and septal (4- 6).

Given the various documented anatomical routes and branches of the facial artery, along with the necessity for performing emergency surgeries in facial trauma cases, understanding the anatomical course and variations of the facial artery can significantly assist maxillofacial surgeons and otolaryngologists in reducing unintended surgical complications (7, 8). The Present study aimed to investigate the anatomical variations of the facial artery in the face, based on their termination point.

Materials and Methods

This descriptive-analytical study aimed to determine the predominant pattern of the facial artery based on angiographic findings. The department approved our study of Basic Medical Sciences, School of Dentistry, Islamic Azad University of Isfahan (Khorasgan) (KHUISF), Isfahan, Iran. Also, our study was approved by the ethics committee of the KHUISF (IR.IAU.KHUISF.REC.1400.230). Our investigation was conducted on patients referred to Ali Ibn Abi Talib Hospital of Rafsanjan (Rafsanjan, Iran) during the spring and summer of 2021. These patients underwent computerized tomography (CT) angiography for various reasons. Inclusion criteria involved patients aged 20 to 70 years who had

indications for CT angiography. Exclusion criteria included a history of facial trauma or surgeries, previous malignancies in the facial or neck region (as malignant masses can alter vascular patterns via angiogenesis), and patients with incidentally diagnosed abnormal angiogenesis. CT angiography images were retrieved from the hospital's radiology archive, and 150 cases were randomly selected based on the inclusion and exclusion criteria. The facial artery pathway was interpreted for both sides of the face. Demographic data, including age, sex, and the reason for CT angiography, were also recorded.

Based on the study performed by Furukawa et al. (9), facial artery patterns were classified into four patterns based on their termination point in the face. The first type of facial artery terminated in the upper lip, the second type terminated in the nasolabial fold, the third type terminated in the nasal ala or the corner of the eye, and the fourth type terminated in two branches in the corner of the eye (Figure 1). The analysis was performed bilaterally, and CT angiography examinations were repeated twice for each patient to ensure accuracy. The pattern type for each individual (both right and left sides of the face) was recorded on separate forms.

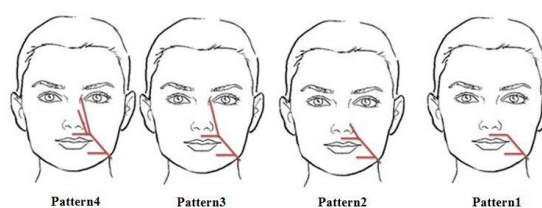


Figure 1. Schematic image for determining the four pathways of the facial artery

In this study, the collected data were analyzed using SPSS software version 24 (SPSS Inc., Chicago, IL, USA). Percentage frequency was used to determine the dominant arterial pattern. The chi-square statistical test was used to determine sex differences in arterial

path, and $P < 0.05$ was considered a statistically significant difference.

Results

This study examined the facial artery pathway in 150 patients based on CT angiographic findings, analyzing a total of 300 arteries (150 on each side). The arterial patterns were evaluated and categorized, and their frequency was assessed across sex. The minimum age of the patients was 38 years, and the maximum age was 77 years. The mean age of the patients was 58.69 ± 9.15 years. Among the participants in the present study, 21.3% were women (32 out of 150) and 78.7% were men (118 out of 150). The mean age of the women participating in the study was 56.13 ± 9.23 years, and the mean age of the men was 59.39 ± 9.04 years. Based on the reviewed patient records, neurological problems were the most common reason for performing CT angiography, with 64 patients (42.7%) 47 patients (31.3%) had CT angiography indicated for being candidates for facial surgeries, 26 patients (17.3%) due to carotid body tumors, and bleeding of unknown cause was the reason for performing CT angiography of the head and neck vessels in 13 of them (8.7%).

In 23.3% of patients, the right facial artery ended in the upper lip, in 28.7% of them in the nasolabial fold, in 40.7% it ended in the lateral nasal ala or as the angular artery in the medial corner of the eye, and in the fourth pattern, where the facial artery ended in two branches on the medial side of the eye, this rate was 7.3%. As can be seen, on the right side of the face, the most common arterial pattern was the third pattern, which ended in the lateral nasal ala or the corner of the eye, and the least common was the fourth pattern, which ended in two branches on the medial canthus.

In 23.3% of patients, the left facial artery terminated in the upper lip, in 29.3% in the nasolabial fold, in 40% the facial artery terminated in the nasal ala or the

medial corner of the eye, and in 7.3% of patients the facial artery ended in two branches on the medial side of the eye. Based on the information presented above, the most common arterial route in the left half of the face was the third route, and the least frequent was the fourth route.

Table 1 shows the frequency of each pattern of the right facial artery in both males and females. Based on the chi-square test, there was no statistically significant difference in the pattern of the right facial artery between males and females ($P=0.45$).

Table 1. The frequency of each pattern of the right facial artery in both males and females

Gender	Pattern 1	Pattern 2	Pattern 3	Pattern 4	P value
Males	25.4%	28.8%	39.8%	5.9%	0.45
Females	15.6%	28.1%	43.8%	12.5%	

Table 2 shows the frequency of each pattern of the left facial artery in both sexes. Based on the chi-square test, there was no statistically significant difference in the pattern of the left facial artery between males and females ($P=0.35$).

Table 2. The frequency of each pattern of the left facial artery in both males and females

Gender	Pattern 1	Pattern 2	Pattern 3	Pattern 4	P value
Males	25.4%	30.5%	38.1%	5.9%	0.35
Females	15.6%	25%	46.9%	12.5%	

Discussion

Many studies have been conducted on fascial artery variations, most of which have been conducted on cadavers (10, 11). These studies are less reliable due to small sample sizes and have the difficulties of static, non-living, surface anatomy. Some other studies have also been based on injecting dye into the facial artery and then performing CT (12, 13). In addition to the value and, of course, the high cost of these studies, this method cannot reflect the physiological state of blood supply and arterial pattern, because blood vessels thicken when filled with dye. CT angiography is a

minimally invasive, highly accurate method for determining the arterial pattern in a patient and is also capable of noting anatomical structures and landmarks. In the present study, we investigated various variations in the course of the facial artery after it passes through the pre-angulated notch and enters the face. For this purpose, four routes that were mentioned as common routes of this artery in the face (based on previous articles) were examined. In our study population, the predominant pattern for the facial artery was to terminate in the nasal ala or corner of the eye (angular artery). Furukawa et al. (9) in Japan investigated the course of the facial artery in the face based on angiographic findings. The results of their study showed that the facial artery typically ended in the nasolabial fold in most cases, which was inconsistent with the findings of our study.

In our study, the pattern of the facial artery on both the right and left sides did not differ statistically between the two sexes. These results were consistent with those of a study by Koh et al. (14). In their study, the researchers investigated possible asymmetry in the course of the facial artery between the two sexes. For this, they dissected 47 Korean cadavers. They reported that sex did not play a crucial role in variations in the course of the facial artery. They reached this finding through autopsy, which naturally has a higher accuracy than angiographic studies; however, the number of samples in our study was significantly larger than that in Koh et al. (14).

In another study, Wang et al. (15) investigated variations in the facial artery among Asians at Tongji Hospital, Wuhan, China, using CT angiography. They also used the four paths used in the present study to determine the dominant pattern. They also examined the relationship between the nasolabial fold and the facial artery. In their study, the second path (the artery ending in the lateral nasal) was the most common, and the fourth path (the artery bifurcating and ending in the

medial canthus) was the least common. In our study, the third pattern, where the artery ends in the nasal ala or the corner of the eye, was more common, which was not consistent with Wang's results. One of the differences between the present study and Wang's study was the comparison of the artery paths on the right and left sides, which was done in our study.

In another study, Hong and colleagues (16) examined fascial artery variations based on conventional angiography. Based on the results of their study, which was conducted on 284 patients, type 1 (angular branch) made up 36.6%, type 2 (lateral nasal branch) made up 48.6%, type 3 (superior labial branch) made up 8.5%, and type 4 (inferior labial branch) made up 6.3%. Additionally, Koziej et al. (17) created an anatomical map of the facial artery for use in cosmetic surgery. They used CT angiography of the head and neck on 131 patients to determine the above map. Their results showed that the most common facial artery pathway was the classic path situated medially to the nasolabial fold, which is consistent with our results. Additionally, Lee et al. (18) investigated the relationship between facial arterial depth and the facial musculature layer. Their study was conducted on 54 Korean cadavers, and three arterial patterns were examined. Based on their results, the arterial distribution frequencies were as follows: pattern 1, the nasolabial pattern (51.8%); pattern 2, the nasolabial pattern with an infraorbital trunk (29.6%); and pattern 3, the forehead pattern (18.6%).

The results of the present study play a significant role in preventing unwanted surgical complications. Because in many facial surgeries that occur following sudden trauma, there is no opportunity to perform CT angiography. Naturally, if the surgeon is aware of the possibility of these arterial variations in the face, they can prevent unwanted vascular damage. Additionally, in many cases of abnormal bleeding that occur following facial surgeries, where the bleeding site is

unclear, it is essential to be aware of these variations (19, 20). There were two significant limitations in our study. One limitation was the small sample size, as this type of study typically has higher validity when the sample size is larger. The other limitation was its single-center design. One of the strengths of the present study was its exclusion criteria, especially in the case of facial malignancies, which can cause difficulties for the researcher in identifying the arterial path due to abnormal angiogenesis.

Conclusion

In our study population, the predominant pattern for the facial artery was to terminate in the nasal ala or corner of the eye (angular artery). Since in many emergency surgeries, there is no opportunity to perform facial vascular angiography, attention to the possibility of other variations in the course of the artery prevents many unwanted surgical injuries. It is recommended to conduct a study with a larger sample size and a multicenter study.

Conflict of Interests: The authors of this manuscript declare that they have no conflicts of interest, real or perceived, financial, or non-financial in this article

References

- Zefreh A, Torkzadeh A, Zare Jahromi M, Ardalani R. Prevalence of Palatal Radicular Groove in upper Lateral Incisors: A CBCT study at Isfahan Azad dental school. *cofs* 2025; 3 (3) :15-21
- García-Barrios A, Cisneros-Gimeno AI, Celma-Pitarch A, Whyte-Orozco J. Anatomical study about the variations in renal vasculature. *Folia Morphol (Warsz)*. 2024; 83(2):348-353.
- Valenzuela-Fuenzalida JJ, Comejo-Peña J, Martínez-Cid J, Rojas-Acuña C, Granite G, Sanchis-Gimeno JA, et al. Anatomical Variants of the Renal Veins and Their Relationship with Morphofunctional Alterations of the Kidney: A Systematic Review and Meta-Analysis of Prevalence. *J Clin Med*. 2024; 13(13):3689.
- Metilda G, A C LR, Natarajan PS, N V, Rajan J. Analyzing the Anatomical Characteristics of the Facial Artery Branches: A Human Cadaveric Study. *Cureus*. 2024; 16(10):e71149.
- Nguyen VH, Cheng-Kuan L, Nguyen TA, Cai THNT. The branching patterns and termination points of the facial artery: a cadaveric anatomical study. *Arch Craniofac Surg*. 2024; 25(2):77-84.
- Elvan Ö, Uzmannel D. Mapping the localization of the facial artery and vein at the inferior border of the mandible for clinical applications. *Anat Sci Int*. 2025; 100(3):280-286.
- Yoon CY, Engler AM, Konisky H, et al. Unilateral double facial artery: an anatomic variant and clinical implications. *Case Reports Plast Surg Hand Surg*. 2024; 11(1):2376136.
- Qin Q, Chu T, Zhao Y, Fu Y, Yang H, Liu Q. Facial artery-based flap for oral and maxillofacial defects: a narrative review. *Clin Oral Investig*. 2025; 29(8):382.
- Furukawa M, Mathes DW, Anzai Y. Evaluation of the facial artery on computed tomographic angiography using 64-slice multidetector computed tomography: implications for facial reconstruction in plastic surgery. *Plast Reconstr Surg*. 2013; 131(3):526-535.
- Nguyen VH, Cheng-Kuan L, Nguyen TA, Cai THNT. The branching patterns and termination points of the facial artery: a cadaveric anatomical study. *Arch Craniofac Surg*. 2024; 25(2):77-84.
- Yi KH, Wan J, Bautzer C, Ascher B, Gold M. Optimizing Cannula Selection: A Cadaveric Study of Arterial Diameters in Facial Artery Branches and Periorbital Arteries. *Aesthet Surg J*. 2025; 45(8):836-841.
- Piisl U, Anderhuber F, Neugebauer S. The Facial Artery-The Main Blood Vessel for the Anterior Face?. *Dermatol Surg*. 2016; 42(2):203-208.
- Zhu GZ, Zhao WR, Luo CE, Cai B, Kong XX, Zhan WF, et al. High-Throughput Screening of Full-Face Clinically Relevant Arterial Variations Using Three-Dimensional Postmortem Computed Tomography. *Plast Reconstr Surg*. 2018; 142(5):653e-664e.
- Koh KS, Kim HJ, Oh CS, Chung IH. Branching patterns and symmetry of the course of the facial artery in Koreans. *Int J Oral Maxillofac Surg*. 2003; 32(4):414-418.
- Wang D, Xiong S, Zeng N, Wu Y. Facial Arterial Variations in Asians: A Study on Computed Tomographic Angiography. *Aesthet Surg J*. 2022; 42(5):527-534.
- Hong SJ, Park SE, Jo JW, Jeong DS, Choi DS, Won JH, et al. ariant facial artery anatomy revisited: Conventional angiography performed in 284 cases. *Medicine (Baltimore)*. 2020; 99(28):e21048.

17. Koziej M, Trybus M, Hołda M, Polak J, Wnuk J, Brzegowy P, et al. Anatomical Map of the Facial Artery for Facial Reconstruction and Aesthetic Procedures. *Aesthet Surg J*. 2019; 39(11):1151-1162.
18. Lee JG, Yang HM, Choi YJ, Favero V, Kim YS, Hu KS, et al. Facial arterial depth and relationship with the facial musculature layer. *Plast Reconstr Surg*. 2015; 135(2): 437-444.
19. Akolkar AR, Kulkarni DG, Gangwani KD, Shetty L, Channe SP, Sarve PH. Bleeding control measures during oral and maxillofacial surgical procedures: A systematic review. *J Dent Res Rev* 2017; 4: 79-89.
20. Guthrie A, Kadakia S, Cranford J, Sawhney R, Ducic Y. A Review of Complications and Their Treatments in Facial Aesthetic Surgery. *The American Journal of Cosmetic Surgery*. 2017; 34(2):73-80