Contemporary Orofacial Sciences (2026) 4(3): 35-40
DOI: 10.66224/cofs.4.3.5

CASE REPORT

Giant 'Leaf-like' Traumatic Fibroma of the Hard Palate: A Case Report

Marzie Qasemzade[1], Parham Farzam[2], Ghazal Hosseinzade Salavati[3], Amirhossein Yavari[4*]

Received: 2025-12-13/ Accepted: 2026-07-06 / First publication date: 2026-09-16

© The Author(s) 2026

Abstract

Background: Traumatic fibroma (TF) is a common benign oral mucosal lesion caused by chronic low-grade irritation. Leaf-like Traumatic Fibroma (LTF) usually presents as a flattened, pedunculated mass beneath maxillary dentures. Giant LTFs, larger than 2–3 cm, are extremely rare. In this case report we present a case of a large leaf-like fibroma.

Case report: This report describes a 68-year-old man with a large, asymptomatic, pedunculated mass on the hard palate. Clinical examination revealed a 3 × 2 × 1.5 cm soft, leaf-like lesion beneath an ill-fitting maxillary denture and severe denture stomatitis (Newton Type III). Under local anaesthesia an excisional biopsy was performed using an 810 nm diode laser. Histopathological examination confirmed fibroepithelial hyperplasia with chronic inflammation. The associated denture stomatitis was treated with the Vizir 3 antifungal protocol, and nystatin oral suspension (100,000 IU/mL) was prescribed postoperatively. Mucosal healing was complete without recurrence at the 3-month follow-up period.

Conclusion: This case shows that common reactive lesions may present as large masses. Successful long-term management requires not only complete surgical removal but also elimination of underlying causes, including prosthetic trauma and secondary fungal infection, to prevent recurrence and ensure recovery.

Keywords: Fibroma; Stomatitis Denture; Laser Therapy

Introduction

Traumatic fibroma (TF), also known as an irritational fibroma, is a benign exophytic oral lesion caused by chronic mucosal irritation (1). TF is the most common benign tumor of the oral cavity, with a worldwide prevalence of 1–2%. Leaf-like Traumatic Fibroma (LTF) is a less common reactive fibrous lesion usually associated with chronic irritation from an ill-fitting maxillary denture. (2,3). Clinically, it usually appears as a firm, sessile or pedunculated mass with a smooth or papillary surface, often causing discomfort during chewing and speaking.

Corresponding author: Amirhossein Yavari

Department of Oral Medicine, Faculty of Dentistry, Isf.C., Islamic Azad University, Isfahan, Iran
Email: a.yavari7508@iau.ir

1. Faculty of Dentistry, Isf.C., Islamic Azad University, Isfahan, Iran
2. Department of Oral and Maxillofacial Medicine, Faculty of Dentistry, Isf.C., Islamic Azad University, Isfahan, Iran
3. Faculty of Dentistry, Isf.C., Islamic Azad University, Isfahan, Iran
4. Department of Oral Medicine, Faculty of Dentistry, Isf.C., Islamic Azad University, Isfahan, Iran

It is often called a fibroepithelial polyp or leaflike denture fibroma, commonly found on the hard palate beneath a maxillary denture. This characteristic lesion presents as a flattened pink mass that is attached to the palate by a narrow stalk. The mass typically adheres closely to the palate within a shallow, cupped depression; however, it can be readily elevated with a probe, confirming its pedunculated nature. The lesion margin is often serrated, producing a characteristic leaf-like appearance (4). Clinically, it is a slow-growing lesion that may involve the adjacent epithelium (5).

The lesion is usually pedunculated, with an average size of 7–8 mm in diameter but may be larger than 1–2 cm. Leaf-like fibroma is typically associated with chronic denture-related irritation and is most often seen on mucosa in contact with the denture base, particularly the hard palate(6) .According to Neville,

[Downloaded from cofs.khuisf.ac.ir on 2026-11-28]

[DOI: 10.66224/cofs.4.3.5]

similar leaf-like lesions predominantly affect middle-aged and older adults, with a significant female predilection - studies demonstrate 67-75% of biopsied cases occur in women. Specifically, these lesions often show associated inflammatory papillary hyperplasia in the midline of the palate (4).

The best treatment for fibromas is surgical removal of the lesion, and rare cases of recurrence have been reported so far. Feasible Treatments include cryosurgery, which uses liquid nitrogen, and the strangulation technique. Cryosurgery is suitable for patients who are allergic to anesthetics or are at high surgical risk. Other methods include electric and regular scalpels. Some authors suggest applying penicillin G to the lesion, claiming it has sclerosing effects that help detach the lesion and prevent recurrence (7-9).

In the present case report, we described a large LTF managed with diode laser surgery without recurrence after 3 months of treatment. To the best of our knowledge, this case may represent the first reported use of laser surgery for this lesion. Its rarity and distinctive etiology underscore the clinical relevance of this case and the importance of addressing underlying causes during management. This case report was prepared in accordance with the CARE (Case Report) guidelines.

Case Presentation

A 68-year-old man was referred to the oral medicine clinic by his general dentist for evaluation of a painless palatal mass that had been slowly enlarging over the past year (Figure 1) The patient's chief complaint was "a growing lump on the roof of my mouth that interferes with my denture". He reported wearing a maxillary complete denture for more than 10 years, which had become progressively ill-fitting. He denied any history of tobacco, alcohol, or previous oral lesions. His medical history was unremarkable except for well-controlled hypertension.

On extraoral examination, no lymphadenopathy or facial asymmetry was noted. Intraoral examination revealed a large, exophytic, pedunculated lesion measuring 3 × 2 × 1.5 cm on the right side of the hard palate. The lesion had similar color to surrounding mucosa, with a lobulated, leaf-like surface and a narrow stalk. It could be easily elevated with a probe, confirming its pedunculated nature . The surrounding palatal mucosa showed diffuse erythema and papillary hyperplasia consistent with Newton Type III denture stomatitis. The lesion was soft, non-tender, and non-ulcerated.



Figure 1. Clinical and Gross aspect,s of the lesion showing mucosal pedunculated leaf-like lesion measuring 3 cm in diameter .

[Downloaded from cofs.khuisf.ac.ir on 2026-11-28]

[DOI: 10.66224/cofs.4.3.5]

Based on the clinical manifestation and history of chronic denture irritation the provisional diagnosis of leaf-like fibroma was made.

Complete surgical excision of the lesion was performed under local anesthesia. The method of complete removal was by using diode laser 810 nm (Dr.Smile c /Italy) used as primary cutting tool and for tissue hemostasis , coagulation and primary closure of the surgical site(Figures2 and 3).The associated denture stomatitis was treated with the Vizir 3 antifungal protocol, and nystatin oral suspension (100,000 IU/mL) was prescribed postoperatively.The excised specimen was submitted entirely for histopathological examination to confirm the diagnosis. Microscopic evaluation of the lesion revealed a fibroepithelial polyp composed of a narrow, pedunculated core of dense, collagenous fibrous connective tissue covered by stratified squamous epithelium.The overlying epithelium showed hyperparakeratosis and rete ridge hyperplasia. No epithelial dysplasia or malignancy was identified. The underlying connective tissue showed a chronic inflammatory infiltrate composed predominantly of lymphocytes and plasma cells, consistent with reactive changes secondary to chronic denture irritation. These histopathologic features confirmed the diagnosis of leaf-like traumatic fibroma (denture-induced fibroepithelial hyperplasia) (Figure 4). Postoperative instructions were maintaining good oral hygiene and follow-up visits. After complete mucosal healing, we fabricated a new maxillary denture to ensure proper fit and prevent recurrence.

At the 3-month follow-up, there was no evidence of recurrence, and the palatal mucosa had healed completely.



Figure 2. Laser removal of the lesion



Figure 3. Post surgery

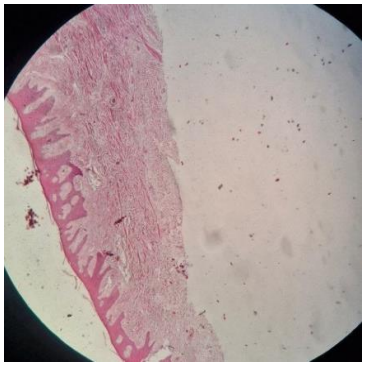

Figure 4. The microscopic image shows the fibrotic stroma of the lesion .(H&E ,4X ,light microscopy)

[Downloaded from cofs.khuisf.ac.ir on 2026-11-28]

[DOI: 10.66224/cofs.4.3.5]

Discussion

This case of a large, leaf-like fibroepithelial hyperplasia highlights several important clinical considerations in the diagnosis and management of unusual oral lesions. A variable chronic inflammatory infiltrate is present; sometimes, it may include eosinophils or show lymphoid follicles. If minor salivary glands are included in the specimen, then they usually show chronic sialadenitis. In rare instances, the formation of osteoid or chondroid is observed,known as osseous and chondromatous metaplasia, a reactive phenomenon caused by chronic irritation by the ill-fitting denture. The irregular nature of this bone or cartilage can be microscopically disturbing, and the pathologist should not mistake it for a sarcoma.

The clinical presentation of a large, pedunculated, leaf-like palatal mass in an elderly patient with an ill-fitting maxillary denture and severe denture stomatitis (Newton Type III) usually manifests the diagnosis of leaf like fibroma but the histopathologic evaluation is necessary to confirm the diagnosis.

The mass exhibited a stalk-like, floppy consistency and smooth surface, which is characteristic of leaf-like traumatic fibroma (LTF) (also known as leaf fibroma or denture-induced fibroepithelial hyperplasia). This lesion, a subtype of focal fibrous hyperplasia representing reactive hyperplasia of fibrous connective tissue in response to chronic mechanical irritation, constitutes the primary diagnostic consideration. Inflammatory papillary hyperplasia (IPH) of the palate was strongly suspected due to the surrounding pebbly erythematous mucosa seen in this case. IPH appears as multiple, small, red papillary projections across a broad area of the palate and is a reactive change to chronic denture irritation, often exacerbated by *Candida albicans* infection. However, the large, solitary, pedunculated, leaf-like mass itself is a distinct clinical entity rather than a manifestation of IPH, which is generally multifocal.

The use of 810 nm diode laser (Dr.Smile c /Italy) for biopsy offered distinct advantages in this palatal lesion, though the potential for thermal artifact required careful histopathological interpretation. The lesion's considerable size (3×2×1.5 cm) necessitated a comprehensive approach combining complete surgical excision with 2 mm margins and concurrent management of the underlying denture stomatitis using Vizir 3 antifungal therapy. This case underscores that even benign-appearing oral lesions may present diagnostic challenges when exhibiting unusual features like leaf-like morphology. The successful outcome demonstrates the importance of a systematic approach incorporating clinical, radiographic, and histopathological evaluation, along with appropriate technology selection and attention to underlying causative factors.

Although LTF is a well-recognized reactive lesion, the majority of published cases described lesions of smaller size (typically 7–8 mm to 2 cm in greatest dimension) occurring in denture-wearing elderly patients. The present case, measuring 3 × 2 × 1.5 cm, therefore falls into the category of a giant LTF, a rare presentation that merits documentation.

Kar et al. (2015) reported a large irritation fibroma of the palate measuring 3.5 cm in length in a 65-year-old female with a history of betel leaf and nut ingestion. Histopathological examination revealed bundles of spindle cells producing extensive collagen with focal pseudoepitheliomatous hyperplasia in the mucosal epithelium and a chronic inflammatory infiltrate in the submucosa. While that case rivals the present lesion in size, it was not characterized as a leaf-like fibroma but rather as a pedunculated irritation fibroma, and it lacked the distinctive leaf-like flattening against the palatal surface. Furthermore, the etiological factors differed substantially, as the Kar et al. case was associated with chronic areca nut use rather than denture-related trauma, and no concurrent denture

[Downloaded from cofs.khuisf.ac.ir on 2026-11-28]

[DOI: 10.66224/cofs.4.3.5]

stomatitis was documented. The present case, by contrast, involved both an ill-fitting maxillary complete denture and severe Newton Type III denture stomatitis, representing a more complex etiological and clinical scenario (10).

Nascimento et al. (2020) described an unusual case of LTF in a dentate patient who did not use any type of prosthesis; instead, the lesion was related to an injury caused by food trauma, which is an unusual etiology for this type of lesion. The lesion measured 2 cm in diameter and was located on the hard palate, with the authors reporting the mechanical pressure of the tongue and the action of negative intraoral pressure as possible modifying agents in causing the characteristic leaf-like shape. While this case shares the leaf-like morphology and palatal location with the present report, key differences exist. The present case measured 3 × 2 × 1.5 cm considerably larger than that reported by Nascimento et al. and was associated with both an ill-fitting maxillary complete denture and severe Newton Type III denture stomatitis, which is not uncommon, underscoring the classic denture-induced etiology. Additionally, the present case involved a 68-year-old male patient, whereas the Nascimento et al. case involved a 38-year-old female without denture use, highlighting the wider age range and more typical demographic pattern of denture-related LTF in the current report (11).

Acevedo Ortiz et al. (2022) reported a case of giant fibrous hyperplasia of the palate in a 40-year-old male patient who presented with two symmetrical tumours on the hard palate. On examination, two bilateral tumours were observed on the hard palate, symmetrical, soft, mobile, non-ulcerated and with pediculation on the inner side of both upper gums. The dimensions of the tumours were 4 × 2 × 1 cm each slightly larger than the present case and complete excision was performed under general anaesthesia. The anatomopathological study reported a lesion covered by hyperplastic squamous epithelium without atypia, with increased collagen with areas of hyalinisation in the lamina propria, compatible with exuberant fibrous hyperplasia. Although similar in size and location to the present case, the Acevedo Ortiz et al. case involved bilateral, symmetrical tumours rather than a single giant LTF, and the patient was younger (40 years vs. 68 years). Additionally, no denture stomatitis was documented in that case, and the surgical approach differed from the combined scalpel and diode laser technique used in the present report. The authors noted that malignant degeneration may occur in up to 6% of cases, underscoring the importance of complete excision a principle that guided the management in the present case (11).

Conclusion

This case of a giant leaf-like fibroma highlights an important clinical principle. Common reactive oral lesions can show unusual and dramatic features that resemble neoplasia. For this reason, a thorough approach is essential. It must include a complete clinical history, careful examination, and a detailed histopathological analysis for a precise diagnosis. Additionally, this report stresses that effective long-term management goes beyond just surgical removal. It requires identifying and carefully removing all underlying causes, especially chronic prosthetic irritation and secondary candidal infections, to prevent recurrence and ensure full patient recovery.

Conflict of Interests: The authors of this manuscript declare that they have no conflicts of interest, real or perceived, financial or non-financial, in this article

References

1. Rivera C, Droguett D, Arenas-Márquez MJ. Oral mucosal lesions in a Chilean elderly population: A retrospective study with a systematic review from

[Downloaded from cofs.khuisf.ac.ir on 2026-11-28]

[DOI: 10.66224/cofs.4.3.5]

thirteen countries. J Clin Exp Dent. 2017 Feb 1;9(2):e276-e283

2. Zhang WT, Wang YB, Ang Y, Wang HZ, Li YX. Diagnosis of an extremely rare case of malignant adenomyoepithelioma in pleomorphic adenoma: A case report. World J Clin Cases. 2022 May 16; 10(14):4648-4653. doi:10.12998/wjcc.v10.i14.4648. PMID: 35663065; PMCID: PMC9125290.
3. Szymczuk V, Taylor J, Boyce AM. Craniofacial Fibrous Dysplasia: Clinical and Therapeutic Implications. Curr Osteoporos Rep. 2023 Apr;21(2):147-153.
4. Neville BW, Damm DD, Allen CM, Chi AC. Oral and Maxillofacial Pathology. 5th ed. St. Louis, MO: Elsevier; 2024.
5. Nascimento LHA, Junior JM, Albuquerque GC. Leaf-like traumatic fibroma in a dentate patient: an unusual case. CODS J Dent. 2021; 12(2): 45-47.
6. Nascimento LHA, Pinheiro TN, Junior JM, et al. Leaf-like traumatic fibroma in a dentate patient: an unusual case. CODS J Dent. 2020;12(2):45-47.
7. Sreeja C, Vezhavendan N, Shabana E, et al. Recurrent peripheral odontogenic fibroma associated with basal cell budding. J Pharm Bioallied Sci. 2014;6(5):204-207.
8. Correa PE, Arias Mendieta S. Resection of fibroma in the oral mucosa: the strangulation technique. Rev CES Odontol. 2016; 29(1): 82-87.
9. Borras MT, Delgado-Molina E, Berini-Aytés L, et al. Excision of hyperplastic lesions of the oral cavity: a retrospective study of 128 cases. Med Oral Patol Oral Cir Bucal. 2005;10: 151-162.
10. Kar C, Sarkar P, Das S, Ghosh A. Large irritation fibroma of palate – a rare presentation. Bahrain Med Bull. 2015;25(3):233-236.
11. Acevedo Ortiz L, Invencio da Costa LF, Juárez Escalona I. Giant fibrous hyperplasia of the palate. Acta Otorrinolaringol Esp. 2022;73(6):339-416.

[Downloaded from cofs.khuisf.ac.ir on 2026-11-28]

[DOI: 10.66224/cofs.4.3.5]