Contemporary Orofacial Sciences (2026) 4(3): 28-34
DOI: 10.66224/cofs.4.3.3

CASE REORT

A dentigerous cyst associated with an impacted canine, supernumerary tooth and denticle in the left mandible: A case report

Nasim Jafari Pozveh[1], Mahmoud Abbasian[2]*

Received: 2025-09-12/ Accepted: 2026-05-06 / First publication date: 2026-09-16

© The Author(s) 2026

Abstract

Background: Dentigerous cysts (DCs) are the second most common type of odontogenic cysts, typically associated with the crowns of unerupted or impacted teeth, most commonly the mandibular third molars and maxillary mesiodens. DCs associated with an impacted mandibular canine, supernumerary tooth, and denticle are extremely rare and rarely reported in the literature

Case report: We reported a case of a 17-year-old Iranian male who presented with a retained primary canine in the left mandibular region. Radiographic examination revealed a dentigerous cyst associated with an impacted permanent mandibular canine, a supernumerary tooth, and a denticle. The lesion was asymptomatic and incidentally discovered during radiographic evaluation. The patient underwent surgical enucleation of the cyst along with extraction of the impacted canine and supernumerary tooth. Histopathological analysis confirmed the diagnosis of a dentigerous cyst.

Conclusion: The impacted canine was removed, and no postoperative complications were noted. Follow-up showed satisfactory healing without recurrence. This case highlights a rare presentation of a dentigerous cyst associated with a mandibular canine, a supernumerary tooth, and a denticle. Early detection through imaging and appropriate surgical management are crucial to prevent potential complications in such unusual cases.

Keywords: Dentigerous Cysts; Tooth, Impacted; Tooth, Supernumerary; Mandible; Cone-Beam Computed Tomography

Introduction

A dentigerous cyst (DC) is a developmental odontogenic cyst that encircles the crown of an unerupted or impacted tooth and is attached to the cementoenamel junction (1). DCs are the second most common odontogenic cyst after radicular cysts (2), accounting for about 16.6% of all jaw cysts. They are typically asymptomatic and often discovered incidentally on radiographs. However, if untreated, they can gradually enlarge and lead to significant bone destruction, tooth displacement, or even pathological fractures (1,3).

The pathogenesis of DCs is primarily developmental, although some cases, particularly those associated with a non-vital deciduous tooth, also suggest inflammatory origins (4). Histopathologically, they are lined by non-keratinized stratified squamous epithelium and may rarely contain mucous or ciliated cells (5). DCs are most frequently associated with impacted mandibular third molars and maxillary supernumerary teeth, particularly mesiodens. According to Lin et al. (5), 84.8–90% of DCs related to supernumerary teeth occur in the anterior maxilla, whereas involvement of mandibular anterior teeth is quite rare.

Corresponding author: Mahmoud Abbasian

Department of Oral and Maxillofacial Radiology, Faculty of Dentistry, Isf.C, Islamic Azad University, Isfahan, Iran
Email: nasimjafari@iau.ac.ir

1. Department of Oral and Maxillofacial Radiology, Faculty of Dentistry, Isf.C, Islamic Azad University, Isfahan, Iran
2. Department of Oral and Maxillofacial Radiology, Faculty of Dentistry, Isf.C, Islamic Azad University, Isfahan, Iran

[Downloaded from cofs.khuisf.ac.ir on 2026-11-28]

[DOI: 10.66224/cofs.4.3.3]

Supernumerary teeth are defined as extra teeth beyond the normal complement. They may occur in both primary and permanent dentition and have a reported prevalence ranging from 0.1% to 3.8% (6). Rajab and Hamdan (7) reported that 92.8% of supernumerary teeth occurred in the premaxillary region, particularly around the central incisors. DCs associated with supernumerary teeth constitute approximately 5% of all DCs (8). In rare cases, DCs may also be associated with odontomas or fused teeth (9–11).

DCs might uncommonly be seen in association with impacted canines as reported in a few studies (12,13). However, to the best of our knowledge, no previously published report has described a dentigerous cyst involving all three elements of impacted mandibular canine, impacted supernumerary tooth, and a denticle simultaneously.

A denticle, in this article, refers to a small, calcified, tooth-like structure resembling a rudimentary odontoma or malformed tooth. Its presence further complicates the clinical and radiographic presentation and may challenge preoperative diagnosis.

The objective of this case report was to describe a dentigerous cyst in an uncommon location with an uncommon presentation. We discuss the diagnostic challenges and the role of advanced imaging such as cone-beam computed tomography (CBCT) in surgical planning. By presenting this case, we aim to contribute to the limited literature on atypical presentations of DCs and assist clinicians in recognizing and managing such rare entities.

Case Report

A 17-year-old Iranian male student was referred to the oral and maxillofacial clinic for evaluation of a retained primary mandibular canine on the left side. The patient reported no relevant medical, familial, or psychosocial history and had no significant systemic conditions. His oral hygiene was fair, and he denied any history of trauma, infection, or previous dental surgery in the mandibular anterior region, smoking and bruxism.

On intraoral examination, the primary canine (tooth C) was retained, and a firm, non-tender swelling was observed in the buccal and lingual aspects of the left mandibular anterior region. The overlying mucosa appeared normal in color and texture, without signs of inflammation or ulceration. The swelling was approximately 1.5 cm in diameter, with no signs of fluctuation. Extraoral examination revealed no facial asymmetry, lymphadenopathy, or malocclusion.

The premolars adjacent to the lesion were intact, with no signs of root resorption, displacement, or periodontal involvement.

A CBCT radiograph revealed an unerupted mandibular canine associated with a well-defined unilocular radiolucent lesion, surrounding the crown, measuring approximately 11.4 × 12.5 mm. The lesion extended into both buccal and lingual cortical plates. A supernumerary tooth and a denticle were also identified near the superior border of the lesion. To better evaluate the lesion's proximity to vital anatomical structures, particularly the mental foramen, and to determine the three-dimensional extent and spatial relationships of the impacted structures, a cone beam computed tomography (CBCT) scan was performed.

The CBCT scan showed the impacted mandibular canine located vertically on the inferior portion of the anterior left mandible (Figure 1), with the radiolucent lesion enveloping its crown and extending circumferentially through the buccal and lingual plates (Figure 2). The denticle and supernumerary tooth were seen on the superior-lingual aspect of the lesion, within the same anatomical quadrant, not crossing the midline, clarifying earlier positional confusion. The lesion was noted to be in proximity to the mental

[Downloaded from cofs.khuisf.ac.ir on 2026-11-28]

[DOI: 10.66224/cofs.4.3.3]

foramen, but no direct involvement or compression was observed.

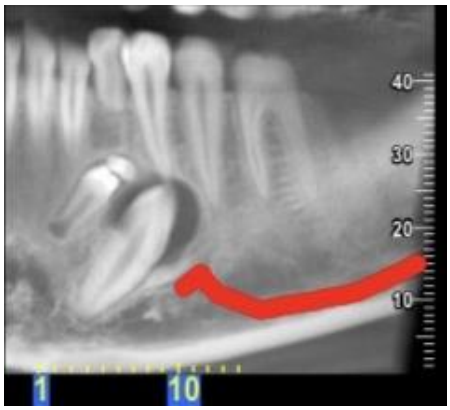

Figure 1. CBCT of Impacted canine

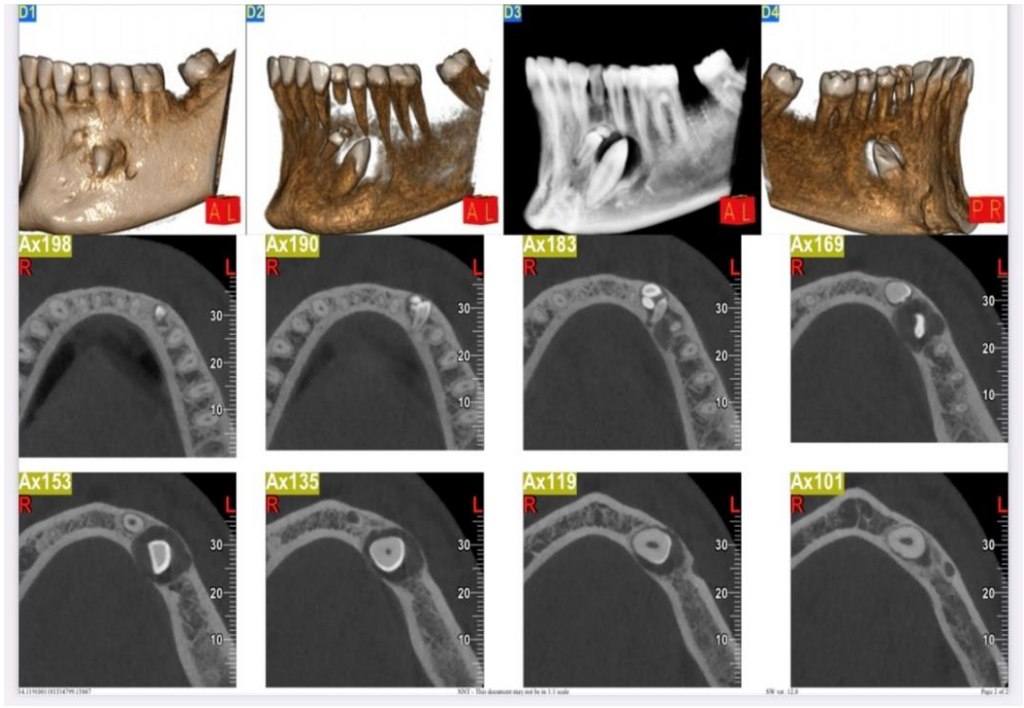

Figure 2. Mild expansion of buccal and lingual Section shows a fibrocellullar connective tissue composed of interlacing bundles of spindle-shaped fibroblasts and collagen fibers.

Based on the clinical and radiographic features, a provisional diagnosis of a dentigerous cyst (DC) was made. The differential diagnoses included odontogenic keratocyst (OKC), unicystic ameloblastoma, and radicular cyst, though the relationship of the cyst with the crown of an unerupted tooth and lack of cortical perforation favored DC.

The patient underwent surgical enucleation of the cyst under local anesthesia using an intraoral vestibular approach. The cystic lesion was carefully separated from the surrounding bone, and the associated impacted canine, supernumerary tooth, and denticle were all extracted due to their abnormal position and non-restorability. No significant intraoperative complications such as bleeding or nerve exposure were encountered.

The excised specimen was sent for histopathological evaluation. Microscopic analysis revealed a fibrous

[Downloaded from cofs.khuisf.ac.ir on 2026-11-28]

[DOI: 10.66224/cofs.4.3.3]

cystic wall lined by non-keratinized stratified squamous epithelium with focal areas containing mucous cells, confirming the diagnosis of a dentigerous cyst (Figure3)

At the 1-week and 1-month follow-up visits, the patient demonstrated uneventful healing, with complete resolution of swelling and no signs of infection or neurosensory deficits. No signs of recurrence were observed during the 6-month clinical and radiographic follow-up.

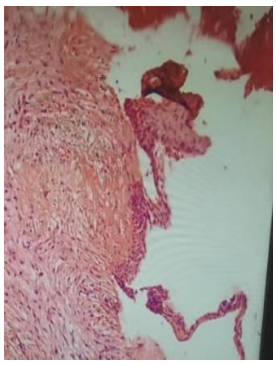

Figure 3. Histopathology image showing fibrotic cyst wall lined by non-keratinized squamous epithelium (H&E stain, light microscopy,100)

Thus, the final diagnosis of DC was made based on clinicohistopathological features operative findings.

Discussion

Of odontogenic cysts, DCs are the second most common type after radicular cysts (2). DCs occur most often around the mandibular third molar, followed by supernumerary teeth (5, 8). It has been reported that DCs occasionally occur around odontomas (9) and fused teeth (10, 11). Supernumerary teeth are most frequently observed in the maxilla, and their prevalence varies between 0.1% and 3.8% in the permanent dentition (14). One previous report stated that mesiodens are the most common supernumerary teeth, followed by premolars, lateral incisors, and fourth molars (10).

In this case report a successful spontaneous bone regeneration without grafting was seen after enucleation of the cyst followed by implant treatment after 6 months (15).

Lehl et al. (13) reported a dentigerous cyst surrounding an impacted mandibular canine in an atypical position, managed by cyst enucleation and removal of the involved tooth, with no recurrence. Our case extends this evidence by including associated structures (supernumerary tooth and denticle), utilizing CBCT for precise surgical planning, and adopting a conservative approach to preserve critical anatomical structures. DCs around supernumerary teeth account for about 5% of all DCs (8). Previous studies have revealed that the mean age of DC patients is 25.7–30 years, with 69.6–82% of patients being within the first four decades of life. Moreover, there is a male-to-female ratio of 1.75–2.80:1, with 84.8–90% of cysts originating from maxillary mesiodens (5,8). The impacted mandibular canine, mandibular supernumerary tooth and denticle is quite a rare teriad rarely documented in the literature. made the diagnosis difficult. Additionally, treatment planning was complicated by the proximity to the mental foramen and the presence of multiple unerupted structures, making this case significant both clinically and academically. Larger odontogenic cysts usually displace the involved tooth as seen in our case Odontogenic keratocysts and ameloblastomas may present similarly in radiographic images. In the present case, there was no enamel hypoplasia on the removed canine and supernumerary tooth, indicating that the cyst had formed as a result of fluid accumulation in the reduced enamel epithelium after complete crown formation. Unlike OKCs and ameloblastomas, dentigerous cysts typically present as unilocular radiolucencies with well-corticated borders surrounding the crown of an unerupted tooth (16). Histologically, the non-keratinized stratified

[Downloaded from cofs.khuisf.ac.ir on 2026-11-28]

[DOI: 10.66224/cofs.4.3.3]

squamous epithelial lining lacking palisaded basal cells and keratin production further supported the diagnosis of a dentigerous cyst.

As most DCs are asymptomatic, they are often diagnosed during radiographic examination as a part of periodic dental care or if they become symptomatic The new insight of this case is the documentation and clinical management of a rare triad: a dentigerous cyst associated simultaneously with an impacted permanent mandibular canine, an impacted supernumerary tooth, and a denticle-a combination that is extremely uncommon and emphasizes the importance of advanced imaging and individualized surgical planning to avoid complications and preserve function. DCs must be definitively diagnosed by histopathological examination. In patients who do not receive regular dental care, these cysts are likely to grow. In such cases, treatment may be necessary as soon as the lesion is diagnosed. Treatment options are enucleation (complete surgical removal), marsupialization(decompression), orthodontic-assisted eruption after marsupialization or surgical exposure.

In this case, the proximity of the lesion to the mental foramen raised concerns regarding potential injury to the inferior alveolar nerve. The use of CBCT provided precise three-dimensional localization of the impacted canine, cystic borders, and adjacent vital structures, facilitating safe surgical planning and minimizing the risk of neurosensory complications. This highlights the diagnostic value of CBCT over conventional radiography in anatomically sensitive areas (17).

Given the deep impaction and aberrant position of the mandibular canine and supernumerary tooth within the cystic cavity, and their lack of alignment with the dental arch, surgical removal was deemed necessary. Preservation was not feasible due to their unfavorable orientation and potential for future complications. This case illustrates the importance of evaluating the eruptive potential and anatomical risks when deciding between preservation and extraction in cyst-associated impacted teeth.

In the management of dentigerous cysts associated with impacted teeth, the decision to preserve or extract the involved tooth should be based on several clinical and radiographic factors, including the tooth's position and angulation, depth of impaction, stage of root development, available eruption space, and the likelihood of spontaneous or orthodontically assisted eruption (18, 19). In the present case, the impacted canine was positioned deeply and vertically within the mandible, without path of eruption. Furthermore, the presence of an associated supernumerary tooth and denticle further complicated the eruption pathway and reduced the feasibility of conservative tooth preservation. Given the unfavorable position of the impacted canine and the complexity of the associated dental anatomy, surgical enucleation of the cyst combined with removal of the associated teeth was considered the most appropriate treatment strategy.

This case contributes to the literature by emphasizing the importance of usual dental checkups and highlights anatomical considerations, eruption potential, and associated anomalies such as denticles in deciding whether to preserve or extract the involved teeth.

Displacement of the impacted canine is a well-documented finding in dentigerous cysts due to the pressure exerted by fluid accumulation. In our case, the mandibular canine was significantly deviated from its usual path, which is consistent with a similar case reported in the literature (15,13). This reinforces the importance of early radiographic examination when eruption delays are noted.

Management of a dentigerous cyst associated with an impacted permanent canine depends on several factors, including the size and extent of the cyst, age of the patient, position and potential of the impacted

[Downloaded from cofs.khuisf.ac.ir on 2026-11-28]

[DOI: 10.66224/cofs.4.3.3]

tooth to erupt, and whether the lesion is causing symptoms or affecting adjacent structures. (16,17)

Cone-beam computed tomography (CBCT) provides detailed three-dimensional information regarding the extent of the lesion and its spatial relationship with adjacent teeth and critical anatomical structures, thereby supporting individualized surgical planning in complex dentigerous cysts. However, although CT/CBCT is valuable for assessing anatomical relationships, imaging findings alone may not reliably predict postoperative neurosensory complications. (20, 21)

Learning points from this case include:

- The importance of CBCT for evaluating complex three-dimensional anatomical relationships and determining the proximity of the lesion to adjacent critical structures, thereby facilitating surgical planning. (20, 21)
- The importance of clinical and radiographic factors, including tooth position and angulation, root development, eruption space, and the likelihood of spontaneous eruption, in determining whether an associated tooth should be preserved or removed. (18, 22)
- The necessity of histopathological examination for definitive diagnosis (23).
- Early diagnosis and appropriate management may help limit lesion-related complications, including cortical expansion, displacement or resorption of adjacent teeth, and involvement of neighboring neurovascular structures. (20, 21)

Limitations include the lack of long-term follow-up Additional case series or studies with extended follow-up are needed to better understand the prognosis of similar cases, particularly those involving multiple associated structures like supernumerary teeth and denticles. (24)

Conclusion

This case highlights the importance of early and comprehensive clinical and radiographic evaluation of dentigerous cysts. The rare association of a dentigerous cyst with an impacted canine, supernumerary tooth, and denticle emphasizes the value of CBCT and histopathological examination for accurate diagnosis and treatment planning. Management should be individualized according to lesion characteristics and the developing dentition, with early intervention aimed at minimizing complications and preserving oral function.

Conflict of Interests: The authors of this manuscript declare that they have no conflicts of interest, real or perceived, financial or non-financial, in this article

References

1. Aldelaimi AAK, Enezei HH, Berum HER, Abdulkareem SM, Mohammed KA, Aldelaimi TN. Management of a dentigerous cyst; a ten-year clinicopathological study. BMC Oral Health. 2024;24(1):831.
2. Eninanç İ, Mavi E. Three-dimensional evaluation of dentigerous cysts in the Turkish subpopulation. BMC Oral Health. 2024;24:677.
3. Weir JC, Davenport WD, Skinner RL. A diagnostic and epidemiologic survey of 15,783 oral lesions. J Am Dent Assoc. 1987;115(3):439-42.
4. Benn A, Altini M. Dentigerous cysts of inflammatory origin. A clinicopathologic study. Oral Surg Oral Med Oral Pathol Oral Radiol Endod. 1996;81(2):203-9.
5. Lin HP, Wang YP, Chen HM, Cheng SJ, Sun A, Chiang CP. A clinicopathological study of 338 dentigerous cysts. J Oral Pathol Med. 2013;42(6):462-7.
6. Scheiner MA, Sampson WJ. Supernumerary teeth: a review of the literature and four case reports. Aust Dent J. 1997;42(3):160-5.

[Downloaded from cofs.khuisf.ac.ir on 2026-11-28]

[DOI: 10.66224/cofs.4.3.3]

7. Rajab LD, Hamdan MA. Supernumerary teeth: review of the literature and a survey of 152 cases. Int J Paediatr Dent. 2002;12(4):244-54.
8. Lustmann J, Bodner L. Dentigerous cysts associated with supernumerary teeth. Int J Oral Maxillofac Surg. 1988;17(2):100-2.
9. Wanjari SP, Tekade SA, Parwani RN, Managutti SA. Dentigerous cyst associated with multiple complex composite odontomas. Contemp Clin Dent. 2011;2(3):215-7.
10. Patel K, Patel N, Venkataraghavan K. Management of a dentigerous cyst associated with inverted and fused mesiodens: a rare case report. J Int Oral Health. 2013;5(4):73-7.
11. Abrams RA, Nelson DL. Fusion of a third molar to a supernumerary tooth with an associated dentigerous cyst. Aust Dent J. 1979;24(3):141-2.
12. Nag R, Singh J, Chhabra U, Mathur J. Surgical management and prosthetic rehabilitation of dentigerous cyst associated with impacted mandibular canine: a case report. J Pharm Bioallied Sci. 2022;14(Suppl 1):S1070-S1073.
13. Lehl G, Chinna K, Bakshi V. Dentigerous cyst with an impacted canine in an unusual position: a case report. J Indian Soc Pedod Prev Dent. 2000;18(1):38-40.
14. Sathyanarayana HP, Nucci L, d'Apuzzo F, Perillo L, Padmanabhan S, Grassia V. Prevalence, etiology, clinical features and management associated with impacted and transmigrated mandibular canines: a systematic review. BMC Oral Health. 2023;23(1):975.
15. Nag R, Singh J, Chhabra U, Mathur J. Surgical Management and Prosthetic Rehabilitation of Dentigerous Cyst Associated with Impacted Mandibular Canine: A Case Report. J Pharm Bioallied Sci. 2022;14(Suppl 1):S1070-S1073.
16. Shear M, Speight PM. Cysts of the Oral and Maxillofacial Regions, 4th ed. Wiley-Blackwell; 2007
17. Scarfe WC, Farman AG. What is cone-beam CT and how does it work? Dent Clin North Am. 2008;52(4):707-730.
18. Nahajowski M, Hnitecka S, Antoszewska-Smith J, Rumin K, Dubowik M, Sarul M. Factors influencing an eruption of teeth associated with a dentigerous cyst: a systematic review and meta-analysis. BMC Oral Health. 2021;21(1):180.
19. Motamedi MH, Talesh KT. Management of extensive dentigerous cysts. Br Dent J. 2005;198(4):203-6.
20. Dave M, Taylor T, Cieplik F, et al. Adapting treatment approaches for dentigerous cysts in paediatric and adult patients: a case series. Oral Surg. 2021; 14: 277-284
21. Yamada S, Osanai H, Mori K, Sugino N, Taguchi A. Association between CT image findings and hypoesthesia in the mental region and lower lip after dentigerous cyst removal: a retrospective study and literature review. Oral Radiol. 2025;41(3):414-420.
22. Cobo-Vázquez C, Fernández-Gutiérrez L, Pérez-Fernández B, Sánchez-Labrador L, Martínez-Rodríguez N, Martínez-González JM, et al. Effectiveness of conservative treatment of dentigerous cyst in the pediatric patient: a systematic review. J Stomatol Oral Maxillofac Surg. 2025;126(4):102115.
23. Caruso DP, Lee CC, Peacock ZS. What factors differentiate dentigerous cysts from other pericoronal lesions? Oral Surg Oral Med Oral Pathol Oral Radiol. 2022;133(1):8-14.
24. Nissen T, Wynn R. The clinical case report: a review of its merits and limitations. BMC Res Notes. 2014;7:264..

[Downloaded from cofs.khuisf.ac.ir on 2026-11-28]

[DOI: 10.66224/cofs.4.3.3]