Contemporary Orofacial Sciences (2026) 4(3): 17-21
DOI: 10.66224/cofs.4.3.1

ORIGINAL ARTICLE

Frequency of Non-Odontogenic Lesions in Biopsied Jaw Lesions: A Single-Institutional Retrospective Study

Hamid Shajan[1], Atousa Aminzadeh[2], Mehdi Abrishami[3*], Iman Hassanzadeh[4]

Received: 2026-02-28/ Accepted: 2026-07-14 / First publication date: 2026-09-16

© The Author(s) 2026

Abstract

Background: Existing research has mostly focused on odontogenic lesions of the jaws; therefore, due to the lack of sufficient studies and the importance of non-odontogenic lesions, this study aimed to evaluate the epidemiologic profile of these lesions in a series of biopsied lesions.

Materials and Methods: To conduct this retrospective study, the oral pathology department archive of Isfahan Azad Dental School from 2010 to 2025 was reviewed for lesions with a definitive diagnosis of non-odontogenic lesions. Demographic and clinical information of each lesion was recorded. The results were analyzed using the chi-square statistical test in SPSS26 software(α=0.05).

Results: Among 1054 jaw bone lesions, 39 nonodontogenic lesions were found (3.7%). The age of the subjects at the time of biopsy ranged from 8 to 59 years, with a mean of 35.7 ± 12.3. The most common lesions were non-odontogenic tumors (38.5%). Lesions were mostly seen in the lower jaw (93.3%), which was related to the type of disease (P = 0.04). Lesions most commonly occurred in females (61.5%), although the Chi-square statistical test did not show this finding as significant (p=0.41). One patient used long-term medication, and two had systemic diseases with no relation to the diagnosis.

Conclusion: Non-odontogenic benign tumors were the most common type of lesion in this study. seen mostly in female patients and in the mandible. For better understanding of these lesions, future multicenter studies are recommended.

Keywords: Jaw Diseases; Nonodontogenic Cysts; Jaw Neoplasms; Bone Cysts; Neoplasms

Introduction

Non-odontogenic lesions are relatively rare; however, a delayed diagnosis and inadequate treatment of these lesions may result in irreversible complications for patients. The jaw bones may be affected by various non-odontogenic lesions, including reactive disorders, inflammatory or infectious diseases, cysts, and tumors (benign and malignant) (1).

Jaw bones have the highest incidence of cysts in the human body. This is due to the large number of epithelial debris that can remain in the jaw bones, including both odontogenic epithelium, which is derived from the tooth-forming apparatus, and non-odontogenic epithelium, which is derived from remnants of embryonic phase of development (1-4). Non-odontogenic cysts are uncommon lesions compared to odontogenic cysts (5). The most recent classification system for non-odontogenic jaw cysts includes Nasopalatine duct cyst, Median maxillary cyst, and Palatine cyst of newborn. Globulomaxillary cyst and Median mandibular cyst are no longer recognized as distinct pathologic cysts within current dental literature. Pseudodontogenic cysts include Stafne cyst, aneurysmal bone cyst, and simple or traumatic bone cyst (5, 6).

Corresponding author: Mehdi Abrishami

Department of Oral and Maxillofacial Surgery, Faculty of Dentistry, Isf.C., Islamic Azad University, Isfahan, Iran
Email: mehdieabrishami@iau.ac.ir

1. Faculty of Dentistry, Isf.C., Islamic Azad University, Isfahan, Iran.
2. Department of Oral and Maxillofacial Pathology, Faculty of Dentistry, Isf.C., Islamic Azad University, Isfahan, Iran.
3. Department of Oral and Maxillofacial Surgery, Faculty of Dentistry, Isf.C., Islamic Azad University, Isfahan, Iran.
4. Department of Oral and Maxillofacial Surgery, School of Dentistry, Isf.C., Islamic Azad University, Isfahan, Iran.

[Downloaded from cofs.khuisf.ac.ir on 2026-11-28]

[DOI: 10.66224/cofs.4.3.1]

Osteoma, Osteoblastoma, Chondroma, Ossifying fibroma, Primary squamous cell carcinoma, Osteosarcoma, Chondrosarcoma, Ewing sarcoma, Plasmacytoma, Multiple myeloma, and various Metastatic lesions are categorized as benign and malignant tumoral lesions of bone and/or related structures. Besides cysts and tumors, multiple reactive and inflammatory lesions can be seen in jaw bones, including Central giant cell granuloma, Osteomyelitis, Eosinophilic granuloma, Fibrous dysplasia and fibro-osseous lesions (6,7).

Proper identification and management of these lesions is critical for preventing further progression of the lesion and subsequent complications. Dental professionals must have a complete knowledge of jaw lesions, including their epidemiology, demography, and clinical characteristics for more precise clinical differential diagnosis, treatment planning, and better prognosis and outcome for the patient. Thus, our study aimed to evaluate the epidemiology of non-odontogenic biopsied lesions of jaws in a small group of Iranian patients gathered from one institutional oral pathology laboratory archive.

Materials and methods

To conduct this retrospective study (ethics code IR.IAU.KHUISF.REC.1404.568) the archive of oral pathology department of Isfahan Islamic Azad Dental School from 2010-2025 was reviewed. Due to the limited size of the targeted population and accessibility of all samples to ensure highest level of accuracy and validity a census method was employed. Specimens with a microscopic diagnosis of non-odontogenic lesions related to the jaw bones were selected and included in the study. Microscopic slides were revised by a pathologist to confirm the diagnosis. Clinical information including age, gender, underlying diseases and medications, history of trauma or severe infection, and location of the lesions were extracted and recorded. Statistical analysis was performed using chi-square and one-way ANOVA at an error level of 0.05 in SPSS 26 software. The gathered information was kept confidential and used only for research purposes. The patients' identities were not disclosed at any stage of the research. This study used biopsy samples previously collected for therapeutic purposes and no new sampling was performed.

Results

Among 1054 jaw bone lesions, only 39 (3.7%) nonodontogenic lesions were identified. Lesions reported in the studied archive composed of True cysts (Nasopalatine cyst), pseudocysts, aneurysmal bone cyst and Traumatic bone cyst tumors consisting of benign tumors of Osteoma and Ossifying fibroma and one case of malignant bone tumor: Chondrosarcoma. Infectious and metabolic lesions included Osteomyelitis, fibro-osseous lesions, and Giant cell granuloma.

The age of the subjects at the time of biopsy ranged from 8 to 59 years, with a mean of 35.7 ± 12.3 years (Table 1), which, based on the results of ANOVA analysis, did not show a statistically significant difference between groups (P value=0.17).

Table 1. The age distribution of patients in each group.

Type of lesion	Mean ± SD
True cysts	34.7 ± 14.7
Pseudo cysts	24.7 ± 8.2
Tumors	35.1 ± 9.6
Infected and reactive lesions	40.1 ±13.5

The most diagnosed non-odontogenic lesions were, in descending order, tumors, reactive or inflammatory lesions, pseudocysts and true cysts (Table 2).

[Downloaded from cofs.khuisf.ac.ir on 2026-11-28]

[DOI: 10.66224/cofs.4.3.1]

Table 2. Frequency distribution of upper or lower jaw involvement, jaw segment involved and gender distribution of lesions is shown.

lesion	N (%)	Maxilla N (%)	Mandible N (%)	P value	Anterior %	Premolar %	Molar %	Molar and premolar	P value	Female N (%)	Male N(%)	P value
True cyst	6 (15.4)	6 (100%)	0(0%)		100	0	0	0		2	4	
Pseudocyst	4(10.3)	1(25%)	3(75%)		25	0	50	25		3	1	
Tumors	15 (38.5)	1(6.7%)	14(93.3%)	<0.001	30.7	0	61.7	7.6	0.04	9	6	0.41
Infectious and Reactive	14 (35.9)	1(7.1)	13(92.8%)		10	10	50	30		10	4	

Lesions mostly occurred in the mandible, which was statistically significant (p value <0.001). The location of lesions in different segments of the jaws was related to the type of lesion, as shown in Table 2 and Figure1 (P value = 0.04). Lesions most commonly occurred in females (61.5%), although the Chi-square statistical test did not show this finding as significant (P value =0.41). One patient used long-term medication, and two had systemic diseases with no relation to the bone pathology diagnosed.

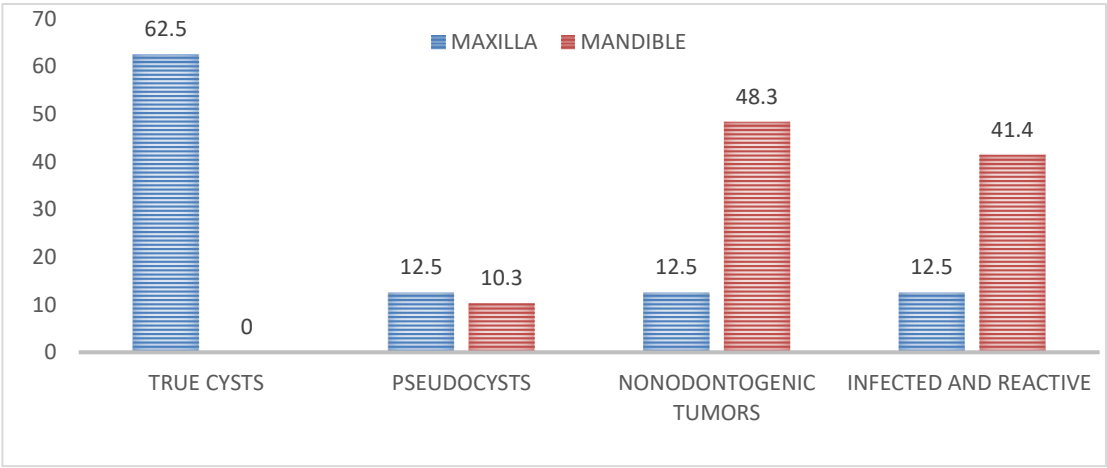

Figure 1. Comparison of non-odontogenic jaw lesions between upper and lower jawbone

Discussion

The aim of our study was to study the epidemiology of non-odontogenic lesions. The frequency of non-odontogenic jaw lesions in our archive was 3.7%. Benign tumors were the most common lesion, followed by infectious and reactive lesions, pseudocysts and cysts, respectively. In the study of Naeini et al., the most common non-odontogenic bone lesions were central giant cell granuloma, ossifying fibroma, osteomyelitis, aneurysmal bone cyst, and nasopalatine duct cyst (8, 9). In the study by Johnson et al. (10), the most frequent nonodontogenic lesion was nasopalatine cyst, followed by inflammatory and reactive lesions, including fibrous dysplasia and giant cell granuloma.

The jaw involved in most of the studied cases (76.9%) was the mandible, which was in accordance with the studies performed by Naeini et al., Dehghanzadeh et

[Downloaded from cofs.khuisf.ac.ir on 2026-11-28]

[DOI: 10.66224/cofs.4.3.1]

al. (1), Oner and Semiz (11), and Okoh et al (12) and Tamgadge et al (13).

Although the mandible was the most common site of lesions, the frequency distribution of the location of involvement was related to the type of the lesion (P value =0.04). The frequency of true cysts in the maxilla was higher than in the mandible, and the frequency of tumours, inflammatory, and reactive lesions in the mandible was higher than in the maxilla. The frequency of pseudocysts in the maxilla and mandible was almost the same.

In our study, the only true cyst observed was a nasopalatine cyst. In the study of Klink et al., the nasopalatine cyst was also noted as the only non-odontogenic cyst observed (14). In the study performed by Siadati et al. (15), mucous retention cysts were reported as the most common non-odontogenic cysts, and in the study of Uchoa-Vasconcelos et al. (16), nasopalatine cysts, lymphoepithelial cysts, and epidermoid cysts were reported as the most common non-odontogenic cysts. The reason for this discrepancy is that in our study, only non-odontogenic intraosseous lesions were addressed, while in the study by Siadati and Uchoa-Vasconcelos, the epidemiological profile of soft and hard tissue lesions was examined together (15, 16).

Both Aneurysmal bone cysts and traumatic bone cysts were reported which were seen involving molar and premolar segments together. Tumors consisted mainly of benign lesions mostly osteoma, ossifying fibroma with a higher incidence in the molar region. Only one single case of malignancy was found, which was a chondrosarcoma of anterior mandible. Johnson et al. (10) believe benign lesions are 6.8% more common than malignant lesions in non-odontogenic lesions of the jaws. Tamgadge et al (13) studied non-odontogenic malignant tumors and mentioned only 1.4% of these lesions had connective tissue origin and were mainly in men. However, in our study the one nonodontogenic malignant lesion was seen in a female patient. Inflammatory and reactive lesions included osteomyelitis, fibro-osseous lesions, and giant cell granuloma, which were seen throughout the jaws.

Twenty-four (61.5%) of the subjects were female and 15 (38.5%) were male, although this difference was not statistically significant (P value= 0.41). In the study by Naini et al. (8), similar to our study, non-odontogenic lesions were mostly discovered in female patients. In the study by Kilink et al. (14) and Dehghanzadeh et al. (1), jaw lesions were reported more frequently in men. Of course, in the aforementioned studies, odontogenic and non-odontogenic lesions were examined together, which may be the reason for the difference in the results obtained in those studies and our study. A relation between gender and type of the lesion was observed, although it was not statistically significant. As True the true cyst of nasopalatine were more common in males, while pseudocysts, tumours, and inflammatory and reactive lesions were more common in females. In the study by Uchoa-Vasconcelos et al. (16), nasopalatine cysts were also seen more frequently in men than in women.

A more thorough classification of non-odontogenic tumors of the jaw, based on tissue of origin other than bone, was introduced by Shaw and Chan (7), which includes tumors of histiocytic, fat, nerve and vascular tissues. In our studied population, no such lesions were reported.

The age of the subjects at the time of biopsy ranged from 8 to 59 years, with a mean of 35.7 and a standard deviation of 12.3 years. Similar to our study, in the study by Oner and Samiz (11), the mean age of the patients was 38.34. But in the study by Naeini et al., the mean age of the patients was 29.09 ± 16.90, a decade younger than patients in our study and the study performed by Oner and Samiz (11). This might be due to the different types of lesions in each study,

[Downloaded from cofs.khuisf.ac.ir on 2026-11-28]

[DOI: 10.66224/cofs.4.3.1]

although the results of our study showed that the age of the subjects at the time of biopsy had no significant relationship with the type of lesion (P value= 0.17). Small sample size was a limitation for our study; thus, future studies with multi cantered, larger sample size are recommended.

Conclusion

In our study, the most reported non-odontogenic lesions, in descending order were tumors, infectious/reactive lesions, true cyst and pseudocysts . Lesions showed relation with location as true cyst was just reported in the maxilla. Tumors, infectious /reactive lesions and pseudo cysts were seen mostly in mandible. True cysts were reported in the anterior segment of jaw, but tumors, infectious /reactive lesions and pseudocysts were seen in the posterior segments in both jaws.In the premolar segment only infectious/reactive lesions were reported . For better understanding of these lesions, multicenter studies for more sample size are recommended.

Conflict of Interests: The authors of this manuscript declare that they have no conflicts of interest, real or perceived, financial or non-financial, in this article

References

1. Dehghanzadeh A, Aminzadeh A, Khodarahmi MJ, Shafazand MH. Prevalence and Clinical Features of Biopsied Jaw Lesions in an Iranian Population Patient in During a Period of 7 Years. J Isfahan Dent Sch 2022; 18(2): 121-6.
2. McKinney R, Menicucci C, Brizuela M. Non-Odontogenic Cysts. [Updated 2025 Dec 1]. In: StatPearls [Internet]. Treasure Island (FL): StatPearls Publishing; 2025 Jan-. Available from: https://www.ncbi.nlm.nih.gov/books/NBK572126/
3. da Silva LP, Gonzaga AK, Severo ML, Barros CC, de Medeiros AM, de Souza LB, et al. Epidemiologic study of odontogenic and non-odontogenic cysts in children and adolescents of a Brazilian population. Med Oral Patol Oral Cir Bucal. 2018;23(1):e49-53.
4. Shakerian P, Attarzadeh H, Jalalian F, Parham E. The prevalence and distribution of anomalies of permanent teeth in 6-17-year-old children in a selected Iranian Population. cofs 2026; 4(2):13-23.
5. Chantarangsu S, Kulthanaamondhita P, Dhanuthai K, Sappayatosok K, Klanrit P, Chamusri N, et al. Prevalence and Clinico-Pathologic Profiles of Nonodontogenic Cysts of the Oral and Maxillofacial Region: A Multicentre Study. Int J Dent. 2025; 2025:4344848.
6. Neville BW, Damm DD, Allen CM, Chi AC. Oral and Maxillofacial Pathology. 5th ed. St. Louis (MO): Elsevier; 2023.
7. Shaw SE, Chan CH. Non-Odontogenic Tumors of the Jaws. [Updated 2023 Jul 25]. In: StatPearls [Internet]. Treasure Island (FL): StatPearls Publishing; 2025 Jan-Available from: https://www.ncbi.nlm.nih.gov/books/NBK576441.
8. Naini FB, Aminishakib P, Ghorbanpour M, Vakili MM, Kharazifard MJ. Demographic Profile of Non-Odontogenic Jaw Lesions in an Iranian Population: A 30-Year Archive Review. J Dent (Tehran). 2017; 14(3): 132-137.
9. Abrishami M, Aminzadeh Gohari A, Hoveida L, Hasani B, Abdollahzadeh H. Periapical Actinomycotic Infection: Review of published Case Reports. cofs 2026; 4(2):44-49.
10. Johnson NR, Savage NW, Kazoullis S, Batstone MD. A prospective epidemiological study for odontogenic and non-odontogenic lesions of the maxilla and mandible in Queensland. Oral Surg Oral Med Oral Pathol Oral Radiol 2013;115(4):515-22.
11. Oner B, Semiz HD. Retrospective Evaluation of Odontogenic and Nonodontogenic Cysts in the Jaws in the Series of 147 Cases. Oral Health Dental Sci. 2020; 4(1); 1-9.
12. Okoh DS, Okoh M, Omoregie FO, Ojo MA. A study on the clinical indicators in the diagnosis of orofacial nonodontogenic tumors. J Cancer Res Ther. 2019;15(3):608-614.
13. Tamgadge S, Anjali AK, Pereira T, Deshmukh Y, Mehta J, Kharat S, et al. Malignant Non-Odontogenic Tumors of the Oral Cavity - Single Institutional Retrospective Study of Three Decades. Indian J Community Med. 2025;50(3):530-534.
14. Kilinc A, Gundogdu B, Saruhan N, Yalcin E, Ertas U, Urvasizoglu G. Odontogenic and nonodontogenic

[Downloaded from cofs.khuisf.ac.ir on 2026-11-28]

[DOI: 10.66224/cofs.4.3.1]

cysts: An analysis of 526 cases in Turkey. Niger J Clin Pract 2017; 20(7):879-883

15. Siadati S, Khorram N, Mirzapour M. Oral and jaw lesions in adults: A 19-year retrospective study in northern Iran. Iran J Pathol. 2013;8(3):159–64.
16. Uchoa-Vasconcelos AC, Filizola-de Oliveira DJ, Roman-Martelli SJ, Etges A, Neutzling-Gomes AP, Chaves-Tarquínio SB. Demographic profile of oral nonodontogenic cysts in a Brazilian population. Med Oral Patol Oral Cir Bucal. 2014;19(4):e308-12.

[Downloaded from cofs.khuisf.ac.ir on 2026-11-28]

[DOI: 10.66224/cofs.4.3.1]