

## Evaluation of Mandibular Indexes for Sex Estimation by Use of CBCT Imaging in Iranian population samples

Alireza Fereidooni Naghani<sup>1</sup>, Arash Ghodousi<sup>2</sup>, Roshanak Ghafari<sup>3</sup>, Somayeh Abbasi<sup>4</sup>

Received: 2022-12-31 / Accepted: 2023-05-02 / First publication date: 2023-05-10  
© The Author(s) 2023

### Abstract

**Background:** Identification of skeletal remains is crucial in forensic medicine, and one of the important subjects for identifying skeletal remains is sex estimation. the present study aimed to investigate some of the anthropological features of the mandible used for forensic sex estimation with the use of CBCT images.

**Materials & Methods:** In this descriptive-analytical study, CBCTs of eighty patients were studied. The studied variables were the mediolateral, and anteroposterior dimensions of the condyle, the ante gonial angle, the longitudinal axis of the condylar angle, and the vertical height of the coronoid process. The above parameters were measured using OnDemand software, and statistical analysis was performed using SPSS software. Independent and Paired T-tests, Discriminant and Receiver operating characteristic (ROC) curves were used for statistical analysis. P values less than 0.05 were considered significant.

**Results:** The condyle mediolateral average dimension for males was significantly higher than for females ( $p < 0.001$ ). Three discriminant analysis models, the first based on the measurements on the right, the second based on the measurements on the left and the third based on mean measurements on both sides, were developed for sex estimation. The area under the receiver operating characteristic (ROC) curve was used for quality assessment of the fitted models and determination of their prediction ability. The ability of all three discriminant models to do sex estimation was obtained by at least 70%. Also, using the ROC curve, the third model was more efficient in sex estimation (area=0.869,  $p < 0.001$ ).

**Conclusion:** The mediolateral dimension of the mandibular condyle process is a useful parameter in sex estimation. Classification accuracy is more than 80% in all models. Different methods should be used together to make more accurate results of sex estimation and one method alone is not sufficiently advised.

**Keywords:** Forensic medicine, Sex estimation, Mandible, Cone beam computed tomography (CBCT), Discriminant analysis

### Introduction

Sex estimation is one of the main branches of forensic medicine that is especially important in cases where information about the deceased is unavailable. As a principle, it is indicated that sex estimation is the highest priority for a forensic pathologist, and in some cases such as the explosion of chemical and nuclear bombs, crime investigations, natural disasters, and ethnic studies, the role of sex estimation becomes more

prominent (1,2) Sexual dimorphism is the phenotypic difference between males and females, or more simply the apparent difference in a species.(3)

The mandibular bone is the largest, strongest, and lowest bone in the face and the only moving bone in the skull. This bone has received much anthropological attention from researchers, and many have pointed to its sexual differences (4). In 2010, Jose et al. Examined the morphological changes of the mandibular condyle from childhood to adulthood (3 to 20 years) using Cone beam computed tomography (CBCT) in Brazil and reported that there was not a significant difference between the mean size of the anterior-posterior dimension of the condyle and the mediolateral dimension of the right and left condyles (5).

Wangai et al. (6) also stated that there is no significant difference between the condylar angle on the right and

**Corresponding Author:** Arash Ghodousi

<sup>1</sup> School of Dentistry, Islamic Azad University, Isfahan (Khorasgan) Branch, Isfahan, Iran

<sup>2</sup> Community Health Research Center, Isfahan (Khorasgan) Branch, Islamic Azad University, Isfahan, Iran

<sup>3</sup> Department of oral Radiology, School of Dentistry, Isfahan (Khorasgan) Branch, Islamic Azad University, Isfahan, Iran

<sup>4</sup> Department of Mathematics, Isfahan (Khorasgan) Branch, Islamic Azad University, Isfahan, Iran

left sides in females and males.

Subbaramaiah and Jagannatha (7) examined mandibular indexes on the dry mandible and stated a significant difference in coronoid height between men and women on the right and left that can be used as a convenient indicator in determining gender.

Tafakheri et al. (8) reported a greater ante gonial angle in women compared to men.<sup>8</sup>

Abbasi et al. (9) examined sex determination using the area and dimensions of the maxillary sinus.

Since epigenetic factors and, of course, social circumstances, race, and eating habits play a major role in the development of sexual dimorphisms, as well as few studies on the use of coronoid (which show little bone resorption and remain unchanged for a long time), angle and The dimensions of the condyle in sex estimation have been performed on CBCT, In this study, we decided to study some of the anthropological parameters of the mandibular bone in both females and males using CBCT images.

## Materials and Methods

This cross-sectional descriptive-analytic study examined the archived CBCT of the patients who visited the Radiology Department of Islamic Azad University of Isfahan (Khorasgan), during summer-fall 2019. This study has been approved by the Ethics Committee of Yazd Azad University (IR.IAU.YAZD.REC.1399.01). The research population consisted of 20-45-year-old individuals visiting the Radiology Department of Islamic Azad University of Isfahan (Khorasgan). In discriminant analysis, the sample size (n) should fulfil the following criteria

$$\min n \geq x + 2.$$

Where x is the number of independent variables. Abbasi et al. (2019) considered forty males and forty females. In this research, the study group comprises eighty subjects (40 males and 40 females) 20-45 years old. CBCT images of patients referred to the radiology department were used and patients did not receive any additional radiation.

They were selected by convenience nonrandom sampling. Patients who had facial trauma or mandibular bone fracture or surgery, were completely edentulous, or had severe problems or TJM problems, were excluded from the study.

In the images where the mandibular condyle head was flat, the CBCT images were unclear, or the patients who had an asymmetric face were excluded from the study. After taking all the needed permission, the following measurement with the help of OnDemand software in the Radiology department by a trained dental student and with help of a maxillofacial Radiologist was done. First in On-demand software with Axis and Reslice option corrected patient head position in three plans and then the following indexes have been measured.

1- Determination of mean value of ante gonial angle in male and female on right and left in an oblique sagittal segment (Figure 1)

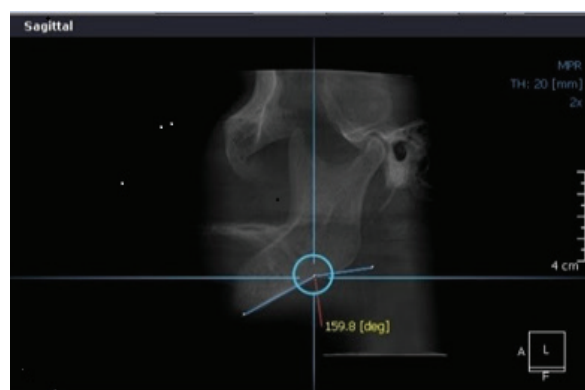


Figure 1. Method of calculation of antegonial

2- Measurement of the anteroposterior dimension of the mandibular condyle in corrected Lateral view (along the long axis of condyle) on right and left (Figure 2A)

3- Determination of mean value of mediolateral width of the mandibular condyle in corrected coronal view (along the long axis of condyle) (Figure 2B)

4- Determination of condylar long axis Angle with a midsagittal plan in an axial segment on the right and left (Drawing of the long axis of both condyles this line passes in front of the foramen magnum and then Drawing midsagittal line (same as picture) and in junction

of the long axis and midsagittal line drawing a horizontal line and measuring the condylar angle) (Figure 2C)

5- Determination of the vertical height of the coronoid in thickened sagittal view (Drawing a horizontal line from the sigmoid notch and coronoid head and drawing a line over that) (Figure 2D)

A. Dimensions of anteroposterior of condyle (corrected lateral view)

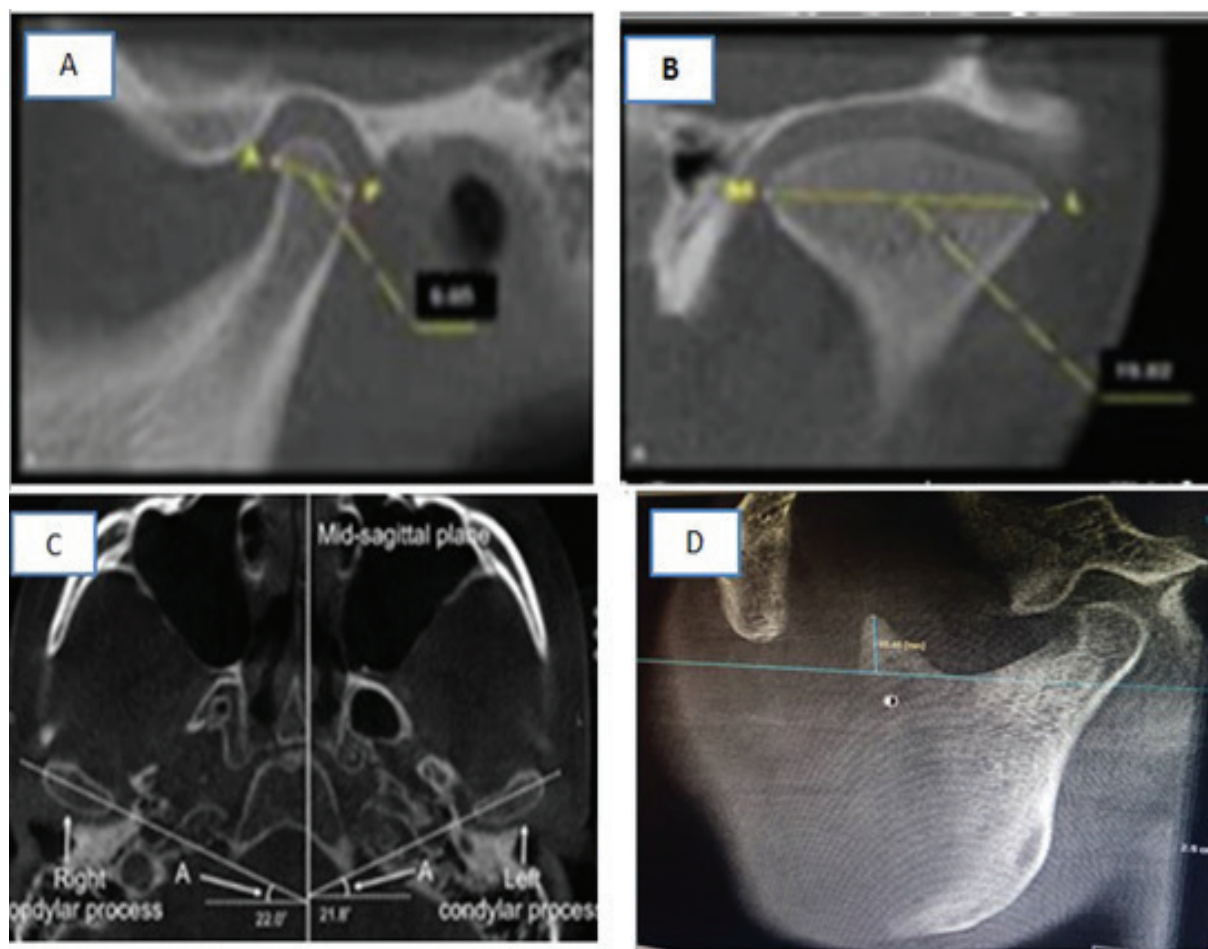
B. Dimensions of mediolateral of condyle ((corrected coronal view)

C. Angle of long axis of mandible (Axial segment)

D. Vertical height of coronoid (thickened sagittal view)

The obtained results were analyzed using descriptive and inferential statistics in SPSS 26. The mean and standard deviation of the mediolateral dimension of the condyle, the anteroposterior dimension of the condyle, the ante gonial angle, the longitudinal axis of the condylar angle, and the vertical height of the coronoid process in males and females were obtained and tabulated using a descriptive test (t-test). These variables were compared between males and females with 95% confidence intervals (CI).

Discriminant function analysis was performed for sex estimation. Linear discriminant equations were also derived with sex as a classifying variable and the



**Figure 2.** Showing process of measurement of indexes of anthropological of mandible briefly

mediolateral dimension of the condyle, the Antero-posterior dimension of the condyle, the ante gonial angle, the longitudinal axis of the condylar angle, and the vertical height of the coronoid process as independent variables. The discrimination scores were obtained and sex differentiation was conducted accordingly. The receiver operating characteristic (ROC) curves were used for selecting possibly optimal models. P values less than 0.05 were considered significant.

## Results

At first, the assumption of normality of variables was investigated by the Kolmogorov-Smirnov test. Since the significance level of the normal test for research variables is more than 0.05 ( $P > 0.05$ ). All variables had normal distribution, and then paired t-test was used to investigate the significant difference between left and right dimensions in variables and the results were presented in (Table 1). Since the significance level of paired T-test in the mediolateral dimension of the condyle, the Antero-posterior dimension of the condyle and the vertical height of the coronoid is more than 0.05, the assumption of means equality on the left and right is confirmed. However, ante gonial angle and the longitudinal axis of the condylar angle tests were

significant and the right and left means are not equal.

To compare the research variables between males and females independent T-test was used (Table 2). T-test was significant for the right, left and mean of the left and right of the mediolateral dimension of the condyle ( $P < 0.001$ ). Therefore, the mediolateral dimension of the condyle was significantly higher in males than in women. In other variables, the t-test was not significant ( $P > 0.05$ ).

Sex estimation was the main purpose of this study. Since the mean dimensions of left and right were significantly different in some variables, to reduce the error, we presented three models of discriminant analysis. Discriminant analysis was performed using sex as a grouping variable and the right mediolateral dimension of the condyle, right Antero-posterior dimension of the condyle, right ante gonial angle, the right longitudinal axis of the condylar angle, and right vertical height of the coronoid as independent variables in model 1. The left sizes of the mentioned variables were independent variables in model 2 and the mean of the left and right sizes of the mentioned variables were independent variables in model 3. In all three models, the significance level of the Box' M tests

**Table 1.** Paired T-test in comparison between left and right sides of variables

	Side	n	Mean± SD (mm)	P-value
Mediolateral dimension of the condyle	Right	40	16.48 ± 2.72	0.094
	Left	40	16.76 ± 2.65	
Antero-posterior dimension of the condyle	Right	40	6.54 ± 1.29	0.48
	Left	40	6.48 ± 1.07	
Ante gonial angle	Right	40	169.4 ± 7.99	0.031
	Left	40	167.8 ± 6.94	
Longitudinal axis of the condylar angle	Right	40	22.87 ± 3.93	<0.001
	Left	40	20.06± 4.12	
Vertical height of the coronoid	Right	40	11.81 ± 3.37	0.081
	Left	40	11.47 ± 3.36	

**Table 2.** Independent T-test in comparison between males and females

	Side	Mean± SD (mm)		P-value
		males	females	
Mediolateral dimension of the condyle (mm)	Right	17.84±2.64	15.13±1.75	<0.001
	Left	18.00±2.51	15.53±2.20	<0.001
	mean	17.92±2.57	15.33±1.87	<0.001
Antero-posterior dimension of the condyle (mm)	Right	6.54±1.25	6.55±1.35	0.985
	Left	1.09±6.60	6.35±1.04	0.290
	mean	1.09±6.57	6.45±1.14	0.618
Ante gonial angle (degree)	Right	167.99±8.86	170.82±6.84	0.113
	Left	166.46±7.55	169.23±6.06	0.075
	mean	167.23±7.24	170.03±6.06	0.065
Longitudinal axis of the condylar angle (degree)	Right	23.14±4.59	22.60±3.17	0.545
	Left	20.42±3.94	19.71±4.32	0.443
	mean	21.78±3.66	21.15±3.31	0.426
Vertical height of the coronoid (mm)	Right	12.08±3.28	11.54±3.48	0.477
	Left	11.49±3.44	11.44±3.32	0.953
	mean	11.78±3.22	11.49±3.32	0.691

**Table 3.** Classifications function coefficients

	Model 1 (right)		Model 2 (left)		Model 3 (mean)	
	females	males	females	males	females	males
Mediolateral dimension of the condyle	-1.959	-1.338	0.701	1.355	-1.361	-0.567
Antero-posterior dimension of the condyle	6.321	6.100	3.774	3.423	5.862	5.358
Ante gonial angle	3.886	3.755	2.875	2.794	4.232	4.094
Longitudinal axis of the condylar angle	1.150	1.215	2.862	2.952	3.097	3.218
Vertical height of the coronoid	.607	.573	.644	.626	.823	.780
(constant)	-	-	-	-	-406.421	-395.173
	349.208	337.014	299.996	296.627		

was more than 0.05, so the assumption of the equality of variance-covariance matrix between males and females was confirmed and the assumptions of linear discriminant analysis were established. In all three models, the significance level of Wilke’s lambda tests was less than 0.05 ( $p<0.001$ ), and we concluded that the linear discriminant analysis models were appropriate. In other words, the means of male and female groups in the presence of research variables were different and the allocation of the appropriate model was significant. In model 1, linear discriminant equations for two groups of males ( $Y_1$ ) and females ( $Y_2$ ) were obtained as:

$$Y_1 = -337.014 - 1.338X_1 + 6.100X_2 + 3.755X_3 + 1.215X_4 + 0.573X_5$$
$$Y_2 = -349.208 - 1.959X_1 + 6.321X_2 + 3.886X_3 + 1.150X_4 + 0.607X_5$$

Where the variables  $X_1$ ,  $X_2$ ,  $X_3$ ,  $X_4$  and  $X_5$  are the mediolateral dimension of the condyle, antero-posterior dimension of the condyle, antegonial angle, Longitudinal axis of the condylar angle and Vertical height of the coronoid, respectively.

In model 2, linear discriminant equations for two groups of males ( $Y_1$ ) and females ( $Y_2$ ) were obtained as:

$$Y_1 = -296.627 + 1.355X_1 + 3.423X_2 + 2.794X_3 + 2.952X_4 + 0.626X_5$$
$$Y_2 = -299.996 + 0.701X_1 + 3.774X_2 + 2.875X_3 + 2.862X_4 + 0.644X_5$$

In model 3, linear discriminant equations for two groups of males ( $Y_1$ ) and females ( $Y_2$ ) were obtained as:

$$Y_1 = -395.173 - 0.567X_1 + 5.358X_2 + 4.094X_3 + 3.218X_4 + 0.780X_5$$
$$Y_2 = -406.421 - 1.361X_1 + 5.862X_2 + 4.232X_3 + 3.097X_4 + 0.823X_5$$

Sex can be predicted by substituting the values of

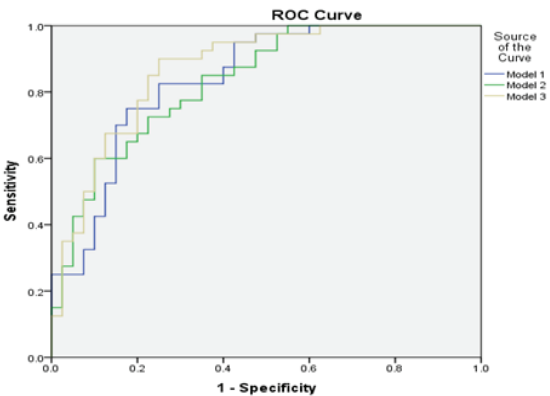
specific measurements in the above equations. A larger calculated Y indicates sex.

In model one, model 2 and model 3, sex estimation was predicted 77.5%, 72.5% and 78.8% as respectively, correctly, in the sample studied.

As seen in (Table 4) and (Figure 3), the larger area under the ROC curve suggested model 3 as the optimal model for sex prediction. Therefore, sex prediction using mean of left and right sizes is better than sex

**Table 4.** The area under the receiver operating characteristic (ROC) curve

	Area	SD	95% CI	P-value
Model 1	0.839	0.044	0.752-0.926	<0.001
Model 2	0.833	0.044	0.747-0.920	<0.001
Model 3	0.869	0.040	0.791-0.948	<0.001



**Figure 3.** ROC curve



prediction using right or left sizes.

## Discussion

So far, many studies have examined the dimorphic properties of the mandibular bone and its use in sex estimation in forensic medicine. Among the various parts of the mandibular bone, its ramus, especially the condyle, has received the most attention from researchers (9,10). The reason for this high attention to Ramos is almost predictable, because the phenomenon of growth and maturity, which is considered by some to be one of the most important initiators of sexual dimorphism, affects Ramos more than the trunk of the mandible, while the phenomenon of "ageing" mainly affects the radio morphometric properties of the bone trunk (11). In this study, we look at some of the radio morphometric properties of the mandibular bone for use in sexual identification. As reported, among the studied variables, the mediolateral dimension of the condylar process showed a significant difference between males and females and right and left, while in the study of Jose et al. there was no significant difference; It should be noted that Jose's study was on patients under 20 years of age.<sup>5</sup> Also, in the study of Rodriguer et al., No significant difference was observed between the right mediolateral dimension (20.62 mm) and the left (20.20 mm) (12).

In the present study, the mean anterior-posterior dimension on the right and left side, and between males and females, did not show a significant difference, similar to the study of Jose et al (13) (right side 9.39 & left side 9.30).<sup>12</sup> In our study, there was no statistically significant difference between the angles of the longitudinal axis of the condyle by gender, which was consistent with the results of Larry Wangai et al.<sup>6</sup> also, in the study of Rebell et al. there was no significant difference between left and right condyles in men, but there was a significant difference between left and right condyles in women.

The reason is probably related to epigenetic factors, social circumstances, and differences in eating habits. Other parameters that have been extensively studied by forensic researchers include the mandibular, the gonial, and the ante gonial angle. The dimorphic differences of the mandibular angle (the angle between the ramus and the mandibular trunk) have been considered for several years, and various issues related to inverting or being inverted between the two sexes have been proven (14,15), and the interesting point is that this is common in most races, but the differences in gonial and ante gonial angles are different in many races, and this necessitates the need for further studies in different races. In our study, the size of the ante gonial angle was higher in women than in men, but this difference was not statistically significant ( $p = 65\%$ ). In the study of Tafakhari et al. (8), the amount

of the above-mentioned angles in females was more than in males and the mentioned difference was statistically significant which was not in agreement with the results of our study. Perhaps the difference in results is due to the fact that we used CBCT instead of panoramic radiographs. However, in some studies on the Norwegian and Indian populations, this angle did not differ significantly between the sexes, though it was larger in men due to the effect of insertion of the masticatory muscle in the gonion region (16). In this study, the dimensions of the condylar longitudinal axis and the ante gonial angle in the right and left (regardless of gender) were statistically significant, while this difference was not significantly different for the other variables. It is not possible to make a definite statement about this observed difference, but it seems that the cause of this difference should be sought in the phenomenon of lateral dominance, or the so-called right-wing dominance or left-wing dominance because in the dominant side of the masticatory muscles of that side of the body is also more powerful and causes changes in the gonial angle or length of the condyle (due to temporomandibular joint movements) (17). In the present study, there was no statistically significant difference in vertical coronoid height, either on the right and left, or in general between men and women ( $p = 69\%$ ), which was not consistent with the study of Mouna subbaramaiah et al (In men on the right side  $37.0 \pm 49.1$ cm and on the left  $34.0 \pm 31.1$ cm and in women on the right  $29.0 \pm 51.1$ cm and on the left  $34.0 \pm 26.1$ cm), so they reported the height of the coronoid process as a useful indicator of sex determination.<sup>7</sup>

## Conclusion

According to our findings, the mean mediolateral dimension of the condyle was significantly larger in males than in females. By discriminant analysis, at least 70% of the original grouped cases were classified, correctly. Considering the area under the ROC curve and the obtained 95% CI, sex estimation based on the mean dimensions of left and right side is more accurate and reliable than sex estimation using just left or just right.

## Conflicts of interest: none

## References

1. Nema P, Nema P K, Dadu S k, Singh B K. Determination of sex from the width of s3 segment of sternum in the central India, indore region (MP). Indian Internet Journal of Forensic Medicine & Toxicology. 2018;16: 79-83.
2. Nagare S P, Chaudhari R S, Birangani R S, Parkarwar P C. Sex determination in forensic identification, a review. J Forensic Dent Sci. 2018;10: 61-66.
3. Punzalan D, Hosken D J. Sexual dimorphism; Why the sexes are (and are not) different. Curr Biol. 2010;20: R972-R973.

4. Pessa JE, Slice DE, Hanz KR, Broadbent Jr TH, Rohrich R J. Aging, and the shape of the mandible. *Plast Reconstr Surg*. 2008;121:196-200.
5. Valladares Neto J, Estrela C, Bueno MR, Guedes OA, Porto OCL, Pécora JD. Mandibular condyle dimensional changes in subjects from 3 to 20 years of age using CBCT: SA preliminary study. *Dental Press J Orthod*. 2010;15:172-181.
6. Wangai L, Mandela P, Butt F. Horizontal angle of inclination of the mandibular condyle in a Kenyan population. *Anatomy Journal of Africa*. 2012;1:46-49.
7. Subbaramaiah M, Jagannatha S. Size of the coronoid process and ramus as novel parameteres in determination of mandibular sex. *Indian Journal of Clinical Anatomy and Physiology*. 2018;5: 402-405.
8. Tafakhori Z, Mostafazadeh G, Fathollahi M S. A study on the association of mandible anatomy with age and gender in panoramic radiography of patients referred to Rafsanjan dental school clinic. *jdm*. 2017;29: 253-261.
9. Abbasi P, Ghodousi A, Ghafari R, Abbasi S. Comparison of accuracy of the maxillary sinus area and dimensions for sex estimation lateral cephalograms of Iranian samples. *Journal of Forensic and Radiology Imaging*. 2019; 17:18-22.
10. More CB, Vijayvargiya R, Saha N. Morphometric analysis of mandibular ramus for sex determination on digital orthopantomogram. *Journal of Forensic Dental Sciences*. 2017;9:1-5.
11. Ko AC, Korn BS, Kikkawa Do. The aging face. *Surv Ophthalmol*. 2017;62:190-202.
12. Rodrigues AF, Fraga MR, Vitral RWF. Computed tomography evaluation of the temporomandibular joint in class I malocclusion patients: condylar symmetry and condylefossa relationship. *Am J Orthod Dentofacial Orthop* 2019;136:192-198.
13. Crusoé-Rebello IM, Campos PS, Rubira IR, Panella J, Mendes CM. Evaluation of the relation between the horizontal condylar angle and the internal derangement of the TMJ - a magnetic resonance imaging study. *Pesqui Odontol Bras*. 2003;17:176-82.
14. Sharma M, Gorea RK, Gorea A, Abuderman A. A morphometric study of the human mandible in the Indian population for sex determination. *Egyptian Journal of Forensic Sciences*. 2016;6:165-169.
15. Albalawi AS, Alam MK, Vundavalli S, Ganji KK, Patil S. Mandible: An Indicator for Sex Determination - A Three-dimensional Cone-Beam Computed Tomography Study. *Contemp Clin Dent*. 2019;10:69-73
16. Apaydın B, Icoz D, Yasar F, Akgunlu F. Evaluation of mandibular anatomical formation for gender determination in Turkish population. *Balkan Journal of Dental Medicine*. 2018;22:133-137.
17. Brackmann MS, Padovan LEM, Marcantonio Junior E, Klüppel LE. Does the Length of Dental Implants Inserted in Areas of Inferior Alveolar Nerve Lateralization Interfere on Mandibular Resistance to Fracture? *J Craniofac Surg*. 2019;30: e293-e295