



Relationship between Radiographic bone analysis and Clinical Factors in Patients with Peri-implantitis

Kosar Kianfar¹, Mehdi Abrishami², Azadeh Torkzadeh^{3*}, Nasim Farkhani⁴, Vahid Pashaei⁵

Received: 2023-10-11 / Accepted: 2023-12-24 / First publication date: 2023-12-27

© The Author(s) 2023

Abstract

Background: Peri-implantitis is a reversible inflammation that can lead to crestal bone loss around the implant. Symptoms include radiographic bone loss, increased probing depth, bleeding on probing, and pus discharge. The aim of this study was to investigate the correlation between clinical factors and radiographic bone analysis in patients diagnosed with peri-implantitis.

Materials and Methods: This cross-sectional observational clinical study enrolled 38 patients with symptoms of peri-implantitis, referred to the private department and dental clinic of Isfahan Azad University. After obtaining informed consent, a periapical digital image was taken using a parallel technique to measure the amount of vertical bone resorption in millimetres around the implant. The amount of vertical bone resorption was divided into three categories: less than 1.5 mm, between 1.5 and 3 mm, and more than 3 mm. Then, the amount of bleeding, depth of probing, and presence of pus were assessed for each participant. Data were analysed using a t-test, ANOVA, and Pearson's correlation coefficient with a significance level of 0.05.

Results: There was a significant and direct difference between bleeding on probing and vertical bone resorption ($P<0.001$, $r=0.466$). There was also a significant and direct difference between probing depth and vertical bone analysis ($P=0.018$, $r=0.278$). The pus variable was negative for all participants.

Conclusion: This study found that bleeding on probing and depth of probing have a direct relationship with vertical bone resorption in patients with peri-implantitis and with the increase of radiographic bone resorption, depth of probing and bleeding on probing increases in patients.

Keywords: Bone Resorption; peri-implantitis; Radiography, Dental

Introduction

Dental implants have become a reliable method for replacing missing teeth in modern dentistry. They are known for their superior durability and success compared to other dental prostheses. However, despite their high success rate, peri-implantitis and mucositis are pathological conditions that can affect the long-

term health of dental implants. Unlike gum disease and periodontitis affecting natural teeth, these conditions affect the soft and hard tissues surrounding implants (1, 2).

The accumulation of microbial plaque is the primary factor in the pathogenesis of peri-implantitis (3). Peri-implantitis is characterized by swelling, redness, pus, pain, bleeding on probing, probing depth of more than 4 mm, radiolucency, and progressive bone loss around the implant. Bacterial biofilm activates both the innate and acquired immune system, leading to the production and secretion of inflammatory mediators. These mediators are protective but may ultimately cause tissue damage (4). In recent decades, there has been a significant amount of evidence regarding the occurrence of inflammation around dental implants. Implant failure can occur due to the impact of diseases

Corresponding author: Dr Azadeh Torkzadeh
Department of oral & maxillofacial radiology, Faculty of dentistry, Isfahan (Khorasgan) branch, Islamic Azad University, Isfahan, Iran
Email: azadehtorkzadeh@gmail.com

¹ School of Dentistry, Islamic Azad University, Isfahan (Khorasgan) Branch, Isfahan, Iran

² Department of oral & maxillofacial surgery, Faculty of dentistry, Isfahan (Khorasgan) branch, Islamic Azad University, Isfahan, Iran

³ Department of oral & maxillofacial radiology, Faculty of dentistry, Isfahan (Khorasgan) branch, Islamic Azad University, Isfahan, Iran

⁴ Department of periodontics, Faculty of dentistry, Isfahan (Khorasgan) branch, Islamic Azad University, Isfahan, Iran

⁵ Department of oral & maxillofacial surgery, Faculty of dentistry, Isfahan (Khorasgan) branch, Islamic Azad University, Isfahan, Iran

on the soft and hard tissues surrounding the implant. Therefore, preventing and treating implant-related diseases should be a critical aspect of implant dentistry (5). Several parameters have been introduced to aid in the clinical diagnosis of peri-implantitis. The most used parameters are radiographic bone resorption, probing depth, bleeding on probing, and pus formation. Periapical radiography can determine bone changes and the progress of the disease around the implant. A successful implant should be immobile, without radiolucency around the implant, with bone loss less than 0.2 mm in one year after the first loading, and without pain, discomfort, or persistent infection (6, 7).

The main factor in bleeding probing is inflammation of the connective tissue of the sulcus wall or periodontal pocket, although other factors besides gingivitis can lead to bleeding on probing. Understanding the factors that can affect BOP (bleeding on probing) is important as it is a symptom of gingivitis and disease activity in clinical evaluations and research (8).

Various studies have reported a 5% to 63.4% prevalence for peri-implantitis (9). This wide range for the prevalence of peri-implantitis may be due to differences in study design and sample size. However, a recent study by Mombelli et al. (10) showed that peri-implant diseases are prevalent in 20% of all patients with implants and 10% of all loaded implants. In a study by Nasiri et al. (11), the prevalence of peri-implantitis was 17% one year after prosthetic loading in the studied participants, and an estimated 9.3% for every replaced implant. A study by Hashim et al. reported that for implants with positive bleeding on probing, there was a 24.1% chance of being diagnosed with peri-implantitis. For patients with positive probing bleeding, there was a 33.8% chance of being diagnosed with peri-implantitis (12).

Considering the widespread use of implants in contemporary dentistry, the high prevalence of diseases around implants, and the lack of evidence and studies in Iran in the field of diagnosing peri-implantitis, this study aimed to investigate the relationship between radiographic bone analysis and clinical factors in patients with peri-implantitis.

Materials and Methods

In this cross-sectional observational study, 38 patients (19 men and 19 women aged between 18 and 60) referring to the private department and dental clinic of Azad University of Isfahan were examined for

symptoms of peri-implantitis (13). These patients had probing depth (PD) of more than 4mm, maximum bone loss to the second thread, and signs of inflammation in the soft tissues. Non-cooperative patients and patients with certain conditions including guided bone regeneration patients (GBR: Guided Bone Regeneration), immediate implant patients (fresh socket), improper implant placement, patients taking drugs affecting bone resorption like Bisphosphonate and Cortone, patients with systemic diseases affecting bone resorption such as diabetes and severe arthritis, patients with a history of smoking, patients with veneer and restoration problems, pregnant women, patients with periodontitis, and patients with severe malocclusion were excluded from the study.

After obtaining informed consent from the patients, digital periapical radiographs were taken using intraoral sensor number 2 with parallel technique (dental x-ray phosphor plate scanner soredeX optime). The amount of bone loss in millimetres based on the connection location of the abutment and the implant fixture was checked using a computerized measurement system (Scanora software, version 3) (Figure 1). Based on the amount of vertical bone loss, the implant was divided into three categories: vertical bone loss less than 1.5 mm, between 1.5 and 3 mm, and more than 3 mm.

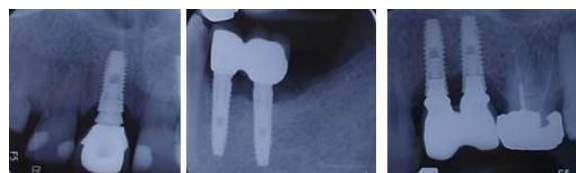

Figure 1. Parallel digital periapical image of a patient with symptoms of peri-implantitis showing bone resorption

This study used the Bleeding Sulcus Index to measure the amount of bleeding. The index classified bleeding into three categories: no bleeding (-), bleeding after 30 to 60 seconds after probing (+), and bleeding immediately after probing (++). Pus formation was measured by applying pressure with an index finger and moving it from the root to the tooth crown. Upon isolation and desiccation of the area surrounding the implant, the quantity of exudate was expressed as negative (-), minor positive (+), or prominent positive (++) per established standards (14). The probing depth was measured using apical penetration of the Williams periodontal probe (Joya Electronics Co., Tehran, Iran) with mild force and low tissue resistance measuring the depth of the pocket on all surfaces around

the implant in six levels, including mesiobuccal, mid-buccal, distobuccal, mesiolingual, mediolingual and distolingual (15). For implants with peri-implantitis, the surface with the deepest pocket was noted and sampled. Pearson and Spearman correlation coefficients, t-test, and ANOVA in SPSS software version 24 were used to analyse data ($\alpha=0.05$).

Results

Figure 2 shows the mean bleeding on probing, probing depth and mean vertical bone resorption in the studied patients. The mean bleeding on probing was 26.4% (-), 33.3% (+), and 40.3% (++) and the average depth of probing was 1.97 (-), (+) 2.38, and (++) was equal to 3.15. The mean vertical bone loss was (-) equal to 1.82, (+) equal to 1.64, and (++) equal to 2.58 (Figure 2).

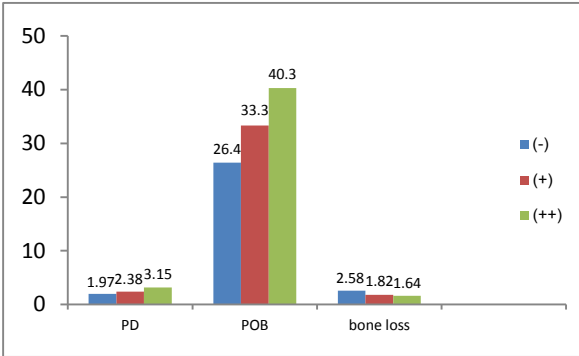


Figure 2. Frequency distribution of BOP, PD, and bone loss

After examining bone resorption based on the depth of probing, it was found that there was no significant difference in depth of probing in peri-implantitis patients with vertical bone resorption who had less than 1.5 mm ($p = 0.808$, $r = -0.054$), between 1.5 to 3 mm ($p = 0.916$, $r = 0.018$) and more than 3 mm ($p = 0.410$, $r = -0.277$). The results of ANOVA test showed a significant relationship between the presence of BOP and the occurrence of bone loss ($P<0.001$), but no correlation between the amount of BOP and the amount of bone loss was found ($r = 0.466$). The results of Tukey's Post hoc test showed a significant difference between the mean of (-) and (++) groups ($P < 0.001$), as well as (+) and (++) ($P < 0.001$) (table 1), but no significant difference was observed between (-) and (+) groups ($P = 0.742$) (Table 1).

Table1. Mean vertical bone loss based on bleeding on probing

Bone loss	NO	Mean \pm SD	P value
-	19	1.82 \pm 0.82	< 0.001
+	24	1.64 \pm 0.54	
++	29	2.65 \pm 0.86	

(-) no bleeding
(+) bleeding after 30 to 60 seconds after probing
(++) bleeding immediately after probing

In examining the relationship between bone resorption and probing depth, the results of Pearson's correlation test showed a direct and significant relationship as with the increase of one of these two variables, the other one also increased ($p=0.018$, $r=0.278$) (Table 2).

Table 2. Relation between Probing depth in peri-implantitis patients with bone resorption

Variable	No	Correlation rate	P value
PD	72	0.278	0.018

Discussion

Results of this study showed bone loss was directly related to the amount of bleeding on probing and probing depth, which was in accordance with the results of previous studies (15, 16). In patients with peri-implantitis, clinical signs of inflammation such as bleeding on probing, pus, increased probing depth, or reduced margins in addition to radiographic bone loss of more than 2 mm are demonstrated (1, 15). In a study performed by French et al. (16), low bleeding was not related to bone loss and vertical bone resorption, while heavy bleeding was related to the amount of pus and probing depth and vertical bone resorption.

In the study of Berglundh et al. (17), bleeding on probing had a direct and significant relationship with vertical bone loss, but probing depth alone was not an effective factor in the occurrence of bleeding on probing.

The study of Coli et al. (18) found that the increase in probing pocket depth values and bleeding on probing over time was not necessarily related to the loss of supporting bone around dental implants. In the study of Coli et al. (18), the increase in probing pocket depth values and bleeding on probing over time was not necessarily related to the loss of supporting bone around dental implants, which is contrary to the results of the present study, since the healthy mucosa around the implant may bleed during probing and show a probing depth greater than 4 mm, thus leading to a large number of false clinical signs that may be misdiagnosed as peri-implantitis and possibly lead to overtreatment of possible bio-mediated peri-implantitis lesion which can be the reason for the difference in the results of the two studies.

Previous studies have shown that bleeding on probing can be a sign of peri-implantitis (11, 14, 19). However, in Hashim et al.'s study (12), it was observed that there can be close similarities between bleeding on probing and false positives. Therefore, dentists should be aware of the possibility of false positives when diagnosing peri-implantitis using Bop. The most

important factor in the pathogenesis of peri-implantitis is the accumulation of microbial plaque, which is characterized by edema, erythema, pus formation, pain, probing depth of more than 4 mm, bleeding on probing, radiolucency around the implant, and progressive bone loss (3, 4). In the present study, no cases of pus were observed in the investigated patients, which is contrary to the results of other studies (1, 15).

Bleeding on probing is a parameter used to diagnose peri-implant mucositis and peri-implantitis. It is believed that healthy implants should not show any bleeding on probing whereas diseased implants may exhibit bleeding. However, there are conflicting results regarding the relationship between bleeding on probing and peri-implantitis. Some studies suggest that bleeding on probing is a cause of peri-implantitis, while others have found no relationship between bleeding on probing and healthy implants (17, 20-22). Saminsky et al. (23) found that the type of implant affects the amount of bleeding on probing and vertical bone analysis. External Hex implants placed without guided bone regeneration and implants 10 to 12 mm long and 3.7 to 4 mm in diameter show less bone loss. Smokers and osteoporosis patients are more prone to increased bone loss (23).

In the study performed by Hashim et al. (12), it was revealed that implants with positive bleeding on probing had a 24.1% chance of peri-implantitis. Even though, in patients with positive bleeding on probing, there was a 33.8% probability of peri-implantitis. Accordingly, they concluded clinicians should be aware of the considerable false-positive rate of BOP for diagnosing peri-implantitis.

In a study conducted by Gerber et al. (24), researchers assessed the bleeding on probing (BOP) tendency and periodontal probe penetration when applying various probing forces at implant sites in patients with a high standard of oral hygiene, well-maintained peri-implant tissues, and no evidence of periodontitis or gingivitis. The study discovered that excessive force during probing could lead to false BOP readings around oral implants. Therefore, caution should be exercised to avoid this. Probing around implants was also found to be more sensitive compared to probing around teeth. However, it is also noteworthy that microbial plaque accumulation cannot be disregarded as a potential contributor to bleeding on probing, radiolucency around the implant, and progressive bone loss. Interestingly, the current study revealed that the depth of probing did not strongly correlate with the amount of bleeding on probing, indicating that other factors

may also play a role in the occurrence of bleeding on probing.

Conclusion

The study found bleeding on probing and probing depth are related to vertical bone resorption in patients with peri-implantitis, and with the increase of radiographic bone resorption, probing depth and probing bleeding increase in patients.

References

1. Derks J, Schaller D, Håkansson J, Wennström J, Tomasi C, Berglundh T. Effectiveness of implant therapy analyzed in a Swedish population: prevalence of peri-implantitis. *J Dent Res*. 2016;95(1):43-9.
2. Okayasu K, Wang HL. Decision tree for the management of peri-implant diseases. *Implant Dent*. 2011;20(4):256-61.
3. Resnik RR, Misch CE. Contemporary implant dentistry. 4th ed. St. Louis: Elsevier, 2021. P:577
4. The American Academy of Periodontology. Peri-implant mucositis and peri-implantitis: a current understanding of their diagnoses and clinical implications. *J Periodontol* 2013; 84(4):436-43.
5. Derks J, Tomasi C. Peri-implant health, and disease. A systematic review of current epidemiology. *J Clin Periodontol*. 2015;42:S158-S71.
6. Lin GH, Kapila Y, Wang HL. Parameters to define peri-implantitis: A review and a proposed multi-domain scale. *J Oral Implantol*. 2017;43(6):491-6.
7. Louropoulou A, van der Weijden F. De richtlijnen voor parodontale en peri-implantaire ontstekingen [The Dutch guidelines for prevention and treatment of periodontal and peri-implant diseases]. *Ned Tijdschr Tandheelkd*. 2021;128(12):585-592
8. Newbrun E. Indices to measure gingival bleeding. *J Periodontol* 1996; 67: 555-561.
9. Smeets R, Henningsen A, Jung O, Heiland M, Hammächer C, Stein JM. Definition, etiology, prevention, and treatment of peri-implantitis--a review. *Head Face Med*. 2014;10:34.
10. Mombelli A, Müller N, Cionca N. The epidemiology of peri-implantitis. *Clin Oral Implants Res*. 2012;23 Suppl 6:67-76.
11. Nasiri S, Rafiei F, Darabian S. Determining the prevalence of peri-implantitis in patients one year after prosthetic loading in Khorramabad in 2021. *J Dent Med-TUMS*. 2021;34:21.
12. Hashim D, Cionca N, Combescure C, Mombelli A. The diagnosis of peri-implantitis: A systematic review on the predictive value of bleeding on probing. *Clinical oral implants research*. 2018;29:276-93
13. Farhad SZ, Rezazadeh F, Mohammadi M. Interleukin -17 and Interleukin-10 as Inflammatory and Prevention Biomarkers in Periimplant Diseases. *Int J Prev Med*. 2019 Aug 12;10:137

14. Esfahanian V, Farhad ShZ, Bakhtiari M, Feyzollahi Almaloo M. Comparison of Interleukin 23 Level in Gingival Crevicular Fluid between Peri-implantitis and Healthy Patients. *J Mash Dent Sch* 2018; 42(2): 115-20.
15. Sanz M, Chapple IL; Working Group 4 of the VIII European Workshop on Periodontology. Clinical research on peri-implant diseases: consensus report of Working Group 4. *J Clin Periodontol*. 2012;39 Suppl 12:202-6.
16. French D, Cochran DL, Ofec R. Retrospective Cohort Study of 4,591 Straumann Implants Placed in 2,060 Patients in Private Practice with up to 10-Year Follow-up: The Relationship Between Crestal Bone Level and Soft Tissue Condition. *Int J Oral Maxillofac Implants*. 2016;31(6): e168-e178.
17. Berglundh T, Armitage G, Araujo MG, Avila-Ortiz G, Blanco J, Camargo PM, et al. Peri-implant iseases, and conditions: Consensus report of workgroup 4 of the 2017 World Workshop on the Classification of Periodontal and Peri-Implant Diseases and Conditions. *J Clin Periodontol*. 2018;45 Suppl 20:S286-S291
18. Coli P, Christiaens V, Sennerby L, Bruyn H. Reliability of periodontal diagnostic tools for monitoring peri-implant health and disease. *Periodontol* 2000. 2017;73(1):203-217
19. Nettemu SK, Nettem S, Singh VP, William SS, Gunasekaran SS, Krisnan M, et al. Multilevel analysis of site, implant, and patient-level factors with peri-implant bleeding on probing: a cross sectional study. *Int J Implant Dent*. 2021;7(1):77.
20. Ericsson I, Lindhe J. Probing depth at implants and teeth. An experimental study in the dog. *J Clin Periodontol*. 1993;20(9):623-7.
21. Lang NP, Wetzel AC, Stich H, Caffesse RG. Histologic probe penetration in healthy and inflamed peri-implant tissues. *Clin Oral Implants Res*. 1994;5(4):191-201.
22. Emecen-Huja P, Eubank TD, Shapiro V, Yildiz V, Tatakis DN, Leblebicioglu B. Peri-implant versus periodontal wound healing. *J Clin Periodontol*. 2013;40(8):816-24.
23. Saminsky M, Ben Dor A, Horwitz J. Variables Affecting Peri-Implant Radiographic Bone Loss-8-23 Years Follow-Up. *Applied Sciences*. 2020;10(23):8591.
24. Gerber JA, Tan WC, Balmer TE, Salvi GE, Lang NP. Bleeding on probing and pocket probing depth in relation to probing pressure and mucosal health around oral implants. *Clin Oral Implants Res*. 2009;20(1):75-8.