



Investigating mandibular anterior teeth root canal configuration diversity using Cone-Beam Computed Tomography

Hamid Ghasemi¹, Maryam Zare Jahormi^{2*}, Azadeh Torkzadeh³, Amirreza Mokabberi⁴

Received: 2023-12-07 / Accepted: 2024-03-12 / First publication date: 2024-07-31

© The Author(s) 2024

Abstract

Background: Errors that occur during root canal treatment can be caused by lack of information about the anatomical conditions of the root canal system. The purpose of this study was to examine the root and canals morphology of mandibular anterior teeth using cone-beam computed tomography (CBCT).

Materials & Methods: In this descriptive analytical study, 165 CBCT images of mandibular anterior teeth of patients from 15 to 60 years in the archives from oral & maxillofacial radiology department in 2015-2021 were used. CBCT images were examined in three axial, sagittal and coronal sections and the information of each tooth were recorded in pre-prepared forms. The data were analysed by Chi-square and Fisher exact test ($\alpha=0.05$).

Results: All mandibular central teeth were single-rooted, of which 59.7% were single canal and 40.3% were double-canal. 99.4% of the mandibular lateral teeth were single-rooted and 0.6% of the teeth were double-rooted. 62.8% of single-rooted laterals had a single-canal where 37.2% had double-canals. 97.6% of canine teeth were single-rooted and 2.4% of teeth were double-rooted. In single-rooted teeth, 95.3% had a single-canal. In mandibular single-rooted anterior teeth with two canals, Vertucci type III was the most common configuration. The frequency distribution of the variation of mandibular central and lateral teeth canals between women and men were not statistically significant, while in single-rooted canines significant differences were observed ($p=0.031$).

Conclusion: Anterior teeth with two roots was not common. It was more prevalent in canines, laterals and central teeth. The prevalence of single-rooted mandibular teeth with two canals was mostly seen in central, lateral, and canine teeth.

Key words: Root canal; Cone-Beam Computed Tomography; Anatomy

Introduction

Cleaning, shaping and three-dimensional filling of the root canal system is important in endodontic treatment (1). Knowledge about the anatomy of the root canal system is crucial because most of errors that occur during root canal treatment are related to lack of observation of canal anatomy and an untreated canal may lead to treatment failure (2, 3). Weine et al. (4)

classified tooth canal into four types depending on the pattern of dividing the main root canal along its path from the floor of the pulp chamber to the apex of the root. Vertucci (5) also categorized the shape of the root canal in a more descriptive way into eight types. Many researchers use this classification widely in studying the root canal system.

There are several methods for determining the anatomy of the root canal system, including preparation of an access hole and taking radiography while the file is in the root canal system. Other methods include root canal staining and tooth cleaning, conventional and digital radiography, cone beam computed tomography, sectioning, and microscopic evaluation (6, 7). Conventional periapical radiography provides a two-dimensional image from three-dimensional anatomy, and this causes overlap of

Corresponding author: Maryam Zare Jahormi
Department of Endodontics, Faculty of Dentistry, Islamic Azad University, Isfahan (Khorasgan) Branch, Isfahan, Iran
Email: m.zare@khuif.ac.ir

¹Faculty of Dentistry, Islamic Azad University, Isfahan (Khorasgan) Branch, Isfahan, Iran

²Department of Endodontics, Faculty of Dentistry, Islamic Azad University, Isfahan (Khorasgan) Branch, Isfahan, Iran

³Department of Oral and Maxillofacial Radiology, Faculty of Dentistry, Islamic Azad University, Isfahan (Khorasgan) Branch, Isfahan, Iran

⁴Department of Endodontics, Faculty of Dentistry, Islamic Azad University, Isfahan (Khorasgan) Branch, Isfahan, Iran

buccolingual surfaces. Therefore, the differences in root canals system cannot be determined without 3D images (8).

Cone beam computed tomography (CBCT) is a non-invasive method that potentially provides 3D diagnostic images without any overlap of tooth structures. The shape and number of the root canals, along with their divergence or convergence from each other can be seen in 3D images (9).

One of the most important reasons for root canal treatment failure in mandibular incisor teeth is failing to treat the second canals. According to previous studies, the most mandibular incisor teeth show Vertucci type I and II root canal anatomy. While Vertucci type IV is rare in these teeth. This condition is seen in 3%, 2% and 6% of mandibular centrals, laterals canines, respectively (5, 10).

Zhao et al. (11) showed that double root canals are most common in mandibular incisors and Vertucci type III canal configurations are the most frequent type in mandibular anterior teeth. Haghanifar et al. (12) revealed that, 87.9% of teeth had one root and 0.3% of canines had two roots. According to Vertucci's classification, type I (88.2%), type III (8.1%), type II (3.3%), type V (0.3%), and type VI (0.1%) were the most prevalent configuration. In the study of Saati et al (3), all mandibular central and lateral incisor teeth had one root, in which, 84.5% of mandibular central incisor teeth and 78.2% of all mandibular lateral incisor teeth had one canal. Pan et al (13), showed that the prevalence of two canals in mandible was observed in 5.1% of central incisors, 12.3% of lateral incisors and 6.1% of canine teeth.

Accordingly, as root canal treatment of mandibular anterior teeth is sometimes difficult due to the morphological differences that can be seen in the shape and number of the roots and canals the aim of present study was to evaluate the morphological and anatomical diversity of the root canals of mandibular anterior teeth in a group of people from Esfahan, Iran by using CBCT.

Materials & Methods

This descriptive analytical study recruited 165 randomly selected CBCT images of mandibular anterior teeth that were selected from patients 15 to 60 years old (62% female, 28% male) referred to the oral and maxillofacial radiology center of Faculty of Dentistry, Azad University of Isfahan (Khorasgan)

during 2015-2021. Ethically this study was approved by the ethical code 1399.27.

These images were taken for other diagnostic and therapeutic purposes. It should be noted that, all CBCT images were acquired by using Galileos-Sirona (Bensheim, Germany) with a field of view 13×15 cm (operational parameters: 90 kV, 5 mA, 8.14 s, 0.38 mm voxel size). CBCT images were studied on SIDEXIS 3D software (Fabrikstr 31, Bensheim, Germany) on a computer monitor under standard conditions (semi-dark room with constant light intensity) to view the images in the axial, sagittal, and coronal planes with a slice thickness of one mm to determine the number of roots and root canals (regarding the presence or absence of the second canal) and the type of canals according to Vertucci classification (5). The inclusion criteria of the study were the images with optimal quality without motion or foreign object artifacts, in which the apex of the teeth were complete and had not undergone root canal treatment. Also, they did not have developmental growth problems, latency, calcification and internal resorption.

To reduce the potential biases, the CBCT stereotypes were randomly observed by two researchers separately (oral & maxillofacial radiologist and endodontist) in two period with the interval of two week and data were recorded and analysed by Chi-square and Fisher exact tests in SPSS software version 22 at a significance level of 0.05.

Results

Among the 165 patients included in this study, 102 (61.8%) were women and 63 (28.2%) were men. In the CBCT images of the mandible (right and left side) of each patient, two mandibular central teeth (330 teeth in total), two mandibular lateral teeth (330 teeth in total) and two mandibular canines (330 teeth in total) were examined. Figure 1 shows the frequency distribution of roots and canals of mandibular anterior teeth. As can be seen, all central teeth in this study were single-rooted, in which 59.7% single canal and 40.3% double canal. In mandibular lateral teeth, 99.4% teeth were single-rooted that 62.8% single canal and 37.2% double canal. Also, 0.6% of teeth were double rooted with double canal. In mandibular canine, 97.6% teeth were single-rooted, in which 95.3% single canal and 4.7% double canal. Besides, 2.4% teeth were double rooted with double canal.

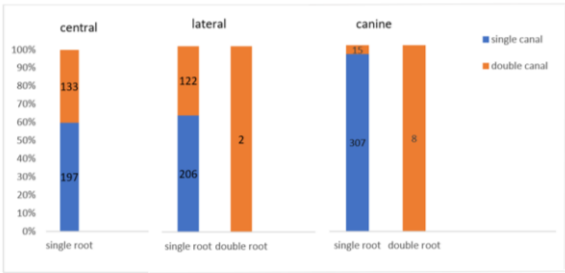


Figure 1. Frequency distribution of roots and canals of mandibular anterior teeth (n=330).

Regarding to the results presented in Table 1 by Fisher exact test, the frequency distribution of the variation of the mandibular central teeth canals between women and men were not statistically significant ($p=0.857$). A similar result was obtained for the lateral teeth that the frequency distribution of canal shape of single-rooted lateral teeth (single-canal and double-canal) between women and men was not statistically significant ($p=0.393$). There was a significant difference in the distribution of the shape of the canals of mandibular single-rooted canine teeth between men and women ($p=0.031$).

Table 1. Frequency distribution of the number of roots and canals of anterior teeth according to gender of patients (n=330).

Mandibular anterior tooth type	Number of roots	number of canals	Gender of patients		P value
			Female	Male	
central	Single root	Single canal	121 (61.4)	76 (38.6)	0.857
		Double canal	83 (62.4)	50 (37.6)	
Lateral	Single root	Single canal	131 (63.6)	75 (36.4)	0.393
		Double canal	71 (58.2)	51 (41.8)	
	Double root	Double canal	2 (100.0)	0	-
Canine	Single root	Single canal	187 (60.9)	120 (39.1)	0.031
		Double canal	13 (86.7)	2 (13.3)	
	Double root	Double canal	4 (50.0)	4 (50.0)	-

By Chi-squared test, the results of Table 2 show that, in all mandibular anterior teeth with single root, there were not statistically significant differences were seen in the distribution of the frequency of the anatomical

variation of the canals according to the Vertucci classification between men and women. There were no significant value was more than 5% for all three types of teeth.

Table 2. Frequency distribution of canal morphology of mandibular anterior teeth based on Vertucci's classification by gender of patients (n=330).

Mandibular anterior tooth type	Number of roots	Number of canals	Vertucci's classification	Gender of patients		P value
				Female	Male	
central	Single root	Single canal	type I	121 (61.4)	76 (38.6)	0.289
			type II	2 (100.0)	0	
		Double canal	type III	79 (61.2)	50 (38.8)	
			type V	2 (100.0)	0	
			type V	2 (100.0)	0	
lateral	Single root	Single canal	type I	131 (63.6)	75(36.4)	0.139
		Double canal	type III	69 (57.5)	51 (42.5)	
			type V	2 (100.0)	0	
			type V	2 (100.0)	0	
	Double root	Double canal	type I	2 (100.0)	0	-
canine	Single root	Single canal	type I	187 (60.9)	120 (39.1)	0.865
		Double canal	type II	1 (100.0)	0	
			type III	11(84.6)	2 (15.4)	
			type V	1 (100.0)	0	
	Double root	Double canal	type I	4(50.0)	4 (50.0)	-

Discussion

Knowledge of teeth anatomy and their diversity are essential for successful of root canal treatment. Anatomy and morphology of teeth are influenced by various factors such as genetics, which have caused anatomical variations among different populations.

Also, different methods are used to verify the anatomy of root canal system. None of the commonly applied methods for determination of internal root canal anatomy such as colouring of canals and clearing technique, conventional radiography, computed tomography can serve as the gold standard for this

purpose because of their characteristic limitations. CBCT method has many advantages, including the ability to compare with common methods and enable to examine adjacent structure and it is possible to accurately identify the anatomy of the tooth (14-17).

To avoid any potential bias, all CBCT images were assessed by oral & maxillofacial radiologist and in the next step, the CBCT stereotype were observed and confirmed by endodontist.

According to the results of the present study, the probability of having two roots in the anterior teeth of mandible is not high. Also, the prevalence of single-rooted and double-canal teeth in mandible, from most to least includes central, lateral and canine.

In Saati et al. (3) investigation all mandibular central and lateral incisor teeth had one root. Also, 84.5% of the mandibular central incisors and 78.2% of the lateral incisor's teeth had one canal. The prevalence of Vertucci types, from most to least, in mandibular central and lateral teeth with two-canal included: type III and type V and the type II and IV were not observed. In our survey, like the Saati et al study (3), Vertucci type III was the most common type in the mandibular central and lateral teeth with two canals. Despite of this study, our investigation shows 0.6 lateral mandibular teeth were two-rooted with Vertucci type I in all cases. It seems that genetic differences can play an important role in this diversity. In the present study, the frequency of single-rooted mandibular incisor (single-canal and double-canal) was higher in females, but this was not statistically significant, Mirhosseini et al. (18) showed, the frequency of mandibular incisor with single root and two canals in men was significantly higher than women.

In the present study, despite the higher frequency of all Vertucci types (I, II, III, V) in mandibular incisor teeth in female patients, the distribution of the frequency of Vartucci types among central and lateral mandibular teeth statistically did not show a significant difference among males and females.

Meanwhile, in the study of Saati et al. (3) the frequency of all Vertucci types observed in the mandibular central teeth (including: type I, III, V) and in mandibular lateral teeth (including: type I and V) were higher in females. Interestingly, in mandibular lateral teeth, the frequency of type III was higher in males

In the study of Doumani et al. (19) which assessed the morphology of mandibular canine, 97.85% of the teeth had single root, while 2.15% of the teeth had two roots.

In single-rooted and double-canal canine teeth, the prevalence of Vertucci types, from most to least, included: type III, type II, and type V which is consistent with the results of the present study.

Candeiro et al. (20) concluded in their study that all mandibular central and lateral incisors were single-rooted, whilst 2.4% of mandibular canines were double rooted. Also, in their research, about 20% of incisors and about 11% of mandibular canines had two canals. The highest prevalence of Vertucci type in these teeth were type I and type III, respectively. In this investigation, mandibular lateral and canine teeth showed no relation to gender whilst in the mandibular central; the prevalence of double canal teeth was higher in male patients.

In research conducted by Pan et al. (13) in the Malaysian population on mandibular anterior teeth, all central and lateral mandibular teeth were single-rooted and 98.8% of mandibular canine teeth were single-rooted, while 1.2% of mandibular canines had two roots. Also, in this study 1.5% of central, 12.3% of lateral incisors and 1.6% of canine teeth had double canals. The order of prevalence of Vertucci type of canals, from most to least, was as follows:

Mandibular central with two canals: type V, type III.

Mandibular lateral with two canals: type V, type III and type IV.

Mandibular canine with two canals: All teeth were type II.

The results of the present study and other research conducted regarding the anatomical variation of the teeth showed that single rooted mandibular anterior teeth with two canals the variation of Vertucci type III, was more common than other types. Also, the study showed that mandibular canines with single root and single canal in 60.9% and 39.1% were seen in females and males respectively. 86.7% and 13.3% mandibular canines having a single root with two canals were seen in females and males, respectively. In other words, the prevalence of single-root canine teeth (single-canal and double-canal) was higher in females and this difference was confirmed statistically.

According to the study of Doumani et al. (19) the prevalence of single-rooted canine teeth was higher in women The present study demonstrates, in double-rooted canines with two canals, 50% of the teeth belonged to women while in the study of Doumani et al. (19) 88.9% of double-rooted teeth were seen in women and none of the differences between gender and the number of roots were statistically significant.

Moreover, in our study the frequency distribution of all Vertucci types of canals of mandibular canine (including Type I, II, III, V) was higher in women but this difference was not statistically significant. In the study of Doumani et al. (19) the frequency of all Vertucci types observed in single-rooted mandibular canine teeth (including: types I, II, III, V) was higher in women, although this difference was not statistically significant (19).

Understanding the anatomical variation of the tooth is essential in the success of treatment. Sometimes root canal treatment of mandibular anterior teeth is difficult due to anatomical variations in shape and number of canals. Therefore, the treatment of these conditions needs special consideration. For instance, to find next canal, the clinician should modify access cavity and use magnification like endodontic microscope which is helpful in facilitating the access cavity preparation, location, and negotiation of the root canal system.

It should be mentioned that one of the main limitations of this study was providing appropriate CBCT stereotypes according to the inclusion criteria of the study. To have a better understanding of root canal anatomy similar research with a larger sample size and from various races is recommended.

Conclusion

The highest prevalence of Vertucci type in single-rooted and single-canal mandibular anterior teeth was type I, and in single-rooted and double-canal mandibular anterior teeth was type III.

The results of the present study in Esfahan advice seeking for the second canal in the mandibular anterior teeth, especially the mandibular incisors, and to pay more attention to Vertucci type III in these teeth.

Conflict of Interests: The authors of this manuscript declare that they have no conflicts of interest, real or perceived, financial or non-financial in this article.

References

- Shakouie S, Mokhtari H, Ghasemi N, Gholizadeh S. Two-rooted maxillary first molars with two canals: a case series. *Iran Endod J.* 2013;8(1):29–32.
- Perlea P, Nistor CC, Toma C, Dimitriu B. Endodontic configuration of the lower incisors in a Romanian population: a radiological study. *Rom J Morphol Embryol.* 2013;54:775–8.
- Saati S, Shokri A, Foroozandeh M, Poorolajal J, Mosleh N. Root morphology and number of canals in mandibular central and lateral incisors using cone beam computed tomography. *Braz Dent J.* 2018;29:239–44.
- Weine FS, Healey HJ, Gerstein H, Evanson L. Canal configuration in the mesiobuccal root of the maxillary first molar and its endodontic significance. *Oral Surg Oral Med Oral Pathol.* 1969;28:419–25.
- Vertucci FJ. Root canal anatomy of the human permanent teeth. *Oral Surg Oral Med Oral Pathol.* 1984; 58:589–99.
- Martos J, Lubian C, Silveira LF, de Castro LA, Luque CM. Morphologic analysis of the root apex in human teeth. *Journal of Endodontics.* 2010;36(4):664–7.
- Neelakantan P, Subbarao C, Subbarao CV. Comparative evaluation of modified canal staining and clearing technique, cone-beam computed tomography, peripheral quantitative computed tomography, spiral computed tomography, and plain and contrast medium-enhanced digital radiography in studying root canal morphology. *J Endod.* 2010;36(9):1547–51.
- Patel S, Dawood A, Ford TP, Whaites E. The potential applications of cone beam computed tomography in the management of endodontic problems. *Int Endod J.* 2007;40:818–30.
- Tian YY, Guo B, Zhang R, Yu X, Wang H, Hu T, et al. Root and canal morphology of maxillary first premolars in a Chinese subpopulation evaluated using cone-beam computed tomography. *Int Endod J.* 2012;45:996–1003.
- Tiku AM, Kalaskar RR, Damle SG. An unusual presentation of all the mandibular anterior teeth with two root canals — A case report. *J Indian Soc Pedod Prev Dent.* 2005;23:204–6.
- Zhao Y, Dong Y, Wang X, Wang Z, Li G, Liu M, et al. Cone-beam computed tomography analysis of root canal configuration of 4674 mandibular anterior teeth. *Beijing Da Xue Xue Bao Yi Xue Ban.* 2014;46(1):95–9.
- Haghanifar S, Moudi E, Bijani A, Ghanbarabadi MK. Morphologic assessment of mandibular anterior teeth root canal using CBCT. *Acta Med Acad.* 2017;46:85–93.
- Pan JYY, Parolia A, Chuah SR, Bhatia S, Mutalik S, Pau A. Root canal morphology of permanent teeth in a Malaysian subpopulation using cone-beam computed tomography. *BMC Oral Health.* 2019;19(1):14.
- Dalili Kajan Z, Taramsari M, Khosravi Fard N, Kanani M. Accuracy of Cone-beam Computed Tomography in Comparison with Standard Method in Evaluating Root Canal Morphology: An *In Vitro* Study. *Iran Endod J.* 2018;13(2):181–187.
- Lo Giudice R, Nicita F, Puleio F, Alibrandi A, Cervino G, Lizio AS, Pantaleo G. Accuracy of Periapical Radiography and CBCT in Endodontic Evaluation. *Int J Dent.* 2018;2018:2514243.

16. Borges CC, Estrela C, Decurcio DA, PÉcora JD, Sousa-Neto MD, Rossi-Fedele G. Cone-beam and micro-computed tomography for the assessment of root canal morphology: a systematic review. *Braz Oral Res.* 2020;34:e056.
17. Aung NM, Myint KK. Diagnostic Accuracy of CBCT for Detection of Second Canal of Permanent Teeth: A Systematic Review and Meta-Analysis. *Int J Dent.* 2021;2021:1107471.
18. Mirhosseini F, Tabrizizadeh M, Nateghi N, Shafiei Rad E, Derafshi A, Ahmadi B, et al. Evaluation of Root Canal Anatomy in Mandibular Incisors Using CBCT Imaging Technique in an Iranian Population. *J Dent (Shiraz).* 2019;20(1):24-29.
19. Doumani M, Habib A, Alhalak AB, Al-Nahlawi TF, Al Hussain F, Alanazi SM. Root canal morphology of mandibular canines in the Syrian population: A CBCT Assessment. *J Family Med Prim Care.* 2020;9(2):552-555
20. Candeiro GT, Teixeira IM, Barbosa DA, Vivacqua-Gomes N, Alves FR. Vertucci's root canal configuration of 14,413 mandibular anterior teeth in a Brazilian population: a prevalence study using cone-beam computed tomography. *J Endod.* 2021;47(3):404-8.