



Possible Role of Palatal Rugae Patterns for Sex Estimation in Forensic Dentistry: A Cross-Sectional Observational Study

Mohsen Karimi¹, Arash Ghodousi², Mohammad Javad Saeedi-Borujeni^{2, 3*}

Received: 2023-12-30 / Accepted: 2024-03-20 / First publication date: 2024-07-31

© The Author(s) 2024

Abstract

Background: Recently, rugoscopy has attracted much attention in forensic science. The purpose of the present study was to investigate the sex differences in morphological structure and number of hard palates rugae.

Materials and Methods: In this cross-sectional observational study, 100 female and male students were enrolled based on inclusion criteria. To investigate the number and shape of palate rugae impressions were provided using hydrocolloid materials. Then impressions were sharpened using a graphical pencil and were reconstructed using Image J software. The Data was analysed with the t-test, and Mann-Whitney statistical tests ($\alpha=0.05$).

Results: The total number of the right and left straight rugae was significantly higher in males ($p = 0.039$). The number of circular rugae on the right side and, primary rugae on the left side of males, was significantly higher ($p = 0.048$). There was also a significant difference between males and females in the total number of circular rugae ($p = 0.003$). No significant difference was observed between the two sexes in the other variables. Based on audit analysis, this model correctly predicted 66% of females and 34% of males studied. The ability of this function to classify cases in other samples and in the general case was estimated at 64%. **Conclusion:** It can be concluded that the number and morphology of palatal rugae can be used for sex estimation in forensic dentistry but additional studies with a larger sample size are needed to make a definitive statement.

Keywords: Forensic Medicine; Sex; Rugoscopy

Introduction

In some situations such as the explosion of chemical and nuclear bombs, crime investigations, and natural disasters, sex is the top priority of a forensic investigator (1). Forensic dentistry is one of the new branches of forensic medicine and forensic science (2). It is the application of dentistry to the settlement of forensic issues, or in other words the use of dental evidence for the benefit of justice (2). Sex estimation is one of the crucial issues in forensic sciences and

sometimes it can be puzzling for forensic specialists (3). Bone remnants can be used to determine a person's sexual identity since they are the last parts that are destroyed after death (4). Importantly, there are many valid parameters for sex estimation, including the anatomical differences of the skull, but it is stated as a rule in forensic medicine that, the more complete information about the sex differences of the various organs, the more accurate the estimation.

The palate is an anatomical structure in the oral cavity that exhibits a distinct feature known as the "rugae". The rugae of the palate can be classified into two distinct types based on their size. The first type is referred to as "primary" and is characterized by a size greater than 5 mm. The second type, known as "secondary", is relatively smaller in size, ranging between 3 and 5 mm.(5, 6). Embryological studies have demonstrated that the formation of palatal rugae commences during fetal development, between 12 to

Corresponding author: Dr. Mohammad Javad Saeedi-Borujeni
Department of Medical Basic Sciences, Isfahan (Khorasgan) Branch, Islamic Azad University, Isfahan, Iran
Email: saeedib694@gmail.com

¹Isfahan (Khorasgan) Branch, Islamic Azad University, Isfahan, Iran

²Community Health Research Center, Isfahan (Khorasgan) Branch, Islamic Azad University, Isfahan, Iran

³Department of Medical Basic Sciences, Isfahan (Khorasgan) Branch, Islamic Azad University, Isfahan, Iran

14 weeks of gestation, and persists throughout the individual's lifespan. Additionally, histological studies have revealed that the connective tissue between the submucosal adipose tissue and the reticular layer of the palate participates in the developmental process of palatal rugae (7). It is now widely recognized that the pattern of palatal rugae is unique to everyone (8). In many developed countries, the pattern of rugae, along with other forms of identification such as chiloscropy and fingerprints, are taken and maintained. Palatal rugae are in areas that are resistant to many types of injuries and can withstand very high temperatures due to the support of structures such as lips, tongue, excess fat, teeth, and bones (9). The present study aims to investigate sexual dimorphisms in palatal rugae patterns in Isfahan, Iran, with a particular focus on epigenetic and socioeconomic factors. As palatal rugae are considered a reliable tool for identification in forensic dentistry, it is imperative to understand the potential impact of sex differences on their patterning.

Material and Methods

In this cross-sectional observational study that was conducted from September 2019 to February 2020, fifty female students and fifty male students from two faculties of dentistry and nursing of Islamic Azad

University of Isfahan (Khorasgan)(KHUISF) were selected based on entry criteria.

This study was approved by the ethics committee of the KHUISF (1399.013). After obtaining conscious consent, maxillary arch impressions were developed in patients using hydrochloric acid.

To enhance the clarity of the existing rugae a graphic pencil was utilized. Following this process, the images were reconstructed using ImageJ software (Version 1.41o, Java 1.6.0_10, Wayne Rasband, U.S. National Institutes of Health, Bethesda, MD, USA; website: <http://rsb.info.nih.gov/ij/download.html>) and subsequently analysed in terms of their respective number and shape. This methodological approach provides a comprehensive understanding of the rugae's characteristics and enables a detailed analysis of the various features associated with them.

In the present study palatal rugae were examined in four distinct types namely straight, wavy, curved, and circular (as shown schematically in Figure.1), in individuals whose parents and grandparents were born in Isfahan and were over the age of 18. Participants with congenital anomalies, a positive history of palate disorders, hypersensitivity to hydrochloric materials, and a history of orthodontic treatment were excluded from the study.

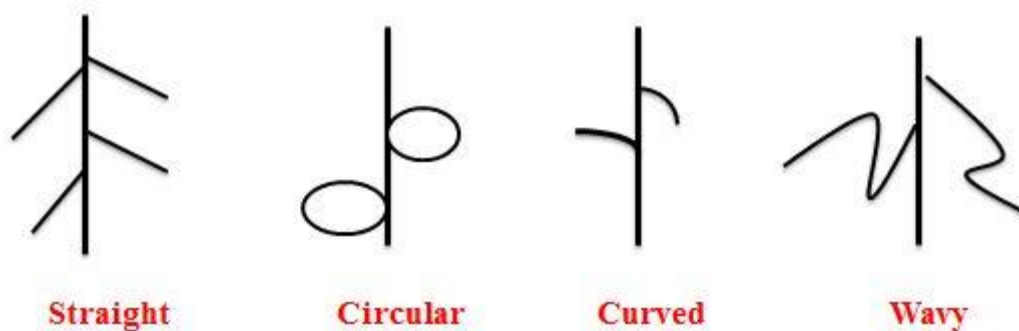


Figure 1. The types of palatal rugae investigated in the present study

Obtained data were statistically analysed by Kolmogorov-Smirnov, Mann-Whitney U nonparametric test, T-test, Box's M test, and Wilk's lambda test in SPSS 24. A P value of < 0.05 was considered a statistically significant difference.

Then, Box's M test was performed and based on the results of that, test statistics was 1.35 and the significance level was 0.129. Given that the significance level of the Box's M test is greater than 0.05, so the assumption of equality of variance-covariance matrix between the two groups of males

and females was confirmed. The model significance test was performed through Wilk's lambda test.

Results

In this study, 100 students, including 50 male and 50 female, were examined in terms of the shape and size of the palatal rugae. Based on the information summarized in Table 1, the wavy rugae were the most numerous rugae in total and the straight rugae were second in number. Also, in terms of size, the number of secondary rugae was higher than the primary.

Table 1. Descriptive analysis of the total number of palatal rugae

Palatal rugae	Number of subjects	Number of rugae	Mean±SD
primary	100	408	4.08 ± 1.56
secondary	100	527	5.27 ± 1.92
straight	100	295	2.95 ± 1.06
circular	100	72	0.72 ± 0.72
curved	100	251	2.51 ± 1.38
wavy	100	317	3.17 ± 1.12

The Kolmogorov-Smirnov test showed that the distribution of all the studied variables was abnormal. For this purpose, nonparametric tests were used to investigate the differences. (Mann Whitney U test for comparison between two groups). The sum of the right and left straight rugae in males was significantly higher than in females ($p = 0.039$). The number of circular vestibules on the right side of the male's palate

was significantly higher than that of females ($p = 0.048$). The number of circular rugae on the right and left was significantly different between males and females ($p = 0.003$). The number of primary rugae on the left side of males was significantly higher than that of females ($p = 0.048$), but no significant difference was found between the two sexes in the other variables (Table 2).

Table 2. Mann Whitney test to compare research variables in both males and females

Rugae	Variable	Female	Male	P value
		Mean±SD	Mean±SD	
Straight	Right side	1.24±0.68	1.56±0.81	0.053
	Left side	1.50±0.73	1.60±0.63	0.369
	Total	2.74±1.15	3.16±0.93	0.039
Circular	Right side	0.26±0.44	0.48±0.56	0.048
	Left side	0.24±0.43	0.46±0.61	0.065
	Total	0.50±0.61	0.94±0.76	0.003
Curved	Right side	1.34±0.84	1.26±0.82	0.643
	Left side	1.26±0.78	1.16±0.79	0.583
	Total	2.6±1.44	2.42±1.34	0.551
Wavy	Right side	1.68±0.74	1.50±0.61	0.131
	Left side	1.50±0.81	1.66±0.82	0.366
	Total	3.18±1.20	3.16±1.03	0.948
Primary	Right side	1.04±0.90	2.10±0.88	0.816
	Left side	1.78±0.93	2.24±1.2	0.048
	Total	3.82±1.39	4.34±1.68	0.135
Secondary	Right side	2.48±1.09	2.66±1.25	0.417
	Left side	2.72±0.99	2.68±1.18	0.877
	Total	5.2±1.75	5.34±2.09	0.828

Then, Box's M test was performed and based on the results of that, test statistics was 1.35 and the significance level was 0.129. Given that the significance level of the Box's M test is greater than 0.05, so the assumption of

equality of variance-covariance matrix between the two groups of males and females was confirmed. The model significance test was performed through Wilk's lambda test and the results are given in Table 3.

Table 3. Model significance test was performed through Wilk’s lambda test

	Wilk’s lambda	χ^2	Degrees of freedom	P value
Final model – total of left and right sides	0.86	13.80	6	0.032

Given that the significance level of the Wilk’s lambda test is less than 0.05 (p=0.032), we conclude that the linear discriminant analysis model is a suitable model

for the data. The coefficients of each of the variables related to the shape and size of palatal rugae used in the discriminant function are given in Table 4.

Table 4. The coefficients of each of the variables related to the shape and size of palatal rugae

Type of rugae	Function
circular	0.639
straight	-0.111
wavy	-0.658
curved	-0.724
primary	0.666
secondary	0.516
Fixed coefficient	-1.696

The method for calculating an unidentified sex (Z*) among the subjects was derived according to the following formula:

$$Z^* = -1.696 + 0.66(\text{primary}) + 0.51(\text{secondary}) - 0.724(\text{curved}) + 0.639(\text{circular}) - 0.658(\text{wavy}) - 0.11(\text{straight})$$

After performing the calculations with the above formula, if the number is close to -0.391, it indicates that the sample is female, and if it is close to 0.391, it indicates that the sample is male. The discriminant function obtained from this model correctly predicted 66% of females and 34% of males studied. The ability of this function to classify cases in other samples and in the general case was estimated at 64%.

Discussion

Over the years, the use of palatal rugae pattern in forensic science and forensic medicine has been a topic of interest for researchers. Many studies have focused on the use of the rugae pattern in sex determination and personality identification (10). It is important to note that the pattern of rugae is influenced by genetic and geographical factors, making it crucial to determine the pattern in various regions and races. The study found that wavy rugae were the most common type, followed by straight rugae. Additionally, secondary rugae were found to be more numerous than primary rugae in terms of size. It should be noted that comparing the results of this study with previous studies could be biased due to differences in the populations that were studied. However, some similarities and differences in the

patterns of palatal rugae across different societies were mentioned.

In 2019, Pakshir and colleagues (11) conducted a study in Shiraz that identified the wavy pattern as the most prevalent type of rugae. Likewise, a study by Kommalapati et al (12) and Jaisingh et al (13) conducted in India in 2017 and 2016, respectively, found wavy rugae to be the most common type. The results of a study by Thabitha et al (14) revealed that wavy rugae were the most prevalent type of palatal rugae. Similarly, Buyuk et al (15) conducted a study in Turkey in 2019, which identified wavy rugae as the most frequent type in their study population. While definitive statements regarding the differences between these studies are challenging, Central Asian and West Asian races may share similar patterns of palatal rugae. However, this issue remains open to discussion.

It has been mentioned that the primary rugae are more than 5 mm and the secondary rugae are between 3 and 5 mm in size (13). In our study, the number of secondary rugae was more than the primary. The results of our study were inconsistent with the results of studies performed by Pakshir in Shiraz (11), and Jaisingh et al.(13). In the present study, the sum of the right and left straight rugae in males was significantly higher than in females. The number of circular vestibules on the right side of the males’ palate was significantly higher than that of females.

The number of circular rugae on the right and left was significantly different between males and females. The number of primary rugae on the left side of males

was significantly higher than that of females, but no significant difference was found between the two sexes in the other variables. The results of similar studies in different populations indicate a different distribution pattern on the right and left, as well as in both sexes (16-19). However, in most studies, the number of rugae in males was higher than in females and our study is in agreement with them.

In such studies, researchers use discriminant analysis to obtain a mathematical relationship for estimating sex based on the number of rugae and their type. Based on the discriminant function obtained in our study, sex estimation was predictable in 66% of females and 34% of males. Also, the ability of this function to classify cases in other samples and in the general case was estimated at 64%. This rate was estimated at 60.8% in Pakshir's study (11) and 70% in a study conducted by Malekzadeh in Shiraz (20). It is important to note that the use of the obtained formula in any study cannot be generalized to other societies.

One of the limitations of the present study was the small sample size. To validate the findings, further studies are recommended to be conducted in Iran, particularly in the city of Isfahan. In our study, we set the minimum age requirement as 18 years. However, since the participants were all students, their ages were mostly limited to the third decade of life. Therefore, it was difficult for the researchers to investigate any possible changes that may occur with age.

Conclusion

The number and morphology of palatal rugae differ significantly between both sexes, making it useful for estimating sex in forensic medicine. However, to make a definitive statement about the differences in palatal rugae patterns, further studies with a larger sample size are necessary.

Conflict of Interests: The authors of this manuscript declare that they have no conflicts of interest, real or perceived, financial or non-financial in this article.

Acknowledgement

Our study was supported by KHUISF Deputy Research. We gratefully thank the Vice Chancellor for research, KHUISF.

References

1. Fereidooni Naghani A, Ghodousi A, Ghafari R, Abbasi S. Evaluation of Some Mandibular Indexes for Sex Estimation by Use of CBCT Imaging in Iranian population samples. *Contemporary Orofacial Sciences*. 2023;1(1): 22-28
2. Abasi P, Ghodousi A, Ghafari R, Abbasi S. Comparison of accuracy of the maxillary sinus area and dimensions for sex estimation lateral cephalograms of Iranian samples. *Journal of Forensic Radiology and Imaging*. 2019;17:18-22.
3. Heng D, Manica S, Franco A. Forensic Dentistry as an Analysis Tool for Sex Estimation: A Review of Current Techniques. *Research and Reports in Forensic Medical Science*. 2022;12:25-39.
4. Ata-Ali J, Ata-Ali F. Forensic dentistry in human identification: A review of the literature. *J Clin Exp Dent*. 2014;6(2):e162-e167
5. Armstrong J, Seehra J, Andiappan M, Jones AG, Papageorgiou SN, Cobourne MT. Palatal rugae morphology is associated with variation in tooth number. *Sci Rep*. 2020;10(1):19074.
6. Ganatra MA, Othman D. Anatomy of the normal palate. In: Fayyaz, G.Q. (eds) *Surgical Atlas of Cleft Palate and Palatal Fistulae*. Springer: Singapore, 2022
7. Smitha T, Vaswani V, Deepak V, Sheethal HS, Hema KN, Jain VK. Reliability of palatal rugae patterns in individual identification. *J Oral Maxillofac Pathol*. 2021;25(3):555.
8. Prakoeswa BF, Kurniawan A, Alias A, Chusida AN, Marini MI, Rizky BN. Palatal rugoscopy as an aid for sex determination in Tengger population, Indonesia. *Bulletin of the International Association for Paleodontology*. 2021;15(2):77-82.
9. Ariyani NPP, Auerkari EI, Gultom FP. The accuracy between palatoscopy method and cheiloscopy method for sex determination in Asian population. In Rahman SF, Zakiyuddin A, Whulanza Y, Intan N, editors, *6th Biomedical Engineering's Recent Progress in Biomaterials, Drugs Development, and Medical Devices: Proceedings of the 6th International Symposium of Biomedical Engineering, ISBE 2021*. American Institute of Physics Inc. 2022. 030005. (AIP Conference Proceedings)
10. Elrewieny NM, Ismail MM, Zaghloul HS, Abielhassan MH, Ali MM. Palatoscopy and odontometrics' potential role in sex determination among an adult Egyptian population sample: A pilot study. *Homo*. 2020; 71(1):19-28.
11. Pakshir F, Ajami S, Pakshir HR, Malekzadeh AR. Characteristics of palatal rugae patterns as a potential tool for sex discrimination in a sample of Iranian children. *J Dent (Shiraz)*. 2019;20(1):1-9.
12. Kommalapati RK, Katuri D, Kattappagari KK, Kantheti LP, Murakonda RB, Poosarla CS, et al. Systematic analysis of palatal rugae pattern for use in human identification between two different populations. *Iran J Public Health*. 2017;46(5):602-607
13. Jaishigh R, Deshmukh S, Srilatha KT. Palatal rugae patterns as an adjunct to gender determination in

- forensic identification procedures in a paediatric population. *J Forensic Sci Criminol*. 2016;4(3):1-6.
14. Thabitha RS, Reddy RE, Manjula M, Sreelakshmi N, Rajesh A, Kumar VL. Evaluation of palatal rugae pattern in establishing identification and sex determination in Nalgonda children. *J Forensic Dent Sci*. 2015;7(3):232-237.
 15. Buyuk SK, Simsek H, Yasa Y, Genc E, Turken R. Morphological assessment of palatal rugae pattern in a Turkish subpopulation. *Australian Journal of Forensic Sciences*. 2019;51(1):40-8.
 16. Sivaraj A. Significance of palatal rugae in orthodontics. *J Orofac Res* 2013;3(3):202-209.
 17. Shetty M, Premalatha K. Study of palatal rugae pattern among the student population in Mangalore. *J Indian Acad Forensic Med*. 2011;33(2):112-5.
 18. Bing L, Wu XP, Feng Y, Wang YJ, Liu HC. Palatal rugae for the construction of forensic identification. *Int J Morphol*. 2014;32(546):546-0.
 19. Jibi PM, Gautam KK, Basappa N, Raju OS. Morphological pattern of palatal rugae in children of Davangere. *J Forensic Sci*. 2011;56(5):1192-1197.
 20. Malekzadeh AR, Pakshir HR, Ajami S, Pakshir F. The application of palatal rugae for sex discrimination in forensic medicine in a selected Iranian population. *Iran J Med Sci*. 2018;43(6):612-622.