Contemporary Orofacial Sciences (2026) 4(1): 17-28
DOI: 10.66224/cofs.4.1.5

ORIGINAL ARTICLE

A Histological Comparison of the Effects of the Steroidal Anti-inflammatory Drug (Dexamethasone) on Bone Fracture Healing in Male and Female Subjects (An Animal Study)

Farid Esmail Beig[1], Hassan Momeni[2]*, Nader Kalbasi[3], Akram Ghomi[4]

Received: 2025-05-20/ Accepted: 2025-12-15 / First publication date: 2026-03-10

© The Author(s) 2026

Abstract

Background: Steroidal anti-inflammatory drugs like dexamethasone are commonly prescribed for managing pain after oral and maxillofacial surgeries. However, their preoperative use may impair bone healing. This study investigated the histological effects of dexamethasone on mandibular fracture healing in male and female rats.

Materials and Methods: This experimental animal study included 64 Wistar Albino rats (12 weeks old, 250–300 g) that underwent surgically induced mandibular fractures and were randomized into 8 groups. Experimental groups received dexamethasone (1 mg/kg), while controls received normal saline. Animals were sacrificed at 2 and 4 weeks postoperatively for histological evaluation. Parameters assessed included union, bone integration, cortical and cancellous bone integrity, bridging of the defect, inflammation, cellularity, and cellular morphology. Data were analyzed using the Kruskal–Wallis and Mann–Whitney U tests with Bonferroni correction ($\alpha = 0.05$).

Results: Control groups showed significantly better healing outcomes than dexamethasone-treated rats, with higher scores for bone union, integration, cortical and cancellous bone formation, defect bridging, cellularity, and morphology (all $p < 0.001$, except cellularity $p = 0.011$). Dexamethasone groups exhibited significantly more inflammation ($p < 0.001$). Female rats demonstrated poorer healing in early stages, though differences between sexes diminished over time.

Conclusion: Dexamethasone (1 mg/kg) delays mandibular bone healing and enhances local inflammation in both sexes, particularly in females during early healing. Its use in maxillofacial fractures should be approached with caution. Further studies are recommended.

Keywords: Dexamethasone, Bone healing, Rat

Introduction

Despite advancements in maxillofacial surgery and standardized treatment protocols for human fractures and bone defects, incomplete or delayed bone healing still occurs in approximately 5% to 20% of cases, which remains a major challenge for treatment teams and imposes significant burdens on healthcare systems, with outcomes influenced by both biological and mechanical factors. (1)

Bone regeneration is a complex biological process involving three phases: inflammation, repair, and delayed remodeling. Intricate molecular mechanisms tightly regulate this process. Systemic and local

Corresponding author: Hasan Momeni

Department of Oral & maxillofacial surgery, Faculty of Dentistry ,Isfahan (Khorasgan) Branch, Islamic Azad University, Isfahan, Iran
Email: hasanmomeni@iau.ac.ir

[1]Department of Oral & maxillofacial surgery, Faculty of Dentistry, Isf.c., Islamic Azad University, Isfahan, Iran
[2]Department of Oral & maxillofacial surgery, Faculty of Dentistry, Isf.c., Islamic Azad University, Isfahan, Iran
[3] Department of Oral & maxillofacial Pathology, Faculty of Dentistry, Isf.c., Islamic Azad University, Isfahan, Iran
[4] Department of Oral & maxillofacial surgery, Faculty of Dentistry, Isf.c., Islamic Azad University, Isfahan, Iran

[Downloaded from cofs.khuisf.ac.ir on 2026-11-26]

[DOI: 10.66224/cofs.4.1.5]

factors, as well as various cell types and growth factors delivered to the injury site via surrounding tissues and the bloodstream, contribute to bone healing. (2,3)

While various strategies, such as growth factors and anabolic agents, have been explored to enhance bone regeneration, few have addressed their role in counteracting glucocorticoid-induced bone impairment. (4–6) Conversely, certain medications, such as specific antibiotics, have been reported to delay or impair bone healing. (7) Identifying and avoiding these drugs may promote more optimal bone regeneration. Estrogen plays a pivotal role in modulating bone turnover by promoting osteoblast activity and suppressing osteoclast-mediated resorption. Fluctuations or deficiencies in estrogen, particularly in females, may impair the coupling between bone formation and resorption, thereby influencing the rate and quality of bone healing. (8) In addition to perfusion, systemic metabolism, and age, previous animal studies have suggested that female sex may be a risk factor for impaired bone healing. This may be due to hormonal differences, particularly fluctuations in estrogen, which influence bone remodeling by altering the balance between osteoblast and osteoclast activity. Clinically, both sex and mechanical stability simultaneously affect bone defect healing. Understanding the influence of these factors could guide gender-specific modifications to fracture treatment protocols, potentially improving bone-healing outcomes.(1)

Glucocorticoids have well-documented effects on bone density and influence the activity of osteoblasts and osteoclasts. (9) Moreover, preoperative or pre-fracture administration of glucocorticoids, especially dexamethasone, has been associated with delayed bone healing. (10)

Steroidal anti-inflammatory drugs (e.g., hydrocortisone) are widely used to manage pain and inflammation, including those related to bone fractures and postoperative maxillofacial pain. Among these, dexamethasone is a potent, long-acting glucocorticoid with stronger anti-inflammatory effects than hydrocortisone and is frequently used in clinical settings involving orthopedic and maxillofacial surgery. However, to the best of the authors' knowledge, no study has specifically investigated the effects of these drugs on bone healing across both sexes. Dexamethasone was selected as an appropriate preclinical model due to its high potency, long half-life, and widespread clinical use in controlling surgery- and fracture-related inflammation and pain. Given its common clinical application, understanding its potential impact on bone regeneration is essential. Moreover, considering evidence of sex-related differences in healing, this study aimed to compare the histological effects of the steroidal anti-inflammatory drug dexamethasone on fracture healing in male and female rats.

Materials and Methods

This experimental laboratory study used an animal model. The study protocol was reviewed and approved by the Ethics Committee for Medical Research of Islamic Azad University, Khorasgan Branch (ethical code: IR.IAU.KHUISF.REC.1401.397). All experimental procedures were performed in accordance with internationally accepted guidelines for the care and use of laboratory animals.

A total of 64 Wistar Albino rats, including both males and females, were included in the study. All animals were clinically healthy and free of systemic disease, infection, or pathological conditions that could interfere with bone healing. The rats were 12 weeks old and weighed 250-300 g at the beginning of the experiment.

Animals were maintained under standard laboratory conditions with controlled temperature (22 ± 2 °C), relative humidity (40–60%), and a 12-hour light/dark

[Downloaded from cofs.khuisf.ac.ir on 2026-11-26]

[DOI: 10.66224/cofs.4.1.5]

cycle. Standard laboratory chow and water were provided ad libitum.

Following fracture induction, animals were randomly allocated into eight experimental groups (n = 8 per group) based on sex and pharmacological intervention:

- Control groups (Groups 1 and 2): male and female rats receiving daily intraperitoneal injections of normal saline
- Dexamethasone-treated groups (Groups 3 and 4): male and female rats receiving intraperitoneal dexamethasone (Dexamethasone Sodium Phosphate, Darou Pakhsh, Iran) at a dose of 1 mg/kg/day for two consecutive days

Each group was further divided into two equal subgroups. Animals were euthanized at 2 weeks and 4 weeks postoperatively (n = 8 at each time point).

General anesthesia was induced by intraperitoneal administration of ketamine (70 mg/kg) (Ketamine hydrochloride, Alfasan International B.V., Netherlands) and xylazine (12 mg/kg) (Xylazine hydrochloride, Alfasan International B.V., Netherlands). To achieve local anesthesia and hemostasis, 0.5 mL of articaine with epinephrine (1:200,000) was injected at the surgical site(11).

A standardized fracture was created at the inferior border of the mandible using a 1.1-mm surgical bur, without internal fixation.

Postoperative pain control was achieved by intramuscular injection of tramadol (1 mg/kg) (Tramadol Hydrochloride, Darou Pakhsh, Iran) for all animals. A multimodal analgesic protocol was applied to minimize pain and stress. At the designated time points, animals were euthanized using an overdose of ketamine, and death was confirmed by a qualified veterinarian based on standard clinical criteria.

Following euthanasia, mandibular specimens were harvested immediately and fixed in 10% neutral buffered formalin. After routine tissue processing, specimens were embedded in paraffin, and 4-µm-thick sections were prepared. All sections were stained with hematoxylin and eosin (H&E) for histological evaluation.

Histological analysis was performed by a blinded examiner using a light microscope (Nikon Instruments, Japan). Bone healing was assessed using a semi-quantitative scoring system adapted from previously validated studies. The following parameters were evaluated:

- Degree of bone union
- Integration with the adjacent bone
- Cortical integrity
- cancellous bone
- inflammatory
- bridging of the bone defect
- Cellularity
- Cellular Morphology

Each parameter was graded according to predefined criteria, and the overall histological healing score was calculated for each specimen. These scores were used for subsequent statistical analysis.

After confirming data normality using the Shapiro–Wilk test, the data were analyzed using the Kruskal–Wallis test and the Bonferroni post hoc test, with a significance level set at $p < 0.05$.

Results

The Kruskal–Wallis test revealed that all bone healing and regeneration indices, including bone union, integration of the lesion with adjacent bone, cortical integrity, cancellous bone, and bridging of the bone defect, were significantly higher in the placebo group compared with the dexamethasone-treated group ($p < 0.001$) (Table 1).

[Downloaded from cofs.khuisf.ac.ir on 2026-11-26]

[DOI: 10.66224/cofs.4.1.5]

Table 1. Bone healing and regeneration indices in placebo and dexamethasone groups according to gender and time

Groups	Gender	Time	Bone union	Integration with the adjacent bone	Cortical integrity	cancellous bone	bridging of the bone defect
			Mean ± SD	Mean ± SD	Mean ± SD	Mean ± SD	Mean ± SD
Placebo	Female	2 weeks	4 ± 0	2.63 ± 0.52	4 ± 0	3 ± 0	3 ± 0
	Female	4 weeks	4 ± 0	3 ± 0	4 ± 0	3 ± 0	3 ± 0
	Male	2 weeks	4 ± 0	3 ± 0	4 ± 0	3 ± 0	3 ± 0
	Male	4 weeks	4 ± 0	3 ± 0	4 ± 0	3 ± 0	3 ± 0
Dexamethasone	Female	2 weeks	1.88 ± 0.35	1.5 ± 0.53	1.5 ± 0.53	2.25 ± 0.46	1.88 ± 0.35
	Female	4 weeks	2.38 ± 0.74	1.88 ± 0.35	1.88 ± 0.35	2.63 ± 0.52	1.87 ± 0.35
	Male	2 weeks	2.62 ± 0.74	2 ± 0.53	2.13 ± 0.64	2.38 ± 0.52	2.5 ± 0.76
	Male	4 weeks	2.38 ± 0.52	2.25 ± 0.46	2 ± 0.76	2.75 ± 0.71	2.75 ± 0.46
P value			<0.001	<0.001	<0.001	<0.001	<0.001

In pairwise comparisons using the Mann–Whitney U test with Bonferroni correction, all placebo subgroups, regardless of sex or time point, exhibited significantly higher bone-healing scores than their corresponding dexamethasone-treated subgroups ($p < 0.05$). For most of these indices, no significant differences related to sex or time were observed within the dexamethasone group ($p > 0.05$); however, in some subgroups, particularly at the second week, the reduction in bone-healing parameters was more pronounced (Figure 1).

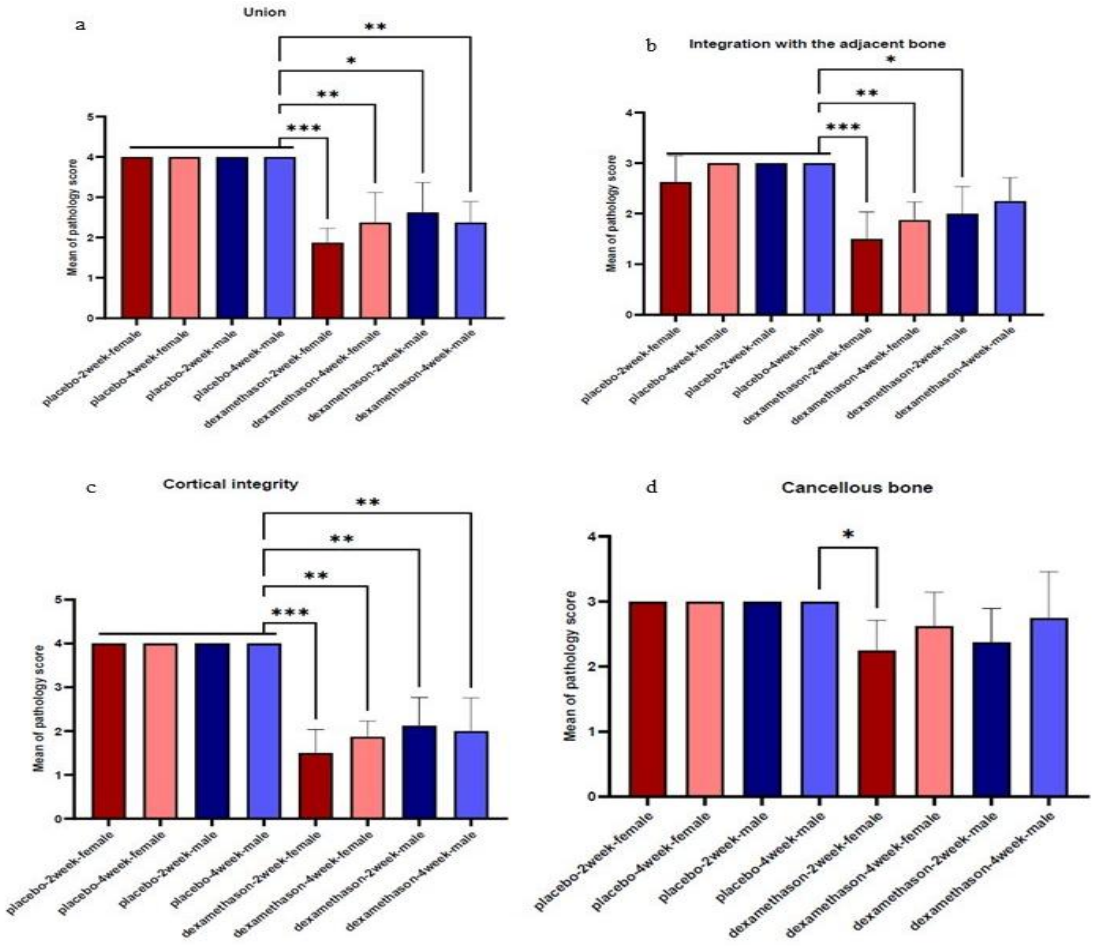

Figure 1. Pairwise comparisons of (a) bone union, (b) integration with adjacent bone, (c) cortical integrity, and (d) cancellous bone in dexamethasone- and placebo-treated animals according to sex and time.
(Significance levels: *$p < 0.05$; **$p < 0.01$; ***$p < 0.001$)

[Downloaded from cofs.khuisf.ac.ir on 2026-11-26]

[DOI: 10.66224/cofs.4.1.5]

According to the Kruskal–Wallis test, inflammatory scores were significantly higher in the dexamethasone-treated group than in the placebo group ($p < 0.001$) (Table 2).

Table 2. Inflammatory scores in placebo and dexamethasone groups according to gender and time

Groups	Gender	Time	Inflammation	P value
			Mean ± SD	
Placebo	Female	2 weeks	0.1 ± 0	<0.001
	Female	4 weeks	0.1 ± 0	
	Male	2 weeks	0.1 ± 0	
	Male	4 weeks	0.1 ± 0	
Dexamethasone	Female	2 weeks	1.88 ± 0.35	
	Female	4 weeks	1.25 ± 0.46	
	Male	2 weeks	1.63 ± 0.52	
	Male	4 weeks	1.63 ± 0.52	

Pairwise comparisons using the Mann–Whitney U test with Bonferroni correction showed that inflammatory scores in female rats at the second week were significantly lower in the placebo group than in the dexamethasone group ($p < 0.01$). In contrast, no significant differences in inflammation severity were observed in the remaining subgroups ($p > 0.05$). Furthermore, no significant differences in inflammatory scores were observed between male and female rats within the dexamethasone group at any time point (Figure 2).

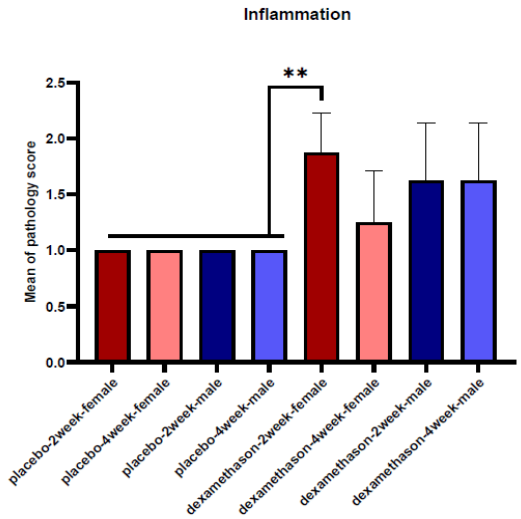

Figure 2. Pairwise comparisons of inflammatory scores in dexamethasone- and placebo-treated animals according to sex and time.(Significance level: **p < 0.01)

The Kruskal–Wallis test also showed that cellular indices, including cellularity and cellular morphology scores, were significantly higher in the placebo group than in the dexamethasone-treated group ($p < 0.001$) (Table 3).

Table 3. Cellularity and cellular morphology scores in placebo and dexamethasone groups according to sex and time

Groups	Gender	Time	Cellularity	Cellular morphology
			Mean ± SD	Mean ± SD
Placebo	Female	2 weeks	2.38 ± 0.52	5 ± 0
	Female	4 weeks	2.38 ± 0.52	5 ± 0
	Male	2 weeks	2.38 ± 0.52	5 ± 0
	Male	4 weeks	2.50 ± 0.53	5 ± 0
Dexamethasone	Female	2 weeks	1.38 ± 0.52	2.38 ± 0.52
	Female	4 weeks	2.38 ± 0.52	3.13 ± 0.83
	Male	2 weeks	2.13 ± 0.64	4.38 ± 0.52
	Male	4 weeks	2.63 ± 0.52	4.50 ± 0.53
P value			0.011	<0.001

In pairwise analyses using the Mann–Whitney U test with Bonferroni correction, a significant reduction in cellularity and cellular morphology scores was observed in dexamethasone-treated female rats, particularly at the second week, compared with the placebo group ($p < 0.05$). Additionally, within the

[Downloaded from cofs.khuisf.ac.ir on 2026-11-26]
[DOI: 10.66224/cofs.4.1.5]

dexamethasone group, female rats at the second week exhibited significantly lower cellular indices than male rats ($p < 0.05$), whereas no significant differences were observed in the other comparisons ($p > 0.05$) (Figures 3).

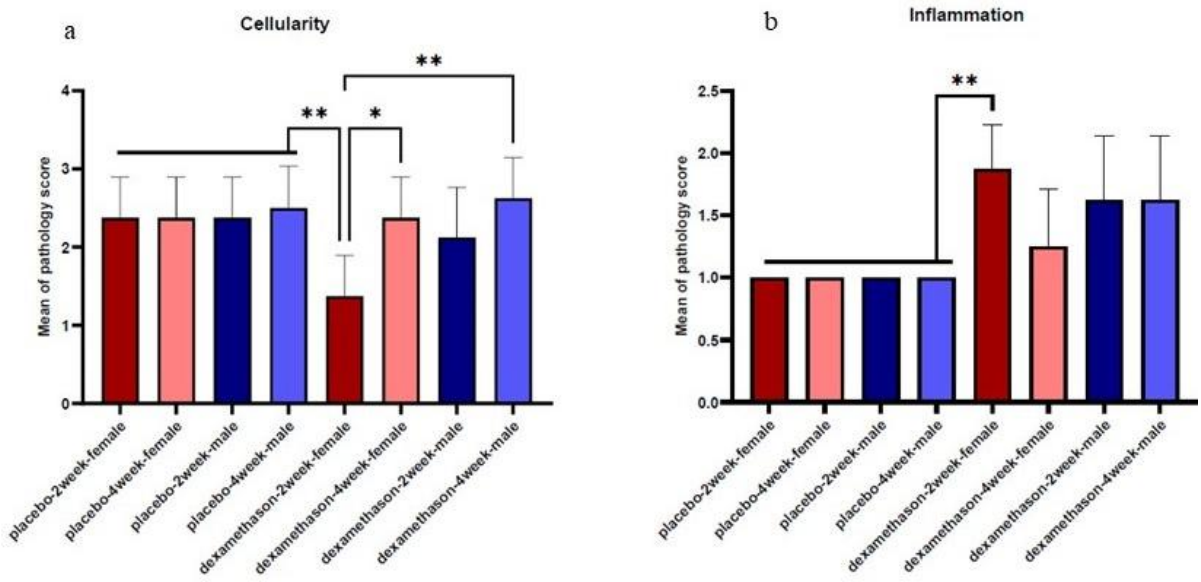

Figure 3. Pairwise comparisons of (a) cellularity and (b) cellular morphology scores in dexamethasone- and placebo-treated animals according to sex and time. Significance levels: *$p < 0.05$; **$p < 0.01$()

Overall, dexamethasone administration resulted in a significant reduction in bone healing, bone regeneration, and cellular indices, accompanied by increased inflammatory severity. The effects of sex and time were limited across most variables and were mainly observed in cellular parameters, particularly at the second-week time point.

Representative histological images illustrating the effects of dexamethasone and normal saline on bone healing in mandibular fractures are presented in Figures 4 and 5, highlighting differences in bone formation, tissue remodeling, and cellularity between the treatment groups.

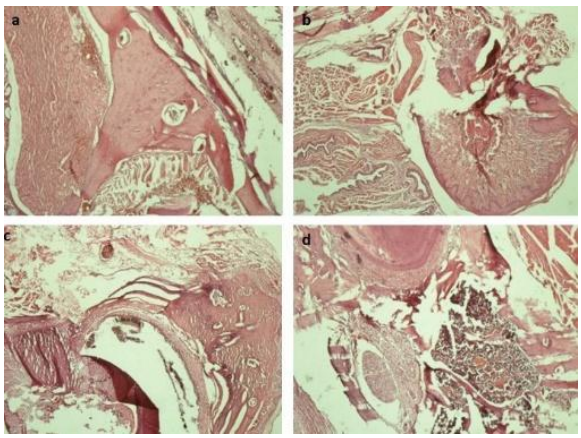

Figure 4. Histological appearance of wound healing in female mice at (a) 2 weeks and (b) 4 weeks, and in male mice at (c) 2 weeks and (d) 4 weeks following dexamethasone administration, illustrating tissue changes, bone formation, and cellularity throughout the healing process.

[Downloaded from cofs.khuisf.ac.ir on 2026-11-26]

[DOI: 10.66224/cofs.4.1.5]

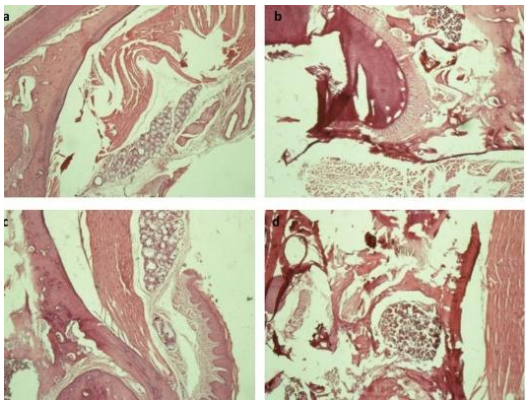

Figure 5. Histological appearance of wound healing in female mice at (a) 2 weeks and (b) 4 weeks, and in male mice at (c) 2 weeks and (d) 4 weeks in the placebo group.

Discussion

Although glucocorticoids such as dexamethasone are commonly administered in maxillofacial surgery (11), their influence on bone healing remains incompletely elucidated, especially given the puzzling lack of research on gender differences in facial injury. The goal of this study was to assess the histological effect that dexamethasone has on the healing of mandibular fractures in both male and female rats.

The study focused on nine crucial parameters of mandibular fracture healing: the degree of connection, integration into the bone, exposure of the cortex, formation of spongy bone, inflammation, bridging of bony tissue, cell population within the defect, and defect geometry. The results demonstrate that the dosage of 1 mg/kg of dexamethasone markedly impaired all parameters of healing, particularly in females. Nevertheless, the initial differences between the genders lessened over time. The rats treated with a placebo showed significantly superior results in all evaluated parameters, except for inflammation and early-stage fibrous bridging, which were also observed in some dexamethasone-treated groups. However, more advanced bridging was consistently seen in the placebo group. The data imply delayed bone healing, which aligns with other researchers' findings in rabbits and rats using glucocorticoids for tibial fracture healing. (9,12)

Singh et al. (13) conducted a systematic review and concluded that preoperative systemic corticosteroid therapy worsened postoperative oral and maxillofacial surgical wound healing. In our results, the inflammation scores were higher in the dexamethasone group. As described previously, inflammation is the body's response and an essential first phase of wound healing, involving increased vascular permeability, chemotaxis, cytokine and growth factor release, and macrophage activation. (14) Corticosteroids prescribed in these conditions usually have an anti-inflammatory action, but in this case have also been shown to restrict cellular migration, proliferation, and angiogenesis, which delays healing. In addition, corticosteroids inhibit collagen synthesis 17) and also decrease procollagen type I mRNA activity (15)

Wound healing occurs in three overlapping stages: inflammation, remodeling, and proliferation. The progression of capillary formation and collagen fiber deposition is key to maintaining the process. (16) Angiogenesis is an active process, with the fibrin clots being substituted with granulation tissue rich in blood vessels that ultimately matures into scar tissue with collagen. (15,17) In this experiment, inflammation in the dexamethasone-treated female rats in week two was significantly higher compared to the controls, which could not be said for the controls. The disparity in this regard decreased in week four. Mean inflammation scores were 1.0 for the placebo-treated and 1.88 for the dexamethasone-treated female rats in week two. Dromush et al. (18) also observed increased vascularity and inflammatory cell infiltration following dexamethasone treatment. According to Chen et al. (19), dexamethasone administration reduced macrophage recruitment during the inflammatory phase. This paradoxical increase in

[Downloaded from cofs.khuisf.ac.ir on 2026-11-26]

[DOI: 10.66224/cofs.4.1.5]

inflammation despite dexamethasone's known anti-inflammatory properties may reflect a rebound inflammatory response or impaired resolution of acute inflammation due to disrupted macrophage regulation. Moreover, short-term glucocorticoid administration, such as the 2-day regimen used here, has been associated with rebound inflammation upon abrupt withdrawal, thereby impairing the resolution of the inflammatory phase. This paradoxical effect may partially explain the unexpectedly higher inflammation scores in the dexamethasone-treated groups. Alternatively, the finding may reflect a limitation of the model or indicate the need for further investigation to rule out experimental artifacts.

Cellularity scores remained lower in females treated with dexamethasone at week two. These changes suggest an incomplete transition from the inflammatory to the proliferative phase, along with inflammatory and vascular alterations. In the control group, advanced collagen deposition, reepithelialization, and reduced numbers of inflammatory cells indicated more mature granulation tissue and scar tissue—characteristic of accelerated healing, as documented in rodent models of wound healing. (20)

Bone connection scores were higher in all placebo subgroups. One study by Snäll et al. (10) showed that 36.8% of patients treated with dexamethasone developed delayed healing, compared with 11.1% in the control group, suggesting that short-term, high-dose corticosteroid use is associated with complications such as infection and delayed union. These findings underscore the need for caution, particularly with short-term, high-dose dexamethasone regimens, and note that its impact may be less pronounced in young, healthy adults, as shown by Snäll et al. Another study in the same cohort showed that 24.4% of zygomatic fracture patients treated with dexamethasone developed impaired healing as compared with 3.2% of the control group. (21) They further stated that the age of the patients also had an impact on the rate of delayed healing, with patients older than 25 years having elevated rates of impaired healing. Nonetheless, preoperative dexamethasone use did not significantly affect healing rates in young, healthy adults free of infection. (22) These results demonstrate different study designs, dosages, as well as the conditions of the patients being used in the studies, in indication of the need for further scrutiny.

Dexamethasone may impair fracture healing by promoting infection, suppressing angiogenesis, and exerting immunosuppressive effects. Bone-healing disruption is likely multifactorial, and the role of infection appears central. The drug's biological half-life of 36–54 hours means its impact extends beyond the initial healing period. (23–25) Based on our results, short-term, high-dose dexamethasone should be considered a potential risk factor for impaired mandibular fracture healing. Caution is warranted, particularly in clinical scenarios resembling our model, although lower doses or prolonged regimens may exhibit different outcomes. This aligns with findings by Snäll et al. (10), who reported no significant adverse effects in young, healthy adult patients.

Inflammatory responses may also be influenced by systemic immune modulation. Dexamethasone has been shown to suppress macrophage polarization toward pro-inflammatory phenotypes and reduce macrophage migration. (26,27) However, some studies suggest these effects are limited or inconsistent. (28,29) Our findings support the notion that corticosteroid-mediated immune regulation plays a key role in delaying healing.

Male rats in this study generally exhibited better healing outcomes than females. The lowest scores for bone integration, cortical integrity, cancellous bone

[Downloaded from cofs.khuisf.ac.ir on 2026-11-26]

[DOI: 10.66224/cofs.4.1.5]

formation, and tissue morphology were observed in female rats treated with dexamethasone, especially at two weeks. Straub et al. (30) reported similar gender-based disparities in fracture healing, attributing reduced mechanical properties of callus and lower callus cross-sectional area in females to fewer mesenchymal stem cells. Although the MSC function is reportedly independent of gender, females generally exhibit fewer MSCs.

Even with the initial delays, female rats were closing in on the male healing capacity by week four, indicating delayed, not deficient, healing. Zanotti et al. (31) found that adult female rats had reduced cancellous bone content, lower osteogenic markers (osteocalcin and alkaline phosphatase), and fewer mineralized nodules. These are thought to play a role in decreased bone regeneration.

Osteogenic capacity is not sexually dimorphic; however, female rats had greater osteoclast numbers, indicative of greater osteoblastic activity. With respect to time, some of the differences appeared to equalize, corroborating observations from Sprague-Dawley rat models that noted gender differences in osteoblastogenic potential (30). Hormonal variations also influence the function of the skeleton in estrogen and androgen (32), but the authors sought to control for hormonal factors by using prepubescent subjects. Thus, it seems most likely that genetic factors explain the observed sex differences in healing patterns. (33,34)

Bone bridging was also quicker in male rats. Straub's team claimed no differences in bridging by six weeks, which promotes the notion that female healing is just slower. This is consistent with our observation that gender disparity was less pronounced by week four.

Previous animal studies focused mostly on young rats. (35,36) For this study, the authors used 12-week-old rats, considered mature enough to exhibit gender differences in healing. (37,38) However, using 12-week-old rats limits generalizability to older human patients, whose bone healing dynamics and hormonal responses differ. Using 12-week-old rats, which are equivalent to young adults, offers insight into healing patterns in younger subjects but limits extrapolation to older populations. Given that age-related declines in bone regeneration and hormonal responses are well documented in humans, future studies should specifically include aged animal models to evaluate the age-dependent effects of dexamethasone. The limited number of *MSCs* in females, together with lower secretion of osteoinductive factors, likely explains their reduced regenerative potential. (30,39)

Variability in glucocorticoid studies stemming from differences in drugs, dosages, routes of administration, and durations of administration makes comparisons problematic. (40,41) Dexamethasone was selected in this case due to its minimal effect on glucose levels, a well-known factor in bone healing.

A key factor is that rat healing differs from human healing. Whereas humans repair via granulation and epithelialization, rat repair primarily occurs through rapid tissue contraction. Additionally, our non-fixated mandibular fracture model differs from human clinical fractures, which are often rigidly fixated. This limits translational relevance, as fixation alters mechanical stability, vascularization, and healing dynamics. These physiological make-up differences need to be considered when using animals in clinics.

Dexamethasone is cost-effective and routinely prescribed, but should be considered in relation to its healing effects, especially in low-regenerative patients or complex fractures of the maxillofacial complex. Retinoic acid has been suggested as a potential alternative due to its effects on collagen synthesis and wound strength. Retinoic acid, a metabolite of vitamin A, plays a role in osteoblast differentiation and collagen synthesis. Its potential in enhancing bone matrix composition and tensile strength has drawn

[Downloaded from cofs.khuisf.ac.ir on 2026-11-26]

[DOI: 10.66224/cofs.4.1.5]

attention in tissue engineering and bone repair research. Although not yet widely adopted in clinical protocols, preclinical studies suggest that it may support wound strength by increasing hydroxyproline content, a marker of collagen deposition. While Wicke et al. (42) reported increased hydroxyproline content after 17 days of treatment, its role in bone healing remains largely hypothetical and warrants further investigation. (14)

Conclusion

Dexamethasone markedly delays mandibular bone healing in female rats by impairing osteogenesis, angiogenesis, and cell proliferation while increasing local inflammation, highlighting sex-specific corticosteroid sensitivity. Caution is warranted in using dexamethasone for maxillofacial fractures, and sex-adapted strategies or adjunct therapies should be considered to preserve bone regeneration without compromising anti-inflammatory effects.

Conflict of Interests: The authors of this manuscript declare that they have no conflicts of interest, real or perceived, financial or non-financial, in this article

References

1. Mehta M, Duda GN, Perka C, Strube P. Influence of gender and fixation stability on bone defect healing in middle-aged rats: a pilot study. Clin Orthop Relat Res. 2011;469(11):3102-3110.
2. Hausman MR, Schaffler MB, Majeska RJ. Prevention of fracture healing in rats by an inhibitor of angiogenesis. Bone. 2001;29(6):560-564.
3. Keramaris NC, Calori GM, Nikolaou VS, Schemitsch EH, Giannoudis PV. Fracture vascularity and bone healing: a systematic review of the role of VEGF. Injury. 2008;39(Suppl 2):S45-S57.
4. Chao EY, Inoue N. Biophysical stimulation of bone fracture repair, regeneration and remodelling. Eur Cell Mater. 2003;6:72-85.
5. Cook JJ, Summers NJ, Cook EA. Healing in the new millennium: bone stimulators. Clin Podiatr Med Surg. 2015;32(1):45-59.
6. Massari L, Caruso G, Sollazzo V, Setti S. Pulsed electromagnetic fields and low intensity pulsed ultrasound in bone tissue. Clin Cases Miner Bone Metab. 2009;6(2):149-154.
7. Perry AC, Prpa B, Rouse MS, Piper KE, Hanssen AD, Steckelberg JM, et al. Levofloxacin and trovafloxacin inhibition of experimental fracture-healing. Clin Orthop Relat Res. 2003;(414):95-100.
8. Berger MB, Cohen DJ, Olivares-Navarrete R, Williams JK, Cochran DL, Boyan BD, et al. Human osteoblasts exhibit sexual dimorphism in their response to estrogen on microstructured titanium surfaces. Biol Sex Differ. 2018;9(1):30.
9. Waters RV, Gamradt SC, Asnis P, Vickery BH, Avnur Z, Hill E, et al. Systemic corticosteroids inhibit bone healing in a rabbit ulnar osteotomy model. Acta Orthop Scand. 2000;71(3):316-321.
10. Snäll J, Apajalahti S, Suominen AL, Tornwall J, Thoren H. Influence of perioperative dexamethasone on delayed union in mandibular fractures: a clinical and radiological study. Med Oral Patol Oral Cir Bucal. 2015;20(5):e621-e626.
11. Dan AEB, Thygesen TH, Pinholt EM. Corticosteroid administration in oral and orthognathic surgery: a systematic review of the literature and meta-analysis. J Oral Maxillofac Surg. 2010;68(9):2207-2220.
12. Aslan M, Şimşek G, Yildirim Ü. Effects of short-term treatment with systemic prednisone on bone healing: an experimental study in rats. Dent Traumatol. 2005;21(4):222-225.
13. Singh AK, Dhungel S, Bhattarai K, Roychoudhury A. Do the benefits of systemic corticosteroids outweigh adverse effects during maxillofacial trauma surgery? a systematic review and meta-analysis. J Oral Maxillofac Surg. 2021;79(7):1530.e1-1530.e21.
14. Witte MB, Barbul A. General principles of wound healing. Surg Clin North Am. 1997;77(3):509-528.
15. Perez JR, Shull S, Cutroneo KR, Gendimenico GJ, Capetola RJ, Mezick JA. Glucocorticoid and retinoid regulation of alpha-2 type I procollagen promoter activity. J Cell Biochem. 1992;50(1):26-34.

[Downloaded from cofs.khuisf.ac.ir on 2026-11-26]

[DOI: 10.66224/cofs.4.1.5]

16. Drucker M, Cardenas E, Arizti P, Valenzuela A, Gamboa A. Experimental studies on the effect of lidocaine on wound healing. World J Surg. 1998;22(4):394-398.
17. Clark RAF, Lanigan JM, DellaPelle P, Manseau E, Dvorak HF, Colvin RB. Fibronectin and fibrin provide a provisional matrix for epidermal cell migration during wound reepithelialization. J Invest Dermatol. 1982;79(5):264-269.
18. Durmus M, Karaaslan E, Ozturk E, Gulec M, Iraz M, Edali N, et al. The effects of single-dose dexamethasone on wound healing in rats. Anesth Analg. 2003;97(5):1377-1380.
19. Chen Y, Chen X, Zhou Q. Different effects of a perioperative single dose of dexamethasone on wound healing in mice with or without sepsis. Front Surg. 2023;10:927168.
20. Tekin E, Taneri F, Ersoy E, Oguz M, Eser E, Tekin I, et al. The effects of glutamine-enriched feeding on incisional healing in rats. Eur J Plast Surg. 2000;23(2):78-81.
21. Snäll J, Kormi E, Koivusalo AM, Lindqvist C, Suominen AL, Törnwall J, et al. Effects of perioperatively administered dexamethasone on surgical wound healing in patients undergoing surgery for zygomatic fracture: a prospective study. Oral Surg Oral Med Oral Pathol Oral Radiol. 2014;117(6):685-689.
22. Snäll J, Kormi E, Lindqvist C, Suominen AL, Mesimäki K, Törnwall J, et al. Impairment of wound healing after operative treatment of mandibular fractures, and the influence of dexamethasone. Br J Oral Maxillofac Surg. 2013;51(8):808-812.
23. Folkman J, Langer R, Linhardt RJ, Haudenschild C, Taylor S. Angiogenesis inhibition and tumor regression caused by heparin or a heparin fragment in the presence of cortisone. Science. 1983;221(4612):719-725.
24. Hasan Q, Tan ST, Gush J, Peters SG, Davis PF. Steroid therapy of a proliferating hemangioma: histochemical and molecular changes. Pediatrics. 2000;105(1):117-120.
25. Hori Y, Hu D, Yasui K, Smither RL, Gresham GA, Fan TD. Differential effects of angiostatic steroids and dexamethasone on angiogenesis and cytokine levels in rat sponge implants. Br J Pharmacol. 1996;118(7):1584-1591.
26. Sacta MA, Tharmalingam B, Coppo M, Rollins DA, Deochand DK, Benjamin B, et al. Gene-specific mechanisms direct glucocorticoid-receptor-driven repression of inflammatory response genes in macrophages. eLife. 2018;7:e34864.
27. Tu GW, Shi Y, Zheng YJ, Ju MJ, He HY, Ma GG, et al. Glucocorticoid attenuates acute lung injury through induction of type 2 macrophage. J Transl Med. 2017;15(1):181.
28. Xie Y, Tolmeijer S, Oskam JM, Tonkens T, Meijer AH, Schaaf MJM. Glucocorticoids inhibit macrophage differentiation towards a pro-inflammatory phenotype upon wounding without affecting their migration. Dis Model Mech. 2019;12(5):dmm037887.
29. Chatzopoulou A, Heijmans JPM, Burgerhout E, Oskam N, Spaink HP, Meijer AH, et al. Glucocorticoid-induced attenuation of the inflammatory response in zebrafish. Endocrinology. 2016;157(7):2772-2784.
30. Strube P, Mehta M, Baerenwaldt A, Trippens J, Wilson CJ, Ode A, et al. Sex-specific compromised bone healing in female rats might be associated with a decrease in mesenchymal stem cell quantity. Bone. 2009;45(6):1065-1072.
31. Zanotti S, Kalajzic I, Aguila HL, Canalis E. Sex and genetic factors determine osteoblastic differentiation potential of murine bone marrow stromal cells. PLoS One. 2014;9(1):e86757.
32. Callewaert F, Sinnesael M, Gielen E, Boonen S, Vanderschueren D. Skeletal sexual dimorphism: relative contribution of sex steroids, growth hormone-insulin-like growth factor-I (GH-IGF-I) and mechanical loading. J Endocrinol. 2010;207(2):127-134.
33. Beamer WG, Shultz KL, Ackert-Bicknell CL, Horton LG, Delahunty KM, Coombs HF, et al. Genetic dissection of mouse distal chromosome 1 reveals three linked BMD QTLs with sex-dependent regulation of bone phenotypes. J Bone Miner Res. 2007;22(8):1187-1196.

[Downloaded from cofs.khuisf.ac.ir on 2026-11-26]

[DOI: 10.66224/cofs.4.1.5]

34. Xiong Q, Jiao Y, Hasty KA, Canale ST, Stuart JM, Beamer WG, et al. Quantitative trait loci, genes, and polymorphisms that regulate bone mineral density in mouse. Genomics. 2009;93(5):401-414.
35. Mark H, Rydevik B. Torsional stiffness in healing fractures: influence of ossification: an experimental study in rats. Acta Orthop. 2005;76(3):428-433.
36. Mark H, Bergholm J, Nilsson A, Rydevik B, Strömberg L. An external fixation method and device to study fracture healing in rats. Acta Orthop Scand. 2003;74(4):476-482.
37. Meyer MH, Meyer RA. Genes with greater up-regulation in the fracture callus of older rats with delayed healing. J Orthop Res. 2007;25(4):488-494.
38. Naik AA, Xie C, Zuscik MJ, Kingsley P, Schwarz EM, Awad H, et al. Reduced COX-2 expression in aged mice is associated with impaired fracture healing. J Bone Miner Res. 2009;24(2):251-264.
39. Fleming JE, Cornell CN, Muschler GF. Bone cells and matrices in orthopedic tissue engineering. Orthop Clin North Am. 2000;31(3):357-374.
40. Hachemi Y, Rapp AE, Picke AK, Weidinger G, Ignatius A, Tuckermann J. Molecular mechanisms of glucocorticoids on skeleton and bone regeneration after fracture. J Mol Endocrinol. 2018;61(1):R75-R90.
41. Sandberg OH, Aspenberg P. Glucocorticoids inhibit shaft fracture healing but not metaphyseal bone regeneration under stable mechanical conditions. Bone Joint Res. 2015;4(10):170-175.
42. Wicke C, Halliday B, Allen D, Roche NS, Scheuenstuhl H, Spencer EM, et al. Effects of steroids and retinoids on wound healing. Arch Surg. 2000;135(11):1265-1270.

[Downloaded from cofs.khuisf.ac.ir on 2026-11-26]

[DOI: 10.66224/cofs.4.1.5]