



Dimensions and morphology of the alveolar bone in the anterior maxilla in patients with bone resorption: A CBCT assessment

Ali Mohammadi¹, Nasim Farkhani^{2*}, Azadeh Torkzadeh³, Fatemeh Jabbarpour⁴

Received: 2024-08-13/ Accepted: 2025-01-04 / First publication date: 2025-05-20

© The Author(s) 2025

Abstract

Background: This study aimed to assess the dimensions and morphology of the alveolar bone in the anterior maxilla in patients with bone resorption using cone-beam computed tomography (CBCT).

Materials and Methods: In this cross-sectional study, alveolar bone thickness, magnitude of bone loss, depth and position of buccal undercuts, buccal fenestrations, the angle between the longitudinal axis of the teeth and alveolar bone, and apical bone height in the anterior maxilla were measured on CBCT scans of 72 patients with bone resorption. Statistical analyses were performed using a within-subjects ANOVA, the Bonferroni test, and the Chi-square test ($\alpha = 0.05$).

Results: The prevalence of mild bone resorption was the highest for all teeth. The undercut depth was the highest for the right canine, followed by the right lateral incisor. Significant differences were found in the mean bone loss in both the buccal ($P=0.021$) and palatal ($P<0.001$) surfaces, residual bone thickness at some sites ($P<0.001$), angulation ($P<0.001$), apical bone height ($P<0.001$), presence/absence of undercuts ($P=0.006$), and fenestration ($P<0.001$) among the six maxillary anterior teeth.

Conclusion: The results revealed differences in the magnitude and severity of bone resorption, residual bone thickness, fenestration, undercuts, angulation of longitudinal tooth axis, and apical bone height among maxillary central and lateral incisors and canine teeth on CBCT scans of patients with bone resorption, which should be taken into account in treatment planning.

Keywords: Alveolar Bone Loss; Cone-Beam Computed Tomography; Maxilla

Introduction

The anterior maxilla is the most challenging region for prosthodontic and implant treatments following tooth loss, due to its importance in smile esthetics and facial attractiveness, as well as local risk factors that can influence outcomes (1).

Long-term osseointegration stability does not equate to dental implant treatment success in the anterior maxilla. Additionally, in conjunction with the existing

success criteria, achieving optimal aesthetics is challenging in this area. The high prevalence and severity of gingival recession in the labial and interproximal regions, which often occur after implant placement in this area, are particularly concerning (2). The mean annual magnitude of free gingival recession around single implants is reportedly 0.5 to 1 mm, and approximately 17% to 40% of patients experience a gingival recession of 1 mm or more (2,3).

Several factors influence gingival recession, including periodontal biotype and alveolar bone anatomy (4). Periodontal biotype can be divided into two groups: thin (scalloped) and thick (flat) (5). Patients with a thin and scalloped biotype are more susceptible to gingival recession, and the presence of a thick biotype is an

Corresponding author: Nasim Farkhani

Department of Periodontics, Faculty of Dentistry, Isf.e, Islamic Azad University, Isfahan, Iran
Email: nasimfarkhani@iau.ac.ir

¹ Faculty of Dentistry, Isf.e, Islamic Azad University, Isfahan, Iran

² Department of Periodontics, Faculty of Dentistry, Isf.e, Islamic Azad University, Isfahan, Iran

³ Department of Oral & Maxillofacial Radiology, Faculty of Dentistry, Isf.e, Islamic Azad University, Isfahan, Iran

⁴ Department of Periodontics, Faculty of Dentistry, Isf.e, Islamic Azad University, Isfahan, Iran

important factor in achieving excellent esthetic results in dental implant treatment (4,6).

It has been reported that thin bone contour is usually covered with thin soft tissue (7). In other words, the soft tissue contour follows the underlying bone anatomy; the alveolar bone supports the gingiva and has a significant effect on the peri-implant soft tissue esthetic appearance (8). The presence of interproximal papilla in the anterior region is another crucial factor in achieving aesthetically pleasing results. Its presence and preservation depend on the underlying interproximal bone and its height (9). The alveolar bone anatomy depends on several factors, including facial type, inclination of the anterior teeth, maxillary protrusion, and a history of periodontal disease, among others (10,11). Therefore, these parameters should be evaluated before dental implant placement in the anterior region.

In a healthy periodontium, the distance between the bone crest and the cemento-enamel junction is usually 1.9 to 2 mm at the molar site on bitewing or parallel periapical radiographs, and a change of >0.7 mm in this distance on parallel periapical radiographs indicates bone loss. Internal bone resorption results in thinning of the bone trabeculae, enlargement of the bone marrow space, and subsequent bone destruction, and reduction of bone height (12).

Horizontal bone loss is the most common form of bone loss in periodontal disease (13). Radiography is a valuable non-invasive tool for detecting bone loss, diagnosing periodontal disease, determining its prognosis, and evaluating treatment outcomes (14). Radiographic examination of changes in bone level in periodontal disease is mainly based on the appearance of the interdental septum (15). Conventional radiographic modalities are extensively used for this purpose. However, errors during film exposure and processing can significantly affect the results; also, image enhancement after processing is not possible

(16). Since the advent of digital radiography in 1970, it has extensively replaced conventional radiography (17).

Cone-beam computed tomography (CBCT) is a relatively novel three-dimensional imaging modality with extensive applications, particularly in implant dentistry and orthodontics (18).

The changes in alveolar bone are greater in the mandible than in the maxilla (19, 20). However, controversy exists regarding the magnitude of bone resorption in the anterior and posterior regions. Some authors reported greater bone loss at the molar site (21) while others claimed that the anterior region is more susceptible to ridge resorption following tooth extraction (22). A third group found no significant difference in the magnitude of ridge resorption following tooth extraction based on tooth type/location (23, 24).

Many patients requiring dental implants have lost their teeth due to a previous periodontal disease. Additionally, many patients require cosmetic dental treatments, such as correcting tooth form or closing diastemas, due to a previous periodontal disease. Therefore, assessing the alveolar bone morphology and dimensions in the anterior maxilla of periodontitis patients is imperative. Thus, this study aimed to assess the dimensions and morphology of the alveolar bone in the anterior maxilla in patients with bone resorption using CBCT.

Materials and Methods

This retrospective cross-sectional study was conducted on 72 CBCT scans retrieved from the archives of the Oral Radiology Department of the School of Dentistry, Islamic Azad University, Khorasgan, Isfahan. The study protocol was approved by the university's ethics committee (IR.IAU.KHUISF.REC.1402.210).

The sample size was calculated to be 72 according to a previous study by Zhang et al. (25), assuming $\alpha = 0.05$, a standard deviation of 0.4, and a maximum standard error of 23%, using the sample size calculation formula. The CBCT scans were selected by convenience sampling.

Eligibility criteria:

High-quality CBCT scans of systemically healthy patients with bone resorption, as well as the visualization of all respective parameters on the scans, were evaluated.

The CBCT scans of patients with cysts, tumors, and a history of previous orthodontic treatment, trauma, or surgery at the site that would affect bone quality were excluded. Presence of obvious malocclusion in the anterior maxillary teeth, such as moderate to severe overbite or overjet, and crowding, history of periodontal therapy, endodontic or restorative treatments in the maxillary anterior teeth, and invasive periodontitis were among other exclusion criteria. Since all patients were selected from those presenting to the university clinic, their medical and dental records were readily available, and the exclusion criteria could be easily identified from these records. Other criteria, such as invasive periodontitis, could be detected on their radiographs.

All CBCT scans were obtained using the Galileos CBCT scanner (Sirona, Bensheim, Germany) with exposure settings of 85 kV and 21-35 mA/s, depending on the patient's body size.

The following measurements were made on the CBCT scans in the anterior maxilla by a board-certified oral and maxillofacial radiologist:

Bone loss: It was quantified by measuring the distance between the cemento-enamel junction and the bone crest (Figure 1).

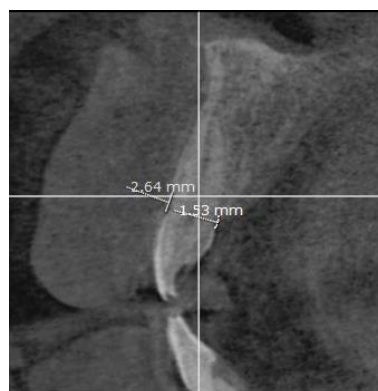


Figure 1. Magnitude of bone resorption in maxillary anterior teeth

The severity of bone resorption was categorized into the following three groups on CBCT scans:

Mild bone loss: Radiographic bone loss $< \frac{1}{3}$ of the root length

Moderate bone loss: Radiographic bone loss between $\frac{1}{3}$ to $\frac{1}{2}$ of the root length

Severe bone loss: Radiographic bone loss over $\frac{1}{2}$ of the root length (12).

Residual bone thickness:

It was measured at the coronal, middle, and apical areas as the sum of cortical and cancellous bones in the buccal and palatal surfaces (Figure 2).

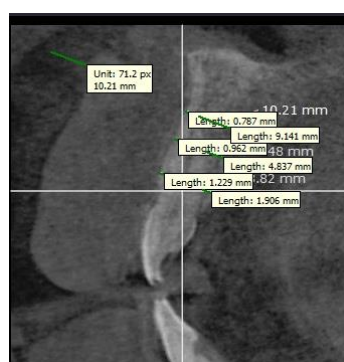


Figure 2. Residual bone thickness in maxillary anterior teeth

Undercuts: The location and depth of undercuts, if present (Figure 3).

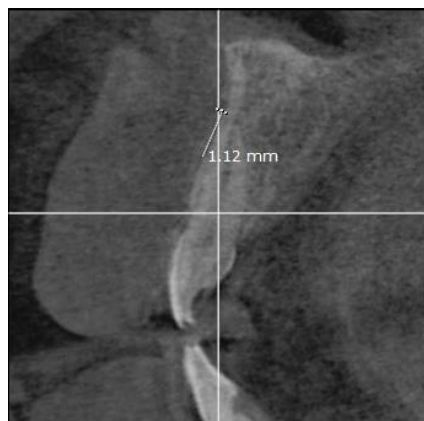


Figure 3. Undercut depth in maxillary anterior teeth

Angulation: The angle formed between the longitudinal tooth axis and the alveolar bone (Figure 4).

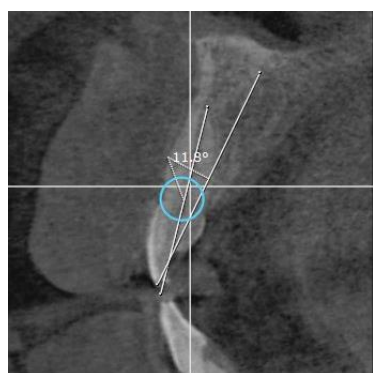


Figure 4. Angle formed between the longitudinal tooth axis and the alveolar bone in maxillary anterior teeth

Apical bone height: Distance between the tooth apex and the nasal cavity floor (Figure 5).

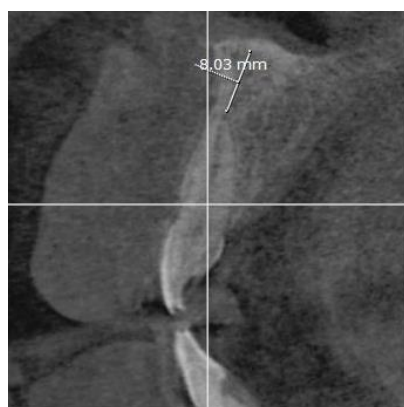


Figure 5. Apical bone height in maxillary anterior teeth

The normality of data distribution was confirmed by the Shapiro-Wilk test. Accordingly, ANOVA, the Bonferroni test, and Fisher's exact test were used to compare the data. All statistical analyses were conducted using SPSS version 26 (SPSS Inc., IL, USA) at a 0.05 level of significance.

Results

The CBCT scans of 72 patients were evaluated, comprising 32 males (44.4%) and 40 females (55.6%). The mean age was 45.38 ± 12.02 years (range, 24 to 71 years). Of all, 12.5% were under 30 years, 23.6% were between 31 and 40 years, 29.2% were between 41 and 50 years, 23.6% were between 51 and 60 years, and 11.1% were over 60 years of age.

Severity of bone resorption:

Table 1 presents the frequency distribution of bone resorption severity among the maxillary anterior teeth. Across all maxillary anterior teeth, mild bone resorption was the most prevalent severity category. Chi-square analysis confirmed that mild resorption was significantly more common than severe resorption for all teeth ($P < 0.001$). In most teeth, mild resorption was also considerably more common than moderate resorption ($P < 0.05$), except for the left central and lateral incisors, where no significant difference was observed ($P = 0.112$ and $P = 0.696$, respectively).

Table 1. Frequency distribution of bone loss severity in maxillary anterior teeth

Tooth	Severity	Frequency	Percentage	P-value*	Bone loss	P-value*
Right canine	Mild	46	68.7	< 0.001	Mild - Moderate	< 0.001
	Moderate	19	28.4		Mild - Severe	< 0.001
	Severe	2	3		Moderate - Severe	< 0.001
Right lateral incisor	Mild	39	60.9	< 0.001	Mild - Moderate	0.059
	Moderate	24	37.5		Mild - Severe	< 0.001
	Severe	1	1.6		Moderate - Severe	< 0.001
Right central incisor	Mild	51	70.8	< 0.001	Mild - Moderate	< 0.001
	Moderate	19	26.4		Mild - Severe	< 0.001
	Severe	2	2.8		Moderate - Severe	< 0.001
Left central incisor	Mild	40	56.3	< 0.001	Mild - Moderate	0.112
	Moderate	27	38		Mild - Severe	< 0.001
	Severe	4	5.6		Moderate - Severe	< 0.001
Left lateral incisor	Mild	31	48.4	< 0.001	Mild - Moderate	0.696
	Moderate	28	43.8		Mild - Severe	< 0.001
	Severe	5	7.8		Moderate - Severe	< 0.001
Left canine	Mild	45	77.6	< 0.001	Mild - Moderate	< 0.001
	Moderate	13	22.4		Mild - Severe	< 0.001
	Severe	0	0		Moderate - Severe	< 0.001

*Chi-square test

Undercut depth:

Figure 6 shows the undercut depth for the maxillary anterior teeth. As shown, the undercut depth was the highest for the right canine, followed by the right lateral incisor.

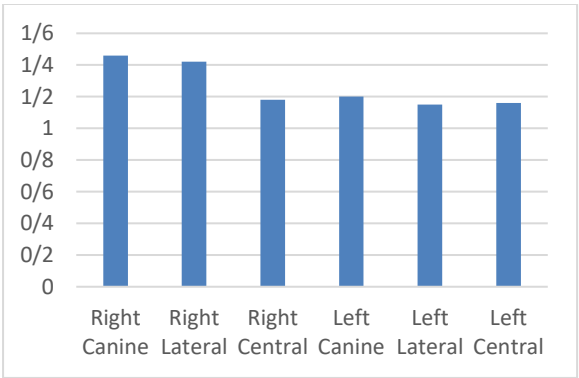


Figure 6. Mean undercut depth in the maxillary anterior teeth

Mean bone loss:

Table 2 shows the mean bone loss in the buccal and palatal surfaces of the maxillary anterior teeth. Within-

subjects ANOVA revealed significant differences in the mean bone loss among the anterior teeth in both the buccal ($P=0.021$) and palatal ($P<0.001$) surfaces. In the buccal surface, the mean bone loss was significantly higher in the right canine than the right lateral ($P=0.043$) and central ($P=0.030$) incisors. No other significant differences were found in pairwise comparisons using the Bonferroni test ($P > 0.05$). In the palatal surface, the mean bone loss was significantly higher in the right canine than the left central incisor ($P=0.025$). The mean bone loss in the left central incisor was markedly lower than that in the left canine ($P=0.002$), and the mean bone loss in the left lateral incisor was significantly lower than that in the left canine ($P=0.040$). No other significant differences were found in pairwise comparisons using the Bonferroni test ($P > 0.05$).

Table 2. Mean bone loss in the buccal and palatal surfaces of the maxillary anterior teeth (in millimetres)

Tooth	Buccal	Palatal
	Mean ± SD	Mean ± Sd
Right canine	3.8 ± 1.11	3.63 ± 0.99
Right lateral incisor	3.41 ± 0.8	2.93 ± 0.81
Right central incisor	3.38 ± 1.05	3.28 ± 0.97
Left central incisor	3.45 ± 1.09	3.14 ± 1.1
Left lateral incisor	3.8 ± 1.03	3.37 ± 0.85
Left canine	3.78 ± 1.1	3.63 ± 1.05
P value	0.021	< 0.001

Residual bone thickness:

Table 3 shows the mean residual bone thickness in the buccal and palatal surfaces at the coronal, middle, and apical thirds of the maxillary anterior teeth. Within-subjects ANOVA revealed significant differences in the mean residual bone thickness among the six maxillary anterior teeth in the coronal third in the buccal surface ($P<0.001$), middle third in the palatal surface ($P<0.001$), and apical third in the palatal surface ($P<0.001$).

Pairwise comparisons of the mean residual bone thickness of the six teeth in the coronal third of the buccal surface revealed that the mean residual bone thickness at this site was significantly higher in the right canine than the right lateral incisor ($P=0.038$) and left lateral incisor ($P=0.040$). Also, it was substantially lower in the left lateral incisor than the left canine ($P=0.011$). No other significant differences were

found in pairwise comparisons using the Bonferroni test ($P > 0.05$).

Pairwise comparisons of the mean residual bone thickness of the six teeth in the middle third of the palatal surface revealed that the mean residual bone thickness at this site was significantly greater in the right canine than the right lateral incisor ($P=0.005$). It was substantially lower in the right lateral incisor than the left canine ($P<0.001$), in the left central incisor than the left canine ($P=0.002$), and in the left lateral incisor than the left canine ($P<0.001$). No other significant differences were found in pairwise comparisons using the Bonferroni test ($P > 0.05$).

Pairwise comparisons of the mean residual bone thickness of the six teeth in the apical third of the palatal surface revealed that the mean residual bone thickness at this site was significantly greater in the right canine than the right lateral incisor ($P<0.001$), left central incisor ($P=0.004$), and left lateral incisor ($P<0.001$). It was significantly lower in the right lateral incisor than the right central incisor ($P<0.001$), left central incisor ($P = 0.008$), and left canine ($P<0.001$). The mean residual bone thickness at this site in the right central incisor was significantly higher than that in the left lateral incisor ($P=0.023$) and significantly lower than that in the left canine ($P<0.001$). This value in the left central incisor was considerably lower than that in the left canine ($P<0.001$). It was also significantly lower in the left lateral incisor than the left canine ($P<0.001$). No other significant differences were found in pairwise comparisons using the Bonferroni test ($P > 0.05$).

Table 3. Mean residual bone thickness in the buccal and palatal surfaces at the coronal, middle, and apical thirds of the maxillary anterior teeth (in millimeters)

Tooth	Coronal third		Middle third		Apical third	
	Buccal	Palatal	Buccal	Palatal	Buccal	Palatal
	Mean \pm SD	Mean \pm SD	Mean \pm SD	Mean \pm SD	Mean \pm SD	Mean \pm SD
Right canine	1.23 \pm 0.3	1.46 \pm 0.42	0.97 \pm 0.45	3.11 \pm 0.94	1 \pm 0.38	6.3 \pm 1.41
Right lateral incisor	1.04 \pm 0.22	1.48 \pm 0.62	0.94 \pm 0.32	2.6 \pm 0.8	0.98 \pm 0.47	4.64 \pm 1.14
Right central incisor	1.09 \pm 0.3	1.7 \pm 0.56	1.01 \pm 0.31	2.83 \pm 1.11	0.92 \pm 0.36	5.38 \pm 1.42
Left central incisor	1.1 \pm 0.26	1.52 \pm 0.69	0.91 \pm 0.29	2.81 \pm 0.95	0.94 \pm 0.56	5.36 \pm 1.49
Left lateral incisor	1.07 \pm 0.33	1.44 \pm 0.56	0.93 \pm 0.48	2.54 \pm 0.87	1.06 \pm 1.08	4.5 \pm 1.42
Left canine	1.19 \pm 0.3	1.42 \pm 0.48	0.96 \pm 0.44	3.04 \pm 0.94	0.91 \pm 0.38	6.43 \pm 1.48
P Value	0.001	0.084	0.526	< 0.001	0.145	< 0.001

SD: Standard deviation

Angulation:

The mean angulation of maxillary anterior teeth is shown in Table 4. The difference in this regard was significant among the teeth, as demonstrated by the Bonferroni test ($P < 0.001$). Pairwise comparisons indicated that the mean angulation of the right lateral incisor was significantly lower than that of the left lateral incisor ($P=0.041$) and the left canine ($P<0.001$). The mean angulation of the right central incisor was significantly lower than that of the left lateral incisor ($P=0.022$) and left canine ($P=0.003$). No other significant differences were found in pairwise comparisons using the Bonferroni test ($P > 0.05$).

Apical bone height:

Table 4 also shows the mean apical bone height. The difference in this parameter was also significant among the six anterior teeth, as demonstrated by the Bonferroni test ($P < 0.001$). Pairwise comparisons showed that the mean apical bone height in the right canine was significantly lower than that in all other teeth ($P<0.001$ for all) except for the left canine ($P=1.00$). This parameter in the right lateral incisor was significantly higher than that in the left lateral incisor ($P=0.012$) and left canine ($P<0.001$). The right

central incisor showed significantly higher apical bone height than the left canine ($P=0.002$). This value in the left central incisor was significantly higher than that in the left canine ($P<0.001$). It was considerably higher in the left lateral incisor than the left canine ($P = 0.001$). No other significant differences were found in pairwise comparisons using the Bonferroni test ($P > 0.05$).

Table 4. Mean angulation (in degrees) and residual bone height (in millimetres) of maxillary anterior teeth

Tooth	Angulation (degrees)	Residual bone height
	Mean \pm SD	Mean \pm SD
Right canine	16.19 \pm 6.6	6.9 \pm 1.99
Right lateral incisor	15.15 \pm 6.83	8.72 \pm 2.15
Right central incisor	13.49 \pm 4.29	8.35 \pm 2.37
Left central incisor	14.48 \pm 3.86	8.89 \pm 2.49
Left lateral incisor	16.07 \pm 5.78	8.38 \pm 2.15
Left canine	16.04 \pm 3.85	6.84 \pm 1.72
P value	< 0.001	< 0.001

Presence of undercuts and fenestration:

Table 5 shows the presence or absence of undercuts and fenestration in the apical and middle thirds of the six maxillary anterior teeth. Fisher's exact test revealed

significant overall differences in both undercuts ($P = 0.006$) and fenestration ($P < 0.001$). Pairwise comparisons by the Chi-square test showed that the right lateral incisor exhibited significantly more apical undercuts compared to the right and left central incisors, and the left canine ($P<0.05$). Similarly, the right canine had significantly more apical undercuts than the right lateral incisor ($P=0.007$). For fenestration, the right central incisor showed significantly lower frequency compared to the right canine, right lateral incisor, and left canine ($P < 0.05$), indicating that these differences were not evenly distributed among the teeth. Additionally, a significant difference existed in the specific location of fenestration among different teeth (Table 6; $P < 0.001$).

Table 5. Frequency distribution of presence/absence of undercuts and fenestration in the apical and middle thirds of the six maxillary anterior teeth

Variable	Right canine	Right lateral incisor	Right central incisor	Left central incisor	Left lateral incisor	Left canine
	N (%)	N (%)	N (%)	N (%)	N (%)	N (%)
No undercuts	59 (85.5)	44 (67.7)	64 (88.9)	64 (99.4)	48 (77.4)	50 (87.7)
Undercuts in the apical third	7 (10.1)	19 (29.2)	4 (55.6)	4 (55.7)	11 (17.7)	5 (88.8)
Undercuts in the middle third	3 (4.3)	2 (3.1)	4 (5.6)	2 (2.9)	3 (4.8)	2 (33.5)
Fenestration	35 (50.7)	20 (30.8)	8 (11.1)	20 (28.6)	16 (25.8)	24 (42.1)

Table 6. Frequency distribution of the location of fenestration in maxillary anterior teeth

Location	Right canine	Right lateral incisor	Right central incisor	Left central incisor	Left lateral incisor	Left canine
	N (%)	N (%)	N (%)	N (%)	N (%)	N (%)
Apical third	30 (85.7%)	19(95.0%)	8(100.0%)	18(90.0%)	7(43.80%)	26(100.0%)
Middle third	2(5.7%)	1(5.0%)	0(0.0%)	0(0.0%)	0(0.0%)	0(0.0%)
Both apical and middle thirds	3(8.6%)	0(0.0%)	0(0.0%)	2(10.0%)	9(56.3%)	0(0.0%)

Discussion

This study assessed the dimensions and morphology of the alveolar bone in the anterior maxilla in patients with bone resorption using CBCT. The results showed that the prevalence of mild bone resorption was the highest for all teeth. The undercut depth was the highest for the right canine, followed by the right lateral incisor. Significant differences were found in the mean bone loss in both the buccal and palatal

surfaces, residual bone thickness at some sites, angulation, apical bone height, presence/absence of undercuts, and fenestration among the six maxillary anterior teeth. Zhang et al. (25) utilized CBCT to evaluate bone loss in relation to tooth type, age, and gender, and reported an increase in apical bone height following tooth loss and aging. The sagittal position of the teeth changed with bone loss, and tooth movements were greater in

the anterior teeth. The alveolar bone morphology in the anterior maxilla differed between patients with and without periodontitis, and these differences were correlated with bone loss, tooth type, age, and gender. Their results regarding bone morphology of the anterior maxilla were in line with the present findings. Sheerah et al. (26) measured alveolar bone thickness in the anterior maxilla using CBCT and found significant differences in alveolar bone length and thickness among patients.

Additionally, bone thickness was significantly correlated with age and gender. Zasčiurinskienė et al. (27) evaluated alveolar bone changes in the maxilla of periodontal and orthodontic patients using CBCT and found slight changes in these patients. They reported some changes in alveolar bone level at the mesial and distal aspects, as well as bone loss at the buccal and lingual aspects. They concluded that orthodontic movement of maxillary incisors can further contribute to a reduction in alveolar bone thickness in this region. Zhang et al. (28) evaluated alveolar bone morphology and dimensions on CBCT scans for immediate dental implant treatment in American adults aged 18–65 years, and reported significant changes in alveolar bone thickness among the maxillary anterior teeth, such that lateral incisors had the lowest bone thickness, which was in line with the present findings. Zhao et al. (29) assessed the alveolar bone status in a middle-aged Chinese population (40–59 years) using CBCT and found significant differences in alveolar bone thickness based on tooth type and location. Patients with chronic periodontitis experienced the highest bone loss on the lingual surface of the incisors and the buccal and lingual surfaces of the molar teeth. Zhou et al. (30) reported very low alveolar bone thickness in the anterior maxilla of Chinese adults aged 20–55 years. Bone thickness was lower at the site of the central incisors with high lingual curvature.

In the present study, canine teeth exhibited the highest frequency of mild bone loss, while lateral incisors showed the highest frequency of moderate and severe bone loss, and central incisors had the highest prevalence of mild and moderate bone loss. Canines showed the highest bone resorption bilaterally, while bone resorption was the lowest in central incisors. Additionally, in all three tooth types, the buccal surface exhibited higher resorption than the lingual surface, which may be attributed to the greater mechanical force and tension applied at this site. Bone thickness at the palatal surface was greater than at the buccal surface in all teeth. Canine teeth usually have greater bone thickness in the apical third of their palatal surface, while lateral incisors often have the lowest bone thickness, especially in the palatal surface. These results were in line with the findings of Sheerah et al (26) and Zhang et al (28).

Lateral incisors exhibited a higher frequency of undercuts and seem to be more vulnerable to injury, especially in the apical third. Canine teeth generally have the deepest undercuts due to the prominence of bone in this region. The rate of fenestration also varied among the teeth. Lateral incisors have the highest risk of fenestration, while central incisors have the lowest. Canine teeth and central incisors showed the highest frequency of fenestration in the apical third, whereas lateral incisors exhibited the highest fenestration in both the apical and middle thirds; therefore, implants with smaller diameters should be considered when replacing lateral incisors. This is also relevant in orthodontic treatment. In a study by Braut et al. (1), conducted on **Swiss adults aged 18–65 years**, the buccal plate was absent at the crestal level in 25.7% of the teeth and at the mid-root in 10%, with an approximate fenestration risk of 12.6% in this study. Canine teeth had the highest, and central incisors had the lowest angulation in the present study. In the study by Zhou et al. (30), this angle was greater for central

incisors due to racial differences and the evaluation of Chinese adults only, as aging has a greater effect on the angulation of central incisors compared with canine teeth.

Apical bone height was greater in central and lateral incisors than in canine teeth in the current study. A longer root of the canine can lead to a reduction in apical bone height, which complicates fresh socket implantation. Zhang et al. (25) reported that aging and tooth loss increased the apical bone height.

Retrospective design and evaluation of CBCT scans alone with no clinical examination were the main limitations of this study. Future studies are needed to investigate the long-term effects of bone loss, its risk factors, and its relationship with systemic diseases.

Conclusion

The results revealed differences in the magnitude and severity of bone resorption, residual bone thickness, fenestration, undercuts, angulation of longitudinal tooth axis, and apical bone height among maxillary central and lateral incisors and canine teeth on CBCT scans of patients with bone resorption, which should be taken into account in treatment planning.

Conflict of Interests: The authors of this manuscript declare that they have no conflicts of interest, real or perceived, financial, or non-financial in this article

References

1. Braut V, Bornstein MM, Belser U, Buser D. Thickness of the anterior maxillary facial bone wall-a retrospective radiographic study using cone beam computed tomography. *Int J Periodontics Restorative Dent*. 2011;31(2):125-131.
2. Evans CD, Chen ST. Esthetic outcomes of immediate implant placements. *Clin Oral Implants Res*. 2008;19(1):73-80.
3. Jemt T, Ahlberg G, Henriksson K, Bondevik O. Changes of anterior clinical crown height in patients provided with single-implant restorations after more than 15 years of follow-up. *Int J Prosthodont*. 2006;19(5):455-461.
4. Kan JY, Rungcharassaeng K, Umezu K, Kois JC. Dimensions of peri-implant mucosa: an evaluation of maxillary anterior single implants in humans. *J Periodontol*. 2003;74(4):557-562.
5. Seibert J, Lindhe J. Esthetics and periodontal therapy. In: Lindhe J, ed. *Textbook of Clinical Periodontology*. Copenhagen: Munksgaard; 1989: 477-514.
6. Claffey N, Shanley D. Relationship of gingival thickness and bleeding to loss of probing attachment in shallow sites following nonsurgical periodontal therapy. *J Clin Periodontol*. 1986;13(7):654-657.
7. Ochsenbein C, Ross S. A reevaluation of osseous surgery. *Dent Clin North Am*. 1969;13(1):87-102.
8. Buser D, Martin W, Belser UC. Optimizing esthetics for implant restorations in the anterior maxilla: anatomic and surgical considerations. *Int J Oral Maxillofac Implants*. 2004;19 Suppl:43-61.
9. Gracco A, Lombardo L, Mancuso G, Gravina V, Siciliani G. Upper incisor position and bony support in untreated patients as seen on CBCT. *Angle Orthod*. 2009;79(4):692-702.
10. Yu Q, Pan XG, Ji GP, Shen G. The association between lower incisal inclination and morphology of the supporting alveolar bone--a cone-beam CT study. *Int J Oral Sci*. 2009;1(4):217-223.
11. Spear FM. Maintenance of the interdental papilla following anterior tooth removal. *Pract Periodontics Aesthet Dent*. 1999;11(1):21-30.
12. Armitage GC. Clinical evaluation of periodontal diseases. *Periodontol 2000*. 1995;7:39-53.
13. Hausmann E. Radiographic and digital imaging in periodontal practice. *J Periodontol*. 2000;71(3):497-503.
14. Armitage GC, Svanberg GK, Loe H. Microscopic evaluation of clinical measurements of connective tissue attachment levels. *J Clin Periodontol*. 1977;4(3):173-190.
15. Naito T, Hosokawa R, Yokota M. Three-dimensional alveolar bone morphology analysis using computed tomography. *J Periodontol*. 1998;69(5):584-589.
16. Mallya SM, Lam EWN. *White and Pharaoh's oral radiology: principles and interpretation*. 8th ed. St. Louis: Elsevier, 2019. P: 41-333
17. Christgau M, Hiller KA, Schmalz G, Kolbeck C, Wenzel A. Accuracy of quantitative digital subtraction radiography for determining changes in calcium mass in mandibular bone: an in vitro study. *J Periodontol Res*. 1998;33(3):138-149.
18. Javidi M, Shoja Razavi A, Esmaili H. A comparison between conventional and digital radiography in estimating the working length of root canal. *Journal of Dentistry*. Mashhad University of Medical Sciences. 2006; 30(1, 2):33-40.
19. Moya-Villaescusa MJ, Sánchez-Pérez A. Measurement of ridge alterations following tooth removal: a radiographic study in humans. *Clin Oral Implants Res*. 2010;21(2):237-242.

20. Bodic F, Hamel L, Lerouxel E, Baslé MF, Chappard D. Bone loss and teeth. *Joint Bone Spine*. 2005;72(3):215-221.
21. Covani U, Ricci M, Bozzolo G, Mangano F, Zini A, Barone A. Analysis of the pattern of the alveolar ridge remodelling following single tooth extraction. *Clin Oral Implants Res*. 2011;22(8):820-825.
22. Vera C, De Kok IJ, Reinhold D, et al. Evaluation of buccal alveolar bone dimension of maxillary anterior and premolar teeth: a cone beam computed tomography investigation. *Int J Oral Maxillofac Implants*. 2012;27(6):1514-1519.
23. Schropp L, Wenzel A, Kostopoulos L, Karring T. Bone healing and soft tissue contour changes following single-tooth extraction: a clinical and radiographic 12-month prospective study. *Int J Periodontics Restorative Dent*. 2003;23(4):313-323.
24. Thalmair T, Fickl S, Schneider D, Hinze M, Wachtel H. Dimensional alterations of extraction sites after different alveolar ridge preservation techniques - a volumetric study. *J Clin Periodontol*. 2013;40(7):721-727.
25. Zhang X, Li Y, Ge Z, Zhao H, Miao L, Pan Y. The dimension and morphology of alveolar bone at maxillary anterior teeth in periodontitis: a retrospective analysis-using CBCT. *Int J Oral Sci*. 2020; 12(1):4.
26. Sheerah H, Othman B, Jaafar A, Alsharif A. Alveolar bone plate measurements of maxillary anterior teeth: A retrospective Cone Beam Computed Tomography study, AlMadianh, Saudi Arabia. *Saudi Dent J*. 2019;31(4):437-444.
27. Zasčiurinskienė E, Lund H, Lindsten R, Jansson H, Bjerklin K. Outcome of periodontal-orthodontic treatment in subjects with periodontal disease. Part II: a CBCT study of alveolar bone level changes. *Eur J Orthod*. 2019;41(6):565-574.
28. Zhang W, Skrypczak A, Weltman R. Anterior maxilla alveolar ridge dimension and morphology measurement by cone beam computerized tomography (CBCT) for immediate implant treatment planning. *BMC Oral Health*. 2015;15:65
29. Zhao H, Li C, Lin L, Pan Y, Wang H, Zhao J, et al. Assessment of Alveolar Bone Status in Middle Aged Chinese (40-59 Years) with Chronic Periodontitis--Using CBCT. *PLoS One*. 2015;10(10):e0139553.
30. Zhou Z, Chen W, Shen M, Sun C, Li J, Chen N. Cone beam computed tomographic analyses of alveolar bone anatomy at the maxillary anterior region in Chinese adults. *J Biomed Res*. 2014;28(6):498-505.