



ORIGINAL RESEARCH



## Comparison of external apical root resorption in maxillary incisors subsequent to fixed orthodontic treatment among late adolescents, young adults, and middle-aged adults

Fatemeh sadat Dehghani<sup>1</sup>, Mehdi Rafiei<sup>2\*</sup>, Parisa Ranjbarian<sup>3</sup>, Pegah Shayestehmehr<sup>4</sup>

Received: 2024-08-13/ Accepted: 2024-11-10 / First publication date: 2025-03-05

© The Author(s) 2025

### Abstract

**Background:** External apical root resorption (EARR) is a common iatrogenic complication following orthodontic treatment. Due to the increasing demand for orthodontic treatment among adults, there has been a rise in the number of middle-aged patients. This study aimed to assess the prevalence of EARR in these patients in comparison to younger patients.

**Materials and Methods:** This cross-sectional retrospective analytical study was performed on panoramic radiographs taken before and one year after the initiation of orthodontic treatment in 78 patients in three age groups. The first group consisted of 28 patients aged 17-25 years (adolescents), the second group consisted of 28 patients aged 25-35 years (younger adults), and the third group consisted of 22 patients aged 40-50 years (middle aged). The outline of the maxillary incisors was traced onto acetate sheets from panoramic radiographs and compared. The collected data was analyzed using Kruskal-Wallis, Mann-Whitney, and Wilcoxon ( $\alpha=0.05$ ).

**Results:** The mean EARR in the adolescents, younger adults, and middle-aged groups showed no significant difference in the right central ( $P=0.322$ ) and left central ( $P=0.289$ ) incisors. No significant difference was seen in the right lateral ( $P=0.358$ ) and left lateral ( $P=0.739$ ) incisors. The average amount of external root resorption in the upper incisors was similar in men and women ( $P>0.05$ ). Also, there was no significant difference between the two treatment methods in the right central ( $P=0.232$ ), left central ( $P=0.204$ ), right lateral ( $P=0.204$ ), and left lateral ( $P=0.882$ ) incisors.

**Conclusion:** The mean EARR was similar between studied groups. External apical root resorption did not show correlation with age and gender.

**Keywords:** root resorption, Maxillary incisor, Orthodontic treatment, Tooth movement.

### Introduction

Orthodontic treatment is performed to restore proper occlusion, improve chewing function, and enhance facial aesthetics. However, like any other dental

intervention, this treatment carries potential risks and complications in addition to its benefits. The most common side effects of orthodontic treatment include root resorption, tooth discoloration, decalcification, and periodontal complications. The force during orthodontic treatment inevitably causes an inflammatory process that is the main cause of root resorption (1). Orthodontic forces exerted on the teeth can lead to the development of initial resorption lacunae on the surface of the cementum. This process which represents the earliest stage of dental resorption, can occur within a brief period, signaling the onset of resorption in response to the applied mechanical pressure. If trauma doesn't occur, the cementum

**Corresponding author: Dr Mehdi Rafiei**

Department of orthodontics, Faculty of Dentistry, Isfahan (Khorasgan) Branch, Islamic Azad University, Isfahan, Iran  
Email: mehdi.rafiee@khuif.ac.ir

<sup>1</sup> Faculty of Dentistry, Isfahan (Khorasgan) Branch, Islamic Azad University, Isfahan, Iran

<sup>2</sup> Department of orthodontics, Faculty of Dentistry, Isfahan (Khorasgan) Branch, Islamic Azad University, Isfahan, Iran

<sup>3</sup> Department of endodontics, Faculty of Dentistry, Isfahan (Khorasgan) Branch, Islamic Azad University, Isfahan, Iran

<sup>4</sup> Department of orthodontics, Faculty of Dentistry, Isfahan (Khorasgan) Branch, Islamic Azad University, Isfahan, Iran

repairs the damage within 2 to 3 weeks. When resorption exceeds the resistance and capacity of cementum regeneration, it becomes visible (2).

External apical root resorption has been classified into three categories based on the extent of root structure loss (3): Mild: External apical root resorption is less than 2 mm of the root length. Moderate: External apical root resorption is more than 2 mm but less than one-third of the root length. Severe: External apical root resorption is more than 4 mm or one-third of the root length.

Root resorption can jeopardize the stability of orthodontic treatment and pulp vitality (2). When the apical root resorption extends to the pulp, these irreversible changes can lead to tooth loss and compromise the benefits of orthodontic treatment (1, 4). By identifying the risk factors in advance, therapists can accurately predict the occurrence, location, and extent of root resorption before starting orthodontic treatment. The appearance of anterior teeth is the main driver for adults seeking orthodontic treatment (5), and this has led to an increase in demand for such treatment (6). With the gradual increase in adult orthodontic patients, the number of middle-aged and older patients is also increasing proportionally. Older individuals are more prone to chronic periodontal diseases and root resorption (7). In Nanekrungsan et al.'s study (4), treatment with premolar extraction was a significant factor in external apical root resorption, and age at the start of treatment was also related to root resorption. In the study by Han et al. (8), the average root resorption was found to be 1.0 mm in middle-aged adults and 6.0 mm in young adults. The extent of root resorption was comparable between the two groups regarding the complexity of treatment and the duration of treatment. Therefore, this study aims to investigate and compare the extent of external apical root resorption after orthodontic treatment in three age groups: late adolescents (17-25 years old), younger adults (25-35 years old), and middle-aged adults (40-50 years old), and to examine the relationship between root resorption analysis and patients' chronological age.

### Materials and Methods

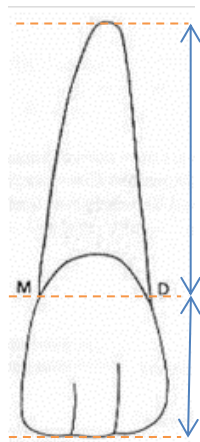
In this retrospective cross-sectional analytical study, 78 patients were examined based on purposive sampling and divided into three groups. In this study, archived data were utilized, obtained from panoramic radiographs of patients who had previously consented to treatment and were referred to the orthodontic

department at the dental school of Islamic Azad University in Isfahan (Khorasgan) This research was conducted in accordance with the guidelines established by the Ethics Committee of Islamic Azad University, Isfahan (Khorasgan), and was assigned the ethics ID IR.IAU.KHUISF.REC.1400.111.

For evaluating and comparing external apical root resorption after orthodontic treatment, the maxillary incisors were studied in three groups according to the patient's age. The first group (adolescents) comprised 28 patients (12 males and 16 females) with an age range of 17 to 25. The second group (younger adults) consisted of 28 patients (6 males and 22 females) aged between 25 and 35 years. The third group (middle-aged) included 22 patients (7 males and 15 females) with ages ranging from 40 to 50 years.

The study included patients who had undergone active orthodontic treatment (extraction or non-extraction method), had panoramic radiographs one year after the initiation of treatment (9), were over 17 years old, and had a high-quality, minimally distorted panoramic radiographs before and one year after the start of treatment. The exclusion criteria included individuals with systemic diseases (such as diabetes, osteoarthritis, and hyperthyroidism), cleft lip and palate, as well as those with a history of trauma, periodontal disease, previous orthognathic surgery or orthodontic, bruxism, immature incisors, impacted canines, and teeth with severe root curvature. A final-year dental student, trained by an endodontist, traced the outlines of the maxillary incisor teeth on tracing paper from the panoramic radiograph. All digital radiographs were taken with one device (Vatech PCH-2500, kVp 72, ma 10, Korea, software: easy Dent viewer). Although periapical radiographs are a more appropriate option for analyzing apical root resorption in anterior teeth, panoramic radiographs were used in this study due to the lack of need for treatment and ethical issues considering the least difference between periapical radiographs and panoramic radiographs in the maxillary incisors than the other teeth for analyzing apical root resorption (10)

The line connecting the mesial and distal CEJ of the tooth under consideration is called MD. The crown height and root length were defined as shown in Figure 1. The distance from the apex of the root to the MD line was considered the root length, and the distance from the incisal edge of the corresponding tooth to the MD line was considered the crown height, as shown in Figure 1.



**Figure 1:** crown height to root length ratio

The ratio of crown height to root length in the incisors before treatment of the patient in late adolescence, younger adulthood, and middle- aged was denoted as X1, X2, and X3, respectively, in tracing of the first radiograph. Similarly, the ratio at least one year after treatment of the patient in late adolescence, young adulthood, and middle age was denoted as Y1, Y2, and Y3, respectively, in tracing the second radiograph. The

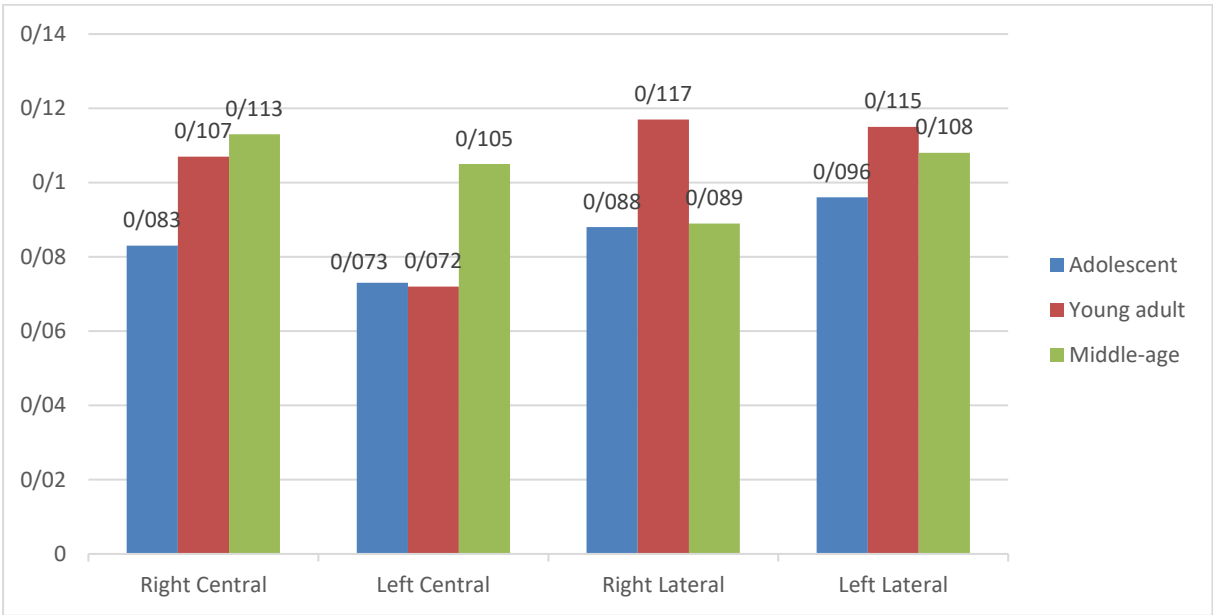
changes in X1 compared to Y1 were denoted as Z1, the changes in X2 compared to Y2 were denoted as Z2, and the changes in X3 compared to Y3 were denoted as Z3. Then, the average of Z1, Z2, and Z3 was recorded in SPSS version 26 and compared at a 95% significance level. The collected data was analyzed using Kruskal-Wallis, Mann-Whitney U, and Wilcoxon.

**Results**

As descriptive analysis shown in table 1 and 2, the highest mean of root resorption in younger adults was observed in lateral teeth, and the highest mean of root resorption in middle aged group was observed in central teeth. The highest mean of root resorption in the extraction group was observed in the right lateral incisors, whilst the highest mean of root resorption in the non-extraction group was observed in the left lateral incisors (table 1 and Figure 1). The mean of root resorption was higher in men than women in the right lateral and central teeth (table 2), however, further inferential analysis using the Mann-Whitney test showed that the difference was not statistically significant ( $P > 0.05$ ).

**Table1.** Descriptive analysis of root resorption in maxillary central and lateral incisors by treatment and age group

Variable	Treatment	Age	NO	Mean $\pm$ SD	Min.	Max.
Right Lateral	Ext	Adolescent	14	0.088 $\pm$ 0.055	0.010	0.18
		Young adult	21	0.129 $\pm$ 0.079	0.01	0.27
		Middle-aged	5	0.098 $\pm$ 0.110	0.00	0.27
Right Central	Ext	Adolescent	14	0.101 $\pm$ 0.075	0.00	0.25
		Young adult	20	0.112 $\pm$ 0.096	0.00	0.29
		Middle-aged	6	0.115 $\pm$ 0.061	0.04	0.17
Left Central	Ext	Adolescent	15	0.084 $\pm$ 0.041	0.02	0.16
		Young adult	18	0.084 $\pm$ 0.078	0.00	0.29
		Middle-aged	7	0.101 $\pm$ 0.063	0.04	0.23
Left Lateral	Ext	Adolescent	15	0.103 $\pm$ 0.069	0.01	0.24
		Young adult	18	0.112 $\pm$ 0.103	0.00	0.35
		Middle-aged	6	0.079 $\pm$ 0.065	0.01	0.20
Right Lateral	Non-Ext	Adolescent	12	0.089 $\pm$ 0.107	0.00	0.35
		Young adult	5	0.069 $\pm$ 0.086	0.00	0.19
		Middle-aged	13	0.086 $\pm$ 0.069	0.00	0.22
Right Central	Non-Ext	Adolescent	12	0.061 $\pm$ 0.074	0.00	0.23
		Young adult	7	0.092 $\pm$ 0.096	0.02	0.28
		Middle-aged	13	0.113 $\pm$ 0.083	0.02	0.31
Left Central	Non-Ext	Adolescent	13	0.060 $\pm$ 0.040	0.00	0.12
		Young adult	7	0.040 $\pm$ 0.047	0.00	0.13
		Middle-aged	12	0.107 $\pm$ 0.095	0.00	0.27
Left Lateral	Non-Ext	Adolescent	12	0.087 $\pm$ 0.075	0.00	0.22
		Young adult	6	0.124 $\pm$ 0.111	0.00	0.27
		Middle-aged	11	0.124 $\pm$ 0.094	0.01	0.32



**Figure1.** Mean root resorption in maxillary central and lateral incisors by age

**Table2.** Descriptive analysis of root resorption in maxillary central and lateral incisors by gender.

Variable	Gender	No	Mean± SD	Minimum	Maximum
Right Lateral	Male	16	0.115±0.089	0.01	0.35
	Female	55	0.095±0.079	0.00	0.27
Right Central	Male	17	0.103±0.085	0.00	0.28
	Female	55	0.099±0.083	0.00	0.31
Left Central	Male	20	0.062±0.036	0.00	0.13
	Female	52	0.088±0.074	0.00	0.29
Left Lateral	Male	18	0.093±0.075	0.00	0.22
	Female	50	0.110±0.090	0.00	0.35

Based on the Kruskal-Wallis test for the analysis of root resorption of right central incisors the significance level was 0.322, and for left central incisors 0.289. Therefore, it can be concluded that with a 95% confidence level, the mean root resorption in right and left maxillary central incisors is the same in the adolescence, younger adulthood, and middle adulthood groups. In order to evaluation the root resorption of right and left laterals in three age groups, and considering the normality of their distribution, Levene's test and one-way ANOVA showed that the root resorption of right ( $P=0.358$ ) and left lateral ( $P=0.739$ ) is the same in the adolescence, young adulthood, and middle adulthood groups. The Wilcoxon test was used to further compare the mean root resorption of lateral and central incisors. The results showed no significant difference between the mean root resorption of right central and lateral incisors ( $P=0.518$ ) and also between left central and

lateral incisors ( $P=0.063$ ). Based on the Mann-Whitney test for comparing the mean root resorption of maxillary central and lateral incisors by gender and by type of treatment, no significant differences were reported ( $P>0.05$ ).

**Discussion**

The primary reason adults seek orthodontic treatment is the appearance of their anterior teeth (5). It is expected that the demand for orthodontic treatment among adults will rise. These older individuals are more prone to chronic periodontal disease and root resorption. (6) In this study, we followed ethical principles similar to other research on root resorption caused by orthodontic treatment by using panoramic radiographs of patients taken before treatment and at least one year after treatment (11-16). The maxillary central and lateral incisors were selected for analysis due to their

ease of assessment in panoramic radiographs and their higher incidence of root resorption related to orthodontic procedures (17). In the present study, external apical root resorption was observed in maxillary central and lateral incisors after orthodontic treatment in all three age groups of adolescents, young adults, and middle-aged adults. The highest mean amount of resorption was observed in the right lateral incisor, although this amount was not statistically significant. In statistical comparison, the mean amount of external apical root resorption in the left and right central and lateral incisors was the same in these three studied groups.

Although the amount of resorption was greater in women compared to men, the mean external apical root resorption of maxillary central and lateral incisors was statistically similar in both genders. Also, the mean external apical root resorption of maxillary central and lateral incisors did not have a significant difference between the two methods of extraction and non-extraction. However, this mean value was higher in the extraction treatment group than in the non-extraction treatment group.

Han et al. (8) conducted a study in 2019 to evaluate periodontal and root changes after orthodontic treatment in middle-aged adults are similar to those in young adults. They collected records from young adults (12 individuals aged 19 to 30 years) and middle-aged adults (27 individuals aged over 40 years) both before and after orthodontic treatment. The mean root resorption was 1.0 and 6.0 mm in middle-aged and young adults, respectively, and the degree of root resorption was similar between the two groups in terms of treatment complexity and treatment duration. Therefore, the results of this study are consistent with Han et al.'s study (8). Although this study focused on three age groups for more precise examination.

Nigl and Train (18) investigated the factors associated with apical root resorption in maxillary incisors among orthodontic patients. They examined 75 patients who had undergone fixed orthodontic treatment using radiographic analysis. The results indicated that the severity of root resorption did not vary significantly between men and women, nor between children and adults. Additionally, the use of extraction during treatment did not lead to notable differences in the extent of resorption. Therefore, the findings of this study align with those of Nigl and Train's previous research, although it is important to note that the population studied by Nigl et al. was younger

Elhaddaoui et al. (16) randomly selected 82 patients (28% male, 72% female) aged 12-27 years who had undergone treatment with fixed appliances for at least one year and had panoramic radiographs before, during, and after treatment. The study found that external apical root resorption was not related to age or gender. Although the study showed that root resorption in lateral teeth was greater than in other teeth, this difference was not statistically significant in this study. The reason for this difference may be related to the sample size of Elhaddaoui's study. Although statistically insignificant in this study, it was shown that extraction treatment resulted in more root resorption than non-extraction treatment, which is consistent with Elhaddaoui's study.

Bayir and Bolat Gumus (14) evaluated the incidence and severity of orthodontically induced inflammatory external apical root resorption (OIIEARR) and the relationship between OIIEARR and possible risk factors such as orthodontic treatment type, treatment duration, gender, and age of the patient. The study sample consisted of 1356 orthodontically treated patients (857 females and 498 males; mean age:  $14.4 \pm 2.8$  years). OIIEARR was evaluated using pre- and post-treatment panoramic radiographs for all the tooth groups. The results showed that the incidence of severe root resorption following orthodontic treatment was 14.8%. Males exhibited a higher incidence of root resorption compared to females. Orthodontic treatment duration and treatment with extractions were positively correlated with OIIEARR ( $P < 0.05$ ). OIIEARR was observed most frequently in maxillary incisors, followed by mandibular incisors. The reason for inconsistency with our study can be attributed to differences in sample size, mean age of participants, and methodology, including the examination of all dental groups in this study compared to maxillary incisors in our study. On the other hand, with an increase in sample size, it may have been possible to obtain similar results.

Tieu et al. (19) conducted a review study to determine external root resorption in upper incisors after non-surgical orthodontic treatment for Class II division malocclusion; eight medium-quality method studies were selected from two electronic databases. This study found that gender did not affect the amount of root resorption. The amount of resorption did not differ between maxillary anterior, central, and lateral teeth, so this study is consistent with Tieu et al.'s study.

Jung and Cho (20) selected 163 patients who had panoramic and lateral cephalometric radiographs

before and after treatment to investigate external apical root resorption in maxillary anterior and posterior teeth. The results showed that the amount of external apical root resorption was the same in both the left and right sides of the anterior and molar teeth. There was no significant correlation between root resorption and patient gender or age, so the results of this study are consistent with Jung and Cho's study. Nanekrungsan et al (4) investigated external apical root resorption in maxillary incisors in orthodontic patients: related factors and radiographic assessment; they examined the medical history and periapical radiographs of the maxillary incisors of 181 patients. The results showed that treatment with premolar extraction was a significant factor in external apical root resorption, and age at the start of treatment was also related to root resorption. While the average amount of resorption in central and lateral teeth and in all three age groups was statistically similar between treatment with and without tooth extraction in this study, the results are inconsistent with Nanekrungsan's study. The reason for this difference may be the type of radiography used, as Nanekrungsan's study used periapical radiography, while this study used panoramic radiography. Additionally, the sample size in Nanekrungsan's study was larger than in this study. Furthermore, this study included three age groups, with a minimum age of 17 years, while Nanekrungsan's study included two age groups, with 59% of teeth in patients under 16 years old (which did not exist in this study).

### Conclusion

In the present study, external apical root resorption was observed in the central and lateral maxillary teeth after orthodontic treatment. The average external apical root resorption was similar in the three age groups of adolescents, younger adults, and older adults, and gender and treatment type did not differ in the amount of external apical root resorption.

**Conflict of Interests:** The authors of this manuscript declare that they have no conflicts of interest, real or perceived, financial or non-financial in this article

### References

1. Heboyan A, Avetisyan A, Markaryan M, Manrikyan M, Vardanyan I. Tooth Root Resorption Conditioned by Orthodontic Treatment. *Oral Health Dental Sci.* 2019; 3(2): 1-8.
2. Kalra S, Gupta P, Tripathi T, Rai P. External apical root resorption in orthodontic patients: molecular and genetic basis. *J Family Med Prim Care.* 2020;9(8):3872-3882.
3. Feller L, Khammissa RA, Thomadakis G, Fourie J, Lemmer J. Apical External Root Resorption and Repair in Orthodontic Tooth Movement: Biological Events. *Biomed Res Int.* 2016;2016:4864195.
4. Nanekrungsan K, Patanaporn V, Janhom A, Korwanich N. External apical root resorption in maxillary incisors in orthodontic patients: associated factors and radiographic evaluation. *Imaging Sci Dent.* 2012;42(3):147-154
5. Pabari S, Moles DR, Cunningham SJ. Assessment of motivation and psychological characteristics of adult orthodontic patients. *Am J Orthod Dentofacial Orthop.* 2011;140(6):e263-e272.
6. Liu Y, Li CX, Nie J, Mi CB, Li YM. Interactions between Orthodontic Treatment and Gingival Tissue. *Chin J Dent Res.* 2023;26(1):11-18.
7. Eke PI, Dye BA, Wei L, Slade GD, Thornton-Evans GO, Borgnakke WS, et al. Update on Prevalence of Periodontitis in Adults in the United States: NHANES 2009 to 2012. *J Periodontol.* 2015;86(5):611-622.
8. Han J, Hwang S, Nguyen T, Proffit WR, Soma K, Choi YJ, et al. Periodontal and root changes after orthodontic treatment in middle-aged adults are similar to those in young adults. *Am J Orthod Dentofacial Orthop.* 2019;155(5):650-655.e2
9. Graber LW, Vig KWL, Huang GJ, Fleming PS. *Orthodontics: Current Principles and Techniques.* 7th ed. Philadelphia: Elsevier; 2022; 868.
10. Sameshima GT, Asgarifar KO. Assessment of root resorption and root shape: periapical vs panoramic films. *Angle Orthod.* 2001;71(3):185-189.
11. Lee YJ, Lee TY. External root resorption during orthodontic treatment in root-filled teeth and contralateral teeth with vital pulp: A clinical study of contributing factors. *Am J Orthod Dentofacial Orthop.* 2016;149(1):84-91
12. Tian YL, Wang K, Wang J, Liu F, Piao ML. Root resorption after orthodontic treatment: study age factor and prevalence in anterior teeth. *Shanghai Kou Qiang Yi Xue.* 2013;22(2):224-227.
13. Preoteasa CT, Ionescu E, Preoteasa E, Comes CA, Buzea MC, Grănescu A. Orthodontically induced root resorption correlated with morphological characteristics. *Rom J Morphol Embryol.* 2009;50(2):257-262.
14. Bayir F, Bolat Gumus E. External apical root resorption after orthodontic treatment: Incidence, severity and risk factors. *J Dent Res Dent Clin Dent*

- Prospects. 2021;15(2):100-105.
15. Gay G, Ravera S, Castroflorio T, Garino F, Rossini G, Parrini S, et al. Root resorption during orthodontic treatment with Invisalign®: a radiometric study. *Prog Orthod*. 2017;18(1):12.
  16. Elhaddaoui R, Benyahia H, Azeroual MF, Zaoui F, Razine R, Bahije L. Resorption of maxillary incisors after orthodontic treatment--clinical study of risk factors. *Int Orthod*. 2016;14(1):48-64.
  17. Proffit WR, Fields HW, Larson BE, Sarver DM. *Contemporary orthodontics*. 6<sup>th</sup> ed. Philadelphia: Elsevier, 2019. P: 40-41.
  18. Nigul K, Jagomagi T. Factors related to apical root resorption of maxillary incisors in orthodontic patients. *Stomatologija*. 2006;8(3):76-79.
  19. Tieu LD, Saltaji H, Normando D, Flores-Mir C. Radiologically determined orthodontically induced external apical root resorption in incisors after non-surgical orthodontic treatment of class II division 1 malocclusion: a systematic review. *Prog Orthod*. 2014;15(1):48.
  20. Jung YH, Cho BH. External root resorption after orthodontic treatment: a study of contributing factors. *Imaging Sci Dent*. 2011;41(1):17-21.