

Minimizing Alveolar Ridge Shrinkage Following Immediate Implant Placement: A Literature Search and Narrative Review

Rickson Daniel Valtellini¹, Douglas Albert Deporter²

Received: 2023-03-14 / Accepted: 2023-05-02 / First publication date: 2023-05-10

© The Author(s) 2023

Abstract

Background: To uncover evidence of whether immediate implant placement (IIP) significantly reduces horizontal ridge shrinkage?

Materials and Methods: Electronic searches (1980 to September 2021) were performed by two reviewers using PubMed, MEDLINE, and Cochrane Central.

Results: Findings suggested that IIP using flap-less surgery, atraumatic extraction, 3D positioning, gap grafting with xenograft and customized healing abutments may limit shrinkage similarly to that with socket preservation grafting and delayed implant placement (SPG/DH).

Conclusions: Further randomized, clinical trials directly comparing IIP and SPG/DH will be needed for confirmation.

Key words: Immediate implant; bone remodeling

Introduction

The modern dental implant has been used worldwide to restore edentulous sites since the early eighties. However, protocols for implant placement have changed over the decades as clinical research and clinicians' experiences have been documented. The traditional protocol called for the healing of edentulous sites for at least 6 months' post-extraction before implant placement (1). A further 3-6 months were needed to allow implant osseointegration with bone. Overall treatment times ranged from 1 to 2 years which was frustrating for patients who often rejected the treatment. As a result, with time and experience, clinicians moved toward placing implants at the time of tooth extraction ("immediate implantation"). Immediate implant placement (IIP) offers advantages over delayed protocols, including a reduction in the number of surgical treatments and time needed between tooth extraction and placement of the definitive prosthesis and a possible reduction in costs. However, it may not be as successful as delayed implant placement. For example, in a recent systematic review, success rates following immediate implant placement

were assumingly lower than treatment with socket preservation grafting and delayed implant placement (2).

One of the original aims for IIP was the possible reduction in alveolar ridge shrinkage observed with natural healing after tooth extraction, which occurs in two phases (3). Initially, a blood clot fills the void that previously housed the tooth roots leading to the formation of granulation tissue and its transformation to the woven bone with the loss of the original bundle bone and a reduction in vertical alveolar ridge height. In a second phase, significant buccolingual/palatal horizontal ridge resorption, generally on the buccal aspect, leads to dramatic shrinkage (up to 50%) in the first 6-12 months with slower rates of resorption of 0.5-1% annually (4). Tooth location may affect the degree of ridge shrinkage likely related to the initial thickness of buccal/facial cortical plates (5, 6). Spinato et al.(7) and others(8) reported that buccal bone plates >1 mm in thickness at non-molar sites showed less horizontal resorption than thin plates (≤1 mm).

In attempts to reduce ridge shrinkage, the technique of socket preservation grafting (SPG)(9) was introduced and has become more or less standard of care following tooth extraction particularly if later implant placement is planned. Multiple reports have documented that SPG will dramatically reduce horizontal alveolar ridge shrinkage. (10) Non-molar sites have a greater

Corresponding Author:
douglas.deporter@dentistry.utoronto.ca

¹ BEng, Faculty of Dentistry, University of Toronto, Ontario, Canada

² Discipline of Periodontology, University of Toronto, Toronto, Ontario, Canada

need for SPG compared with molar sites (69.7% vs 45.9%, respectively). (5) However, sequential CBCT assessments at molar sockets have documented that SPG (xenograft + resorbable barrier) will reduce resorption significantly compared to non-grafted control sites both at 1mm (-1.02 ± 0.88 vs. -4.44 ± 3.71 mm) and 3 mm (-0.31 ± 1.51 vs. -2.27 ± 1.15 mm) below the original bone crest. (11) Again, using CBCT analyses, Jung et al. (12) reported that compared to spontaneous socket healing, SPG using particulate xenograft and resorbable membranes in posterior jaw sites led to significantly less loss in ridge width at both 1mm (SPG: -17.14% vs control: -32.47%), and 3mm (test: -11.65% vs control: -28.47%) apical to the crest. It is clear then that SPG procedures have the benefit of reducing if not dropping buccolingual/palatal ridge width shrinkage. Unfortunately, including SPG in preparation for later implant placement does add time, inconvenience, and cost. Also, particular graft materials (e.g., xenograft) placed into extraction sockets may impair routine bone healing as remnants will remain indefinitely (13).

Furthermore, a recent retrospective study of 1,370 extraction sites in 216 patients indicated that only 40% of extraction sockets that were allowed to heal unassisted (i.e. without SPG) were unable to receive delayed implants without additive bone augmentation procedures (14). To date, clear criteria have not been identified to help predict which 60% of sites will heal well enough without SPG. It would seem then that SPG usage at all extraction sockets may not be appropriate. But what about the impact of immediate implant placement (IIP) on subsequent horizontal ridge shrinkage? While some early case presentations suggested that IIP was of benefit, a consensus has never been established. Based on our clinical experiences, however, we were intrigued by past conflicting reports and undertook the current narrative literature review. The aim was also to identify all contributing factors to minimize bone remodelling without adversely influencing the short and long-term success of IIPs.

Methods

Electronic and manual literature searches were performed by two independent reviewers using several databases including PubMed, MEDLINE, and Cochrane Central, for publications from 1980 up to September 2021 that reported outcomes for alveolar bone changes following placement and restoration of immediate implants.

Focused question

In systemically healthy patients receiving immediate implant treatment, is there a significant reduction for alveolar ridge remodelling compared to unassisted socket healing and delayed implant placement?

PICO format:

Population: Systemically healthy patients with a failing tooth

Intervention: IIP (i.e., implants immediately placed after tooth extraction)

Comparison: IIP versus unassisted socket healing and/or socket preservation grafting (SP)

Primary outcome: Amount of horizontal alveolar ridge resorption post-IIP

Secondary outcomes: Buccal plate thickness, peri-implant buccal gaps

Search terms included: (((((((Bone defect OR alveolar bone loss [Mesh Term] OR Surgical wound dehiscence [Mesh Term] OR dehiscence OR dehiscence's OR alveolar process OR alveolar ridge) AND (Alveolar ridge preservation OR Alveolar ridge augmentation [Mesh Term] OR Socket preservation OR tooth extraction [Mesh Term] OR tooth socket [Mesh Term]) AND (Immediate implant OR Immediate implant placement)) OR (Peri-implant distance[Title/Abstract])) OR (buccal gap[Title/Abstract])) OR (jumping distance[Title/Abstract])) OR (atraumatic dental extraction[Mesh Terms]))

Results

Our approach with this review was to find reports with findings relevant to horizontal alveolar ridge shrinkage following IIP compared to spontaneous, unassisted socket healing or socket preservation grafting with/without delayed implant placement. The original

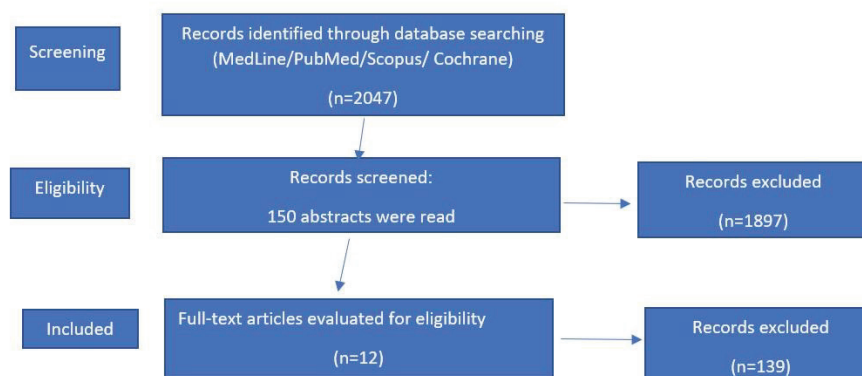


Figure 1. PRISMA flow chart on the search strategy.

search terms/query used in preparing this report turned up 2,047 publications in English (figure 1). After examining the abstracts, a thorough assessment of relevant papers was performed. Relevant articles were considered, as well-documented observational studies reporting IIP data (minimum 3-month follow-ups) and

Table 1: Summary of Literature Search
Abbreviations: (NR) not reported; (I) incisor; (C) canine; (PM) premolar; (M) molar; (RCT) randomized controlled trial; (DBBM) deproteinized bovine bone material; (DFDBA) demineralized freeze-dried bone allograft; (AG) autograft; (E-PTFE) expanded polytetrafluoroethylene; (CTG) connective tissue graft.
(IIP) immediate implant placement; (SPG) socket preservation graft; (contr); control, i.e. spontaneous socket healing.

Article	Year	Number of Implants	Location	Protocol	Postoperative Measurements		Gingival phenotype	Implant Type
					Duration months	Method		
Werbitt ¹⁶	1992	8	I, PM, M	2-Stage	6	visual	NR	Branemark
Lazzara ¹⁵	1989	4	I, PM, M	2-stage	6	visual	NR	NR
Botticelli et al. ¹⁸	2004	21	I, C, PM	1-stage	4	clinical calipers	NR	Straumann
Chen et al. ²³	2007	10	anterior maxilla	2-stage	6	clinical probing	either	Straumann
Chen		10						
Chen		10						
Sanz et al. ¹⁹	2010	93	I, C, PM maxilla	2-stage	4	clinical probing	either	Astra Osseo-Speed
Degidi et al. ²⁶	2013	69	I, C, PM maxilla	1-stage	12	CBCT	either	NR
Rossi et al. ²⁴	2013	12	PM	2-stage	4	CBCT	either	Biomet 3i
Clementini et al. ²⁵	2019	10 IIP	I, C, PM maxilla	2-stage	4	CBCT	either	WINSIX
Clementini		10 SPG						
Clementini		10 contr						
Chen et al. ³⁰	2019	17	M	1-stage	6	CBCT	either	Straumann
Bittner et al. ²⁰	2020	16	maxillary	1-stage	12	CBCT	either	Biomet 3i
Bittner		16	anterior					
Lilet et al. ³³	2022	20	M, PM	1 stage	12	CBCT	thick	Straumann BLX
Slagter et al ²⁹	2021	20 IIP	anterior maxilla	2-stage	3.60	CBCT	NR	Nobel Active
Slagter et al ²⁹		20 SPG						

meta-analyses exploring similar research questions. (Table 1)
Due to the heterogenicity of the identified studies and the number of compounding factors, no meta-analysis could be performed, leaving us to present this descriptive, narrative review.
Our findings were classified according to three periods of investigation: i) early clinical observations; ii) next animal and human studies; and finally, iii) more recent studies employing refined clinical protocols mined from earlier data. Early clinical case reports by Lazzara (15) and others (16) suggested that IIP might inhibit alveolar ridge shrinkage based on visual assessments at re-entry surgery. Following these reports, work with canines was undertaken to study the matter further. Araujo et al. (17) extracted premolar tooth roots in dogs and studied remodelling with unassisted socket healing versus those where immediate implants had been placed. Histometric measurements in retrieved specimens revealed significant and similar levels of bone remodelling by 3 months in both groups. At about the same time, Botticelli et al. reported results from a human clinical study in which immediate implants were placed at incisor, cuspid and bicuspid tooth sites (18). Bone measurements were made clinically using callipers. They saw that while peri-implant gaps healed spontaneously with new bone by 4 months post-implantation, significant alveolar ridge shrinkage (56%

Article	Study	Barrier Used	Flapless	Grafting material used	Buccal Gap (mm)	Initial Buccal wall thickness (mm)	Horizontal Resorption
Werbitt	case series	E-PTFE	no	DFDBA or none	NR	variable	"Preservation of ridge contour"
Lazzara	case series	E-PTFE	no	none	≥ 1	NR	"Preserves bone at the sight of implantation"
Botticelli et al.	clinical trial	collagen	no	none	2 ± 0.7	1.4 ± 0.4	56% buccal 30% palatal
Chen et al. Chen Chen	RCT RCT RCT	collagen no barrier no barrier	no no no	DBBM DBBM none	2.2 ± 0.2 2.4 ± 0.3 2.3 ± 0.5	1 to 3 1 to 3 1 to 3	$20 \pm 21.9\%$ $15.8 \pm 16.9\%$ $48.3 \pm 9.5\%$
Sanz et al.	RCT	no barrier	no	none	2.2 ± 1.2	0.5-3.0	63 -80% horizontal. 30-43% buccal
Degidi et al.	cohort	no barrier	yes	Bio-Oss® Collagen	1 to 4	1.2 average	0.88mm or 29.3%
Rossi et al.	clinical trial	no barrier	no	none	1.7 ± 1	1 to 3	1.9 mm (76%) buccal
Clementini et al. Clementini Clementini	RCT RCT RCT	collagen collagen no barrier	no no no	DBBM DBBM none	 NR 	1.34 ± 0.45 1.33 ± 0.25 1.17 ± 0.39	$1.29 \pm 0.38\text{mm.}$ $(14.9 \pm 4.9\%)$ $1.56 \pm 0.76\text{ mm.}$ $(19.2 \pm 9.1\%)$ $3.37 \pm 1.55\text{ mm.}$ $(43.2 \pm 25.1\%)$
Chen et al.	clinical trial	none	yes	DBBM	NR	3.01 ± 0.87	0.48mm (15.3%)
Bittner et al. Bittner	RCT RCT	none none	yes yes	Bio-Oss® Collagen none	2.9 ± 2.3 3.1 ± 0.9	1.1 ± 0.7 0.8 ± 0.5	$0.84 \pm 0.64\text{mm}$ buccal $1.01 \pm 0.62\text{mm}$ buccal
Lilet et al.	clinical trial	none	yes	DBBM	NR	intact	$0.33 \pm 0.81\text{mm}$
Slagter et al Slagter et al	RCT RCT	CTG CTG	no	DBBM +AG	NR	buccal dehiscences <5mm	small & like SPG

buccally and 30% palatally) occurred. Further support for these findings came from a study by Sanz et al. (19). Recent studies suggest that IIP in conjunction with peri-implant gap grafting can produce more favourable outcomes, especially when immediate customized healing abutments or temporary non-occlusal-loaded restorations are provided. (20)

Most information found regarding the impact of IIP on bone changes relates to non-molar tooth sites often in the maxilla. Facial bone thickness here is commonly <1mm (21) which is quite different from that at molar sites, particularly in the mandible where the buccal bone tends to be much thicker (22). Mandibular molar sites also demonstrate significant increases in buccal plate thickness from coronal to apical.

Chen et al. (23) published results from a clinical study where immediate implants were placed at maxillary anterior or bicuspid tooth sites as controls (no gap grafting) compared to IIPs with xenograft gap grafting alone or xenograft covered with a collagen barrier. Full-thickness flaps were raised in both groups. Horizontal

bone loss was measured clinically using a periodontal probe at implant placement and at re-entry surgery after 6 months of healing. At that time, horizontal ridge resorption was significantly greater in the control group ($48.3 \pm 9.5\%$) when compared to IIPs with gap grafting alone ($15.8 \pm 16.9\%$) or IIPs with graft covered with collagen membrane ($20 \pm 21.9\%$). Rossi et al. conducted a small study with 12 patients receiving IIPs in maxillary or mandibular bicuspid sites after raising full mucoperiosteal flaps and reported a greater ridge shrinkage. (24). Bone changes were documented using CBCT scans. The original mean buccal thickness was 2.5mm at 1mm apical to the crest. After 4 months of healing, re-entry surgery revealed buccal horizontal resorption of 1.9 mm (76%) at 1.0 mm from the crest. Clementini et al. (25) also studied post-extraction ridge shrinkage in single-rooted teeth or bicuspids by comparing three different protocols, which all used full-thickness flap elevation: i) spontaneous socket healing (SH); ii) socket preservation grafting (SPG) with bovine xenograft and resorbable membrane (DBBM/

CM); and iii) immediate implantation combined with concomitant gap grafting using the same materials (IMPL/DBBM/CM). Ridge width measurements were made with CBCT scans at baseline and after 4 months. The SH group lost significantly more horizontal ridge width (3.37 ± 1.55 mm or $43.2 \pm 25.1\%$) at the most coronal aspect than both the sites with SPG (1.56 ± 0.76 mm; or $19.2 \pm 9.1\%$) or immediate implants with added graft materials (1.29 ± 0.38 mm; or $14.9 \pm 4.9\%$). No significant differences were observed between the DBBM/CM and IMPL/DBBM/CM groups.

Degidi et al. (26) added flap-less surgery to IIP protocols placing sixty-nine immediate implants (ANKYLOS® plus, Dentsply-Friadent, Mannheim, Germany) along with immediate non-occlusal loading at maxillary bicuspid and anterior tooth sites. Implants were placed towards the palatal with 1 to 4mm gaps between the implant and the buccal socket wall. These gaps were grafted with the xenograft Bio-Oss Collagen® (Geistlich Pharma AG, Switzerland), and changes in horizontal ridge dimension were measured using CBCT scans (pre-op and 1 year later). The original mean buccal bone thickness at the level of the implant shoulder was $3\text{mm} \pm 0.86$ mm and was reduced to 2.12 ± 0.92 mm (loss of 0.88mm or 29.3%) after 12 months. Unfortunately, no controls (spontaneous, unassisted socket healing with or without delayed implant placement) were included for comparison.

In a more recent publication, Bittner et al. (20) reported results of a prospective, randomized, controlled clinical trial comparing changes in the alveolar ridge over 1 year following immediate implant placement and temporization with or without gap grafting using xenograft (deproteinized bovine bone mineral with 10% collagen). Each of the 32 patients had a hopeless maxillary anterior tooth and wished to have it replaced using an immediate implant with flap-less surgery. In Half of the patients, the buccal peri-implant gap was grafted, while the remaining patients were left ungrafted. Pre-op CBCT scans were used to ensure intact bone walls. Either immediate, non-occlusal-loaded temporary crowns or customized healing abutments were placed on the day of surgery, while final restorations were delayed until at least 6 months. At the 1-year after implant insertion follow-up exam, the grafted group showed less horizontal alveolar ridge dimensional change than the control group, but the differences were not statistically significant. A complicating factor in both groups might be as implants were carefully temporized providing non-occlusal loading and soft tissue support which both have been reported to reduce ridge shrinkage (27, 28)

Most recently in a report from Slagter et al. (29) offered 5-year outcomes from a randomized controlled trial comparing peri-implant soft and hard tissue parameters following either immediate implant placement or socket

preservation grafting (SPG) with delayed implant insertion. Patients treated each had a failing tooth in the anterior maxilla with facial bony dehiscence of < 5 mm after extraction. Twenty patients were included for each treatment protocol treatment group I received immediate implants, and treatment group II received SPG and delayed implant insertion. Immediate implants were placed towards the socket palatal walls with facial gaps and dehiscence defects being grafted with a mixture of autogenous tuberosity bone and xenograft covered with an autogenous connective graft to allow soft tissue closure and submerged healing. The same materials were used for the SPG sites. Re-entry surgery and temporization were provided after 3 months of site healing, with final prostheses happening after a further 3 months. While horizontal changes in Bucco-palatal ridge width were not recorded, changes in facial bone thickness at the time of tooth extraction and at 3 months and 5 years after placing the definitive restorations were calculated from CBCTs. Facial bone thickness increased over time with no significant differences between the two treatment groups. Thickness at the level of the implant neck for the IIPs after 5 years ranged from 0.44mm to 2.04 mm, while the range of thicknesses for the SPG/delayed implants was 0.43mm to 1.74mm.

Less information could be found concerning ridge shrinkage following immediate molar implant placement. Chen et al. (30) reported outcomes from 15 patients who received 17 immediate molar implants. CBCT measurements of horizontal buccal (HBT) and lingual (LBT) bone thicknesses were taken at implant installation and 6 months later. In these flap-less anatomically-guided osteotomies an optimal 3-D implant positioning preparation was used (31). Along with gap grafting using xenograft and placement of wide-diameter stock healing abutments to help “seal” the sockets and provide some non-occlusal loading. At 6 months, loss in HBT at 1mm below the crest was reported to be 0.48mm (15.3%) of the original 3.13 mm. Loss in LBT was even less at 7.5%. Gap grafting was beneficial, although immediate, non-occlusal loading with the healing abutments (27) again may have contributed to the outcomes.

Lilet et al. (32) also presented findings of a prospective case series intended to assess hard and soft tissue changes following immediate implant placement in the molar or premolar sites (maxillary or mandibular), the protocol including gap grafting with xenograft covered with custom-made healing abutments (fabricated using intra-oral digital scans) meant to provide support for the original, pre-extraction soft tissue contours. Fifty percent of the sites were mandibular molars, although, in the maxilla, most were premolars. Twenty non-smoking, otherwise healthy patients were included. Comparing horizontal ridge width and soft tissue levels

were determined between baseline and one-year using CBCT and intra-oral scans. All sites were needed to show at least 2 mm of keratinized gingival width, intact buccal bone walls, and good plaque control. Twenty BLX implants (Roxolid®, SLAactive®, Institute Straumann AG) were placed using flap-less surgery. Following treatment, horizontal ridge shrinkage was labelled as non-significant during the 1-year interval at any level (2, 5 and 7mm below the implant platform). Furthermore, soft tissue profiles (pink esthetic scores) were stable with almost no mid-buccal recession (0.07 mm).

Discussion

Our focus was to uncover evidence to advocate or refute whether IIP can effectively and significantly reduce the loss in alveolar ridge width and/or buccal plate thickness seen during spontaneous, post-extraction socket healing and to show possible contributory factors.

Early information from case reports (15, 16) suggested that IIP might prevent this loss, but no actual pre- and post-treatment measurements were presented. Araujo et al. (17) elected to study this issue in dogs and reported similar degrees of bone remodelling and loss at mandibular premolar extraction sites treated with IIPs or left to heal by themselves for 3 months. However, a close examination of the study protocol showed that stock implants made for humans rather than customized for dog sockets had been used. The diameters of these implants would have been too large for dog premolar sockets leaving no gaps for grafting and instances where implants made direct contact with the naturally-thin buccal plates. It was no wonder then that IIPs did not reduce alveolar ridge shrinkage. Also of note was the fact that flaps were raised for a tooth removal. Nevertheless, other investigators studied whether similar outcomes would occur in humans.

Botticelli and coworkers (18) published a clinical case series in which 18 patients received 21 IIPs. Gap grafting was not performed even though non-submerged healing was allowed. After 4 months, a significant buccolingual horizontal ridge resorption (buccal bone loss 56%, lingual/ palatal bone 30%) was seen that revealed IIP did not reduce alveolar ridge shrinkage. However, the use of full-thickness flaps both for the first and re-entry surgeries would have favoured bone loss. Sanz et al. (19) later performed prospective, multicenter research that supported the above - mentioned Botticelli's findings. They replaced single non-molar or molar teeth with IIPs (OsseoSpeed™, Astra Tech AB, Mölndal, Sweden) of proper diameters to ensure the presence of peri-implant gaps. The buccal and palatal bone wall thickness were measured 1mm apical to the bone crest (measured to the nearest half-millimetre using callipers). No gap grafting was done, and after

16 weeks, a 30-40% loss in buccal bone thickness was observed. Negative factors similar to the study of Botticelli et al. likely contributed to the outcome (twice flap elevations and no gap grafting) like the study of Rossi et al. (24), who measured changes in buccal bone thickness using CBCT scans. The original mean buccal thickness was 2.5mm at 1mm apical to the crest, but after 4 months of healing, re-entry surgery revealed horizontal buccal resorption of 1.9 mm (76%) at 1.0 mm from the bone crest.

In contrast to Botticelli, Sanz and Rossi, Degidi et al. (26) placed 69 immediate implants (ANKYLOS® plus, Dentsply-Friadent, Mannheim, Germany) using flap-less surgery, gap grafting and immediate non-occlusal loading. Changes in horizontal ridge dimension were measured at the level of the implant shoulder using CBCT scans pre-op and 1 year later. The original mean buccal bone thickness at the level of the implant shoulder was $3\text{mm} \pm 0.86\text{ mm}$ which was reduced to $2.12 \pm 0.92\text{ mm}$ (loss of 0.88mm or 29.3%) after 12 months. This confirms the importance of site selection as the thicker buccal bone showed at least 2mm thickness after site healing, a fair satisfactory outcome. The most recent studies (20, 25, 30, 33, 34) on horizontal ridge changes associated with IIPs have confirmed that bone remodelling can be reduced relative to normal socket healing with strict attention to detail. Suitable site selection is essential, and having a thicker gingiva is preferred (35-37). Careful assessment of pre-treatment CBCT radiographic scans will allow the surgeon to select sites with thicker buccal bone plates, preferably $>1.5\text{mm}$ (38), intact socket walls, and in the case of molar sites, favourable inter-septal bone volume (Types A or B). Key factors include flap-less surgery, atraumatic tooth extraction and ideal positioning of 3-D implant (figure 2).

With immediate molar implants, the tooth should be de-coronated at the CEJ level to allow initiation of the osteotomy through the furca and later separation of the roots before their careful removal (31, 40). With all bone-level IIPs, care should be taken to ensure that the implant's prosthetic platform is sub-crestal to the facial/buccal cortex by 1mm or more (41). Some manufacturers suggest sub-crestal placement of less than 2mm to avoid unwanted loss in marginal bone height during initial site healing(42). The buccal gap between the implant periphery and its buccal plate is essential, and this gap should be filled with xenograft to minimize long-term ridge shrinkage (20, 33). A customized healing abutment made either manually or with intra-oral digital scanning and CAD/CAM technology (43, 44) can help soft tissue support/contouring and non-occlusal loading (27). Finally, platform-switching (45) and socket shield technique (46) may help.

Conclusions

Degrees of bone remodelling are unavoidable following immediate implant placement. Flapless surgery, thick buccal bone, thick gingival biotype, 3-D ideal implant positioning with sub crestal placement, buccal peri-implant gap and its grafting are important in minimizing this bone remodelling. Emerging data suggest that careful, minimally invasive placement of immediate implants can reduce the horizontal alveolar ridge shrinkage associated with unassisted healing after tooth extraction. However, more randomized,

prospective, controlled clinical trials are required to compare immediate implant placement (at both non-molar and molar sites)with delayed implant placement at extraction sites previously preserved with socket grafting. Outcomes to date, have suggested that there may be no statistically significant differences between these two, but proof for such comparisons till now is limited.

Conflicts of interest: none

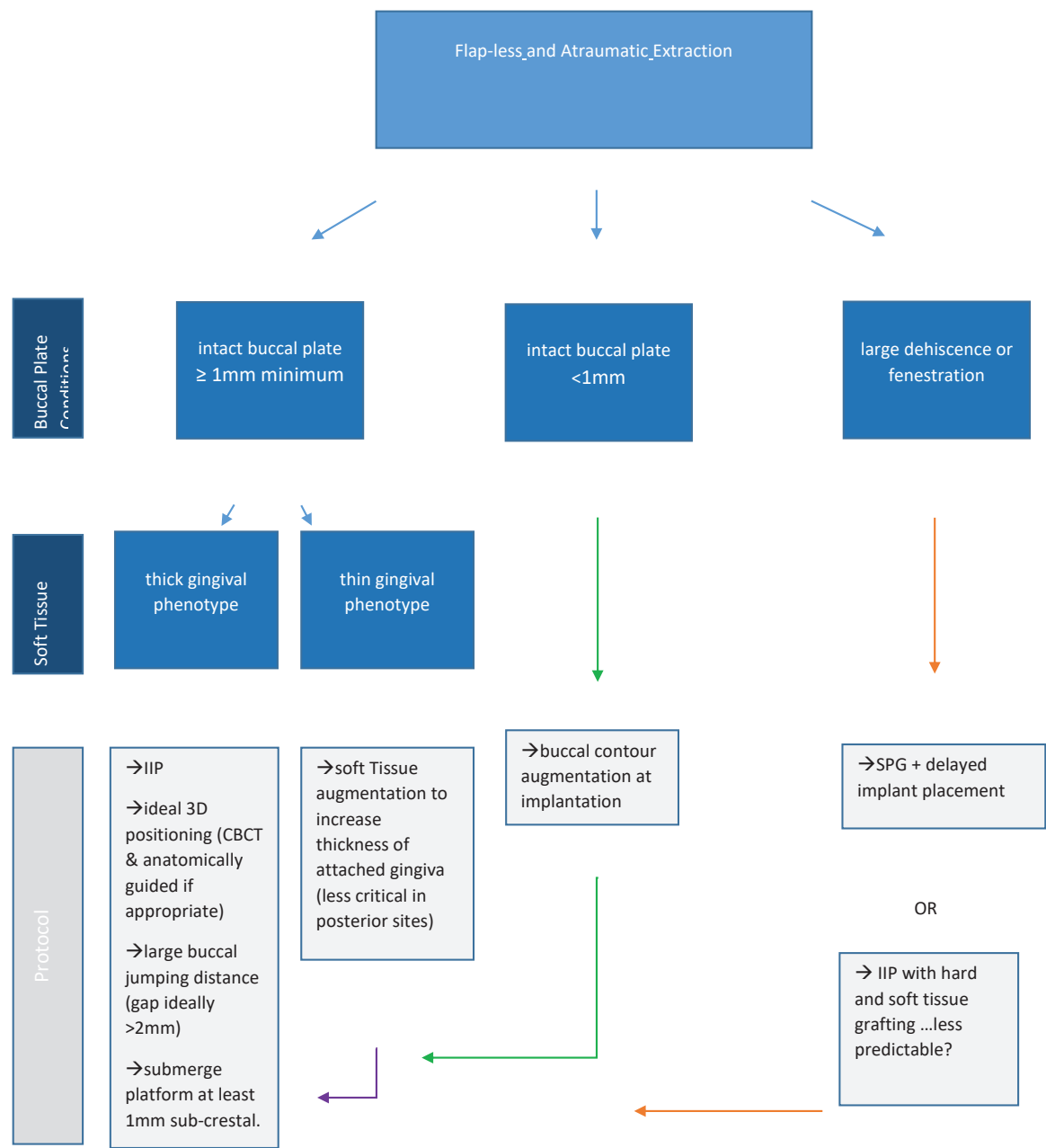


Figure 2. Flow chart for immediate implant placement (IIP); SPG = socket preservation grafting.

References

- Adell R, Lekholm U, Rockler B, Brånemark PI. A 15-year study of osseointegrated implants in the treatment of the edentulous jaw. *Int J Oral Surg* 1981; 10:387-416.
- Yu X, Teng F, Zhao A, Wu Y, Yu D. Effects of post-extraction alveolar ridge preservation versus immediate implant placement: a systematic review and meta-analysis. *J Evid Based Dent Pract*. 2022;22:101734.
- Pagni G, Pellegrini G, Giannobile WV, Rasperini G. Postextraction alveolar ridge preservation: biological basis and treatments. *Int J Dent*. 2012; 2012:151030.
- Schropp L, Kostopoulos L, Wenzel A. Bone healing following immediate versus delayed placement of titanium implants into extraction sockets: a prospective clinical study. *Int J Oral Maxillofac Implants* 2003;18:189-199.
- Couso-Queiruga E, Stühr S, Tattan M, Chambrone L, Avila-Ortiz G. Post-extraction dimensional changes: A systematic review and meta-analysis. *J Clin Periodontol*. 2021;48:126-144
- Avila-Ortiz G, Gubler M, Romero-Bustillos M, Nicholas CL, Zimmerman MB, Barwacz CA. Efficacy of Alveolar Ridge Preservation: A Randomized Controlled Trial. *J Dent Res*. 2020;99:402-409
- Spinato S, Galindo-Moreno P, Zaffe D, Bernardello F, Soardi CM. Is socket healing conditioned by buccal plate thickness? A clinical and histologic study 4 months after mineralized human bone allografting. *Clin Oral Implants Res*. 2014;25: e120-6
- Ferrus J, Cecchinato D, Pjetursson EB, Lang NP, Sanz M, Lindhe J. Factors influencing ridge alterations following immediate implant placement into extraction sockets. *Clin Oral Implants Res*. 2010;21:22-9
- Tan WL, Wong TL, Wong MC, Lang NP. A systematic review of post-extraction alveolar hard and soft tissue dimensional changes in humans. *Clin Oral Implants Res*. 2012;23 Suppl 5:1-21.
- Abdelhamid A. Alveolar bone preservation. Biological basis and techniques. *International Journal of Dental Sciences and Research* 2017; 5:56-68.
- Lim HC, Shin HS, Cho IW, Koo KT, Park JC. Ridge preservation in molar extraction sites with an open-healing approach: A randomized controlled clinical trial. *J Clin Periodontol*. 2019;46:1144-1154
- Jung RE, Sapata VM, Hämmerle CHF, Wu H, Hu XL, Lin Y. Combined use of xenogeneic bone substitute material covered with a native bilayer collagen membrane for alveolar ridge preservation: A randomized controlled clinical trial. *Clin Oral Implants Res*. 2018;29:522-529
- Araújo MG, Lindhe J. Ridge preservation with the use of Bio-Oss collagen: A 6-month study in the dog. *Clin Oral Implants Res*. 2009;20:433-40.
- Fiorellini JP, Llobell A, Norton MR, Sarmiento HL, Chang YC, Wada K. Healed Edentulous Sites: Suitability for Dental Implant Placement, Need for Secondary Procedures, and Contemporary Implant Designs. *Int J Oral Maxillofac Implants*. 2020;35:924-930
- Lazzara RJ. Immediate implant placement into extraction sites: surgical and restorative advantages. *Int J Periodontics Restorative Dent*. 1989;9:332-43.
- Werbitt MJ, Goldberg PV. The immediate implant: bone preservation and bone regeneration. *Int J Periodontics Restorative Dent*. 1992;12:206-17.
- Araújo MG, Sukekava F, Wennström JL, Lindhe J. Ridge alterations following implant placement in fresh extraction sockets: an experimental study in the dog. *J Clin Periodontol*. 2005;32:645-52.
- Botticelli D, Berglundh T, Lindhe J. Hard-tissue alterations following immediate implant placement in extraction sites. *J Clin Periodontol*. 2004;31:820-8.
- Sanz M, Cecchinato D, Ferrus J, Pjetursson EB, Lang NP, Lindhe J. A prospective, randomized-controlled clinical trial to evaluate bone preservation using implants with different geometry placed into extraction sockets in the maxilla. *Clin Oral Implants Res*. 2010;21:13-21.
- Bittner N, Planzos L, Volchonok A, Tarnow D, Schulze-Späte U. Evaluation of Horizontal and Vertical Buccal Ridge Dimensional Changes After Immediate Implant Placement and Immediate Temporization with and Without Bone Augmentation Procedures: Short-Term, 1-Year Results. A Randomized Controlled Clinical Trial. *Int J Periodontics Restorative Dent*. 2020;40:83-93.
- Tsagarida A, Toscano J, de Brito Bezerra B, Geminiani A, Barmak AB, Caton J, et al. Buccal bone thickness of maxillary anterior teeth: A systematic review and meta-analysis. *J Clin Periodontol*. 2020;47:1326-1343.
- Temple KE, Schoolfield J, Noujeim ME, Huynh-Ba G, Lasho DJ, Mealey BL. A cone beam computed tomography (CBCT) study of buccal plate thickness of the maxillary and mandibular posterior dentition. *Clin Oral Implants Res*. 2016;27:1072-8.
- Chen ST, Darby IB, Reynolds EC. A prospective clinical study of non-submerged immediate implants: clinical outcomes and esthetic results. *Clin Oral Implants Res*. 2007;18:552-62
- Rossi F, Romanelli P, Ricci E, Marchetti C, Botticelli D. A cone beam tomographic evaluation of hard tissue alterations at immediate implants: a clinical prospective study. *Int J Periodontics Restorative Dent*. 2013;33:815-23.
- Clementini M, Agostinelli A, Castelluzzo W, Cugnata F, Vignoletti F, De Sanctis M. The effect of immediate implant placement on alveolar ridge preservation compared to spontaneous healing after tooth extraction: Radiographic results of a randomized controlled clinical

- trial. *J Clin Periodontol*. 2019;46:776-786.
26. Degidi M, Daprile G, Nardi D, Piattelli A. Buccal bone plate in immediately placed and restored implant with Bio-Oss (®) collagen graft: a 1-year follow-up study. *Clin Oral Implants Res*. 2013;24:1201-5.
 27. Sommer M, Zimmermann J, Grize L, Stübinger S. Marginal bone loss one year after implantation: a systematic review of different loading protocols. *Int J Oral Maxillofac Surg*. 2020;49:121-134.
 28. Menchini-Fabris GB, Crespi R, Toti P, Crespi G, Rubino L, Covani U. A 3-year retrospective study of fresh socket implants: CAD/CAM customized healing abutment vs cover screws. *Int J Comput Dent*. 2020;23:109-117.
 29. Slagter KW, Meijer HJA, Hentenaar DFM, Vissink A, Raghoobar GM. Immediate single-tooth implant placement with simultaneous bone augmentation versus delayed implant placement after alveolar ridge preservation in bony defect sites in the esthetic region: A 5-year randomized controlled trial. *J Periodontol*. 2021; 92:1738-1748.
 30. Chen Z, Li J, Wang HL, Yu H. Initial Bone Volume Changes After Immediate Implant Placement Associated with Filling the Gap Using Bovine Bone in Molar Sites. *Int J Oral Maxillofac Implants*. 2019; 34:521-528.
 31. Rodriguez-Tizcareño MH, Bravo-Flores C. Anatomically guided implant site preparation technique at molar sites. *Implant Dent*. 2009;18:393-401.
 32. Lilet R, Desiron M, Finelle G, et al. Immediate implant placement combining socket seal abutment and peri-implant socket filling: A prospective case series. *Clin Oral Implants Res* 2022; 33:33-44.
 33. Lilet R, Desiron M, Finelle G, et al. Immediate implant placement combining socket seal abutment and peri-implant socket filling: A prospective case series. *Clin Oral Implants Res* 2022;33:33-44
 34. Slagter KW, Raghoobar GM, Hentenaar DFM, Vissink A, Meijer HJA. Immediate placement of single implants with or without immediate provisionalization in the maxillary aesthetic region: A 5-year comparative study. *J Clin Periodontol*. 2021;48:272-283
 35. Grunder U. Crestal ridge width changes when placing implants at the time of tooth extraction with and without soft tissue augmentation after a healing period of 6 months: report of 24 consecutive cases. *Int J Periodontics Restorative Dent*. 2011;31:9-17.
 36. Lee CT, Sanz-Mirallas E, Zhu L, Glick J, Heath A, Stoupel J. Predicting bone and soft tissue alterations of immediate implant sites in the esthetic zone using clinical parameters. *Clin Implant Dent Relat Res*. 2020;22:325-332.
 37. Botticelli D, Renzi A, Lindhe J, Berglundh T. Implants in fresh extraction sockets: a prospective 5-year follow-up clinical study. *Clin Oral Implants Res*. 2008;19:1226-32 38.
 38. Monje A, Chappuis V, Monje F, Muñoz F, Wang HL, Urban IA, et al. The Critical Peri-implant Buccal Bone Wall Thickness Revisited: An Experimental Study in the Beagle Dog. *Int J Oral Maxillofac Implants*. 2019;34:1328–1336
 39. Smith RB, Tarnow DP. Classification of molar extraction sites for immediate dental implant placement: technical note. *Int J Oral Maxillofac Implants*. 2013;28:911-6.
 40. Valenzuela S, Olivares JM, Weiss N, Benadof D. Immediate Implant Placement by Interradicular Bone Drilling before Molar Extraction: Clinical Case Report with One-Year Follow-Up. *Case Rep Dent*. 2018; 2018:6412826.
 41. Linkevicius T, Puisys A, Linkevicius R, Alkimavicius J, Gineviciute E, Linkeviciene L. The influence of submerged healing abutment or subcrestal implant placement on soft tissue thickness and crestal bone stability. A 2-year randomized clinical trial. *Clin Implant Dent Relat Res*. 2020;22:497-506.
 42. Vandeweghe S, Hattingh A, Wennerberg A, Bruyn HD. Surgical protocol and short-term clinical outcome of immediate placement in molar extraction sockets using a wide body implant. *J Oral Maxillofac Res*. 2011;2:e1.
 43. Wang L, Wang T, Lu Y, Fan Z. Comparing the Clinical Outcome of Peri-implant Hard and Soft Tissue Treated with Immediate Individualized CAD/CAM Healing Abutments and Conventional Healing Abutments for Single-Tooth Implants in Esthetic Areas Over 12 Months: A Randomized Clinical Trial. *Int J Oral Maxillofac Implants*. 2021;36:977-984
 44. Finelle G, Popelut A, Knafo B, Martín IS. Sealing Socket Abutments (SSAs) in Molar Immediate Implants with a Digitalized CAD/CAM Protocol: Soft Tissue Contour Changes and Radiographic Outcomes After 2 Years. *Int J Periodontics Restorative Dent*. 2021;41:235-244
 45. Saito H, Chu SJ, Zamzok J, Brown M, Smith R, Sarnachiaro G, et al. Flapless Postextraction Socket Implant Placement: The Effects of a Platform Switch-Designed Implant on Peri-implant Soft Tissue Thickness-A Prospective Study. *Int J Periodontics Restorative Dent*. 2018;38:s9-s15.
 46. Sun C, Zhao J, Liu Z, Tan L, Huang Y, Zhao L, Tao H. Comparing conventional flap-less immediate implantation and socket-shield technique for esthetic and clinical outcomes: A randomized clinical study. *Clin Oral Implants Res*. 2020;31:181-191.