



Evaluation of the height, depth and angle of submandibular gland fossa and correlation of depth with mandibular canal position using Cone beam computed tomography

Farzad Mastary Farahani¹, Roshanak Ghaffari^{2*}, ShirinZahra Farhad³

Received: 2023-09-12 / Accepted: 2023-12-16 / First publication date: 2023-12-27

© The Author(s) 2023

Abstract

Background: This study used CBCT to determine anatomical landmarks in the submandibular region, which is crucial to avoid implant surgery complications.

Materials and Methods: This cross-sectional descriptive-analytical study measured height, deepest points of the submandibular gland fossa, and the starting point of the concavity between the alveolar crest and the upper wall of the alveolar canal in 130 CBCTs of 60 men and 70 women between the ages of 40 and 70. Independent t-tests, Fisher's exact tests, chi-square tests, and Pearson correlation coefficient tests, were used to analysed data ($\alpha=0.05$).

Results: Men had higher mean height and depth of submandibular fossa. Fossa depth in women was mostly <2mm, while this was between 2-3 mm in men. The mean angle of the submandibular cavity did not show a significant difference between men and women ($p=0.187$). The depth of the submandibular cavity and angle were positively and significantly related ($p<0.001$, $r=0.529$). However, gender showed no significant relationship with the position of the mandibular canal with the deepest point of the submandibular gland fossa ($p=0.858$) and the starting point of the undercut ($p=0.211$). The deepest point above the inferior alveolar canal and the most frequent starting point of the undercut was in the middle one-third between the alveolar crest and the inferior alveolar canal for all genders.

Conclusion: It is important to evaluate the concavity and thickness of the alveolar bone in the submandibular fossa using CBCT during implant treatment, especially in men because of the greater depth of the concavity.

Keywords: Anatomy; Dental Implants; Cone-Beam Computed Tomography

Introduction

Currently, implant-based treatments are an accepted and common treatment for edentulous patients (1). These treatments allow patients to regain their dental function and aesthetics through bone integration of dental implants (2). The characteristics of bone morphology and the relationship between implants and vital anatomical structures are among the most important factors in implant surgery, which, if not

performed correctly, may lead to bone perforation, followed by inflammation, infection, mandibular fracture, and implant loss (3). There are various methods to assess anatomical areas, such as palpation of the ridges, osteometry and diagnostic cassettes. However, the osteometer is not suitable for the posterior mandibular regions due to the presence of the mylohyoid muscle, or diagnostic cassettes are not powerful enough for detecting defects in the oral floor. Clinical palpation may be used in diagnosis, but it does not a definitive method (4).

The posterior mandibular region includes the mandibular canal and the submandibular concavity, which are very important anatomical areas as the lingual and inferior alveolar nerves and the submandibular and sublingual arteries pass through (1). As a result, any damage to this

Corresponding author: Dr. Roshanak Ghaffari
Department of oral & maxillofacial Radiology, School of Dentistry, Isfahan (Khorasgan) Branch, Islamic Azad University, Isfahan, Iran
Email: roshanakghaffari@yahoo.com

¹ Department of oral & maxillofacial Radiology, School of Dentistry, Isfahan (Khorasgan) Branch, Islamic Azad University, Isfahan, Iran.

² Department of oral & maxillofacial Radiology, School of Dentistry, Isfahan (Khorasgan) Branch, Islamic Azad University, Isfahan, Iran.

³ Department of periodontology, School of Dentistry, Isfahan (Khorasgan) Branch, Islamic Azad University, Isfahan, Iran.

area during implant surgery can result in bleeding and paresthesia (4), which can be life threatening if it extends to the pharyngeal space and obstructs the upper respiratory tract in a case of a deep submandibular gland fossa (type II and type III) (5). Therefore, accurate identification of anatomical landmarks in the posterior mandibular region before implant surgery is mandatory to avoid complications.

Comparing the CBCT scan with the panoramic scan showed that the deep submandibular fossa radiolucent fossa is not clearly defined in the panoramic images, making them unreliable. Consequently, 3D imaging such as CBCT plays an important role in assessing the condition of the concavities and selecting a suitable fixture, primarily in the submandibular gland fossa, due to the presence of the inferior alveolar nerves and related arteries and veins, to prevent errors and perforations during drilling and subsequent complications (6, 7).

Researchers have shown that CBCT is a suitable method to evaluate mandibular morphology, particularly for the identification of lingual concavity. This is because of the high measurement accuracy obtained from high-resolution images that are free from superimposition, magnification, and image distortion. Additionally, it exposes the patient to a lower radiation dose compared to CT (8).

In a study by Koushal & Tangotra (9), found that the submandibular gland fossa depth was greater in men, and greater depth was observed on the right side of the mandible than on the left side in both genders. A study by Rajput et al. (1) discovered that the best type of concavity for safe implant placement is type I, while types II and III increases the risk of post-implantation complications.

Since the submandibular gland fossa dimensions and anatomy can be evaluated properly in cross-sectional imaging and sufficient information about the morphological and anatomical characteristics of the area is important to prevent cortical perforation of the lingual plate during implant treatment, and also it is more important to measure bone thickness at this area compared to other areas this study aimed to determine the assessment of the height, depth and angle of the submandibular gland fossa and its relationship with the mandibular canal using CBCT.

Materials and Methods

In this cross-sectional study 130 CBCT images of 70 women and 60 men who were referred to Department of Oral and Maxillofacial Radiology, Islamic Azad University of Isfahan (Khorasgan) with an age range

of 40 to 70 years were selected. The selected images for this study should include the mandible, have a suitable quality with no artifacts that may affect the anatomy of the area being studied, these images were related to patients with partial edentulism for less than 2 years in the region of all mandibular molars (6th, 7th, 8th) and without the use of a partial prosthesis (1). Images of patients with congenital and developmental disorders, abnormal morphology caused by trauma and pathological conditions affecting the target area were excluded from the study.

The images were captured using a Galileo device (Sirona, Germany, Bensheim) with exposure conditions of 85 kV, 21 to 35 MAP seconds and FOV of 15 x 15 cm.

All observations were made on a 22-inch flat panel LED monitor LG 22MP57HQ (LG Electronics, Iran, Tehran) with a resolution of 1920x1080, screen refresh Rate 60Hz and (32bit) true color under the supervision of a maxillofacial radiologist.

In the Cybermed Inc. software, Seoul, Republic of Korea (OnDemand 3D) the canal position was first determined in the reconstructed panoramic image (Figure 1). The submandibular gland fossa area was examined in cross-sectional sections at 1 mm intervals and with a thickness of 1 mm. The height and depth of the fossa in the edentulous area of the first molar and second molar of the mandible were measured and the highest height and the deepest point were recorded (5).

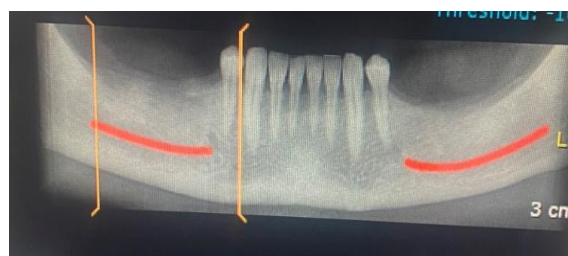

Figure 1. Mapping mandibular canal in posterior edentulous area

To determine the height of the submandibular concavity, a line was drawn from the most prominent upper part on the lingual surface of the mandible to the most prominent inferior part on the lingual surface of the mandible (Figure 2) and the maximum rate was reported as the height of the submandibular concavity (9, 10). The data were also classified based on gender in the present study.

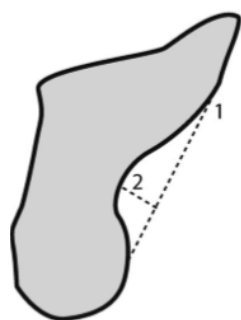


Figure 2. 1) Line connecting the most prominent upper part and the most prominent lower points of the submandibular gland fossa (height). 2) Another line drawn perpendicular to first line and (depth) of submandibular gland fossa.

To determine the depth of the submandibular fossa, two lines were drawn on cross-sectional images. The first line was drawn from the most prominent upper part to the most prominent inferior part on the lingual surface of the mandible in each slice. The second line was perpendicular to the first line from the deepest point of the fossa, and the length of the second line was measured as the depth of the area. The depth was divided into three subgroups based on depth. Type 1 (<2 mm), type 2(2-3 mm) and type 3(>3 mm) (Figure 3) (1, 4).

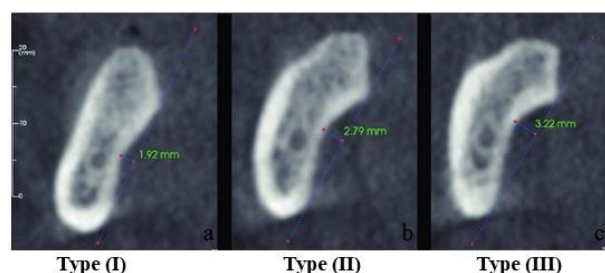


Figure 3. Submandibular fossa types based on depth in cross-sectional sections in CBCT images

The deepest submandibular point of the gland fossa was examined relative to the position of the mandibular canal and divided into three subgroups (Figure 4) (4, 5).

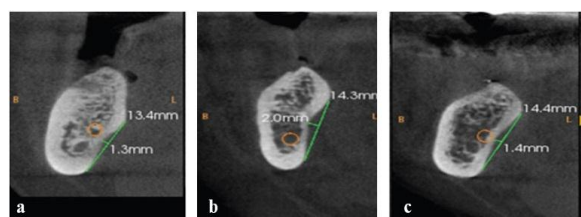


Figure 4. The position of the deepest fossa point compared to the inferior alveolar canal was classified into the following three groups: Superior relation (a) Parallel relation (b) Inferior relation(c).

Superior relation: The mandibular canal is located above the deepest submandibular gland fossa.

Parallel relation: The mandibular canal is located adjacent to the deepest point of the submandibular gland fossa.

Inferior relation: the mandibular canal is located below the deepest point of the submandibular gland fossa To investigate the submandibular gland fossa concavity, first a line was drawn to connect the upper and inferior points of the submandibular gland fossa (Line A). The second line was perpendicular to line A from the deepest point (Line B). Line C was drawn perpendicular to the horizon and tangentially to the upper point of the submandibular gland fossa. Then, line D was drawn to connect the upper point and the deepest point of the fossa. Lines E and F were also drawn tangentially to the upper and lower walls of the canal and parallel to the horizon. Finally, the angle between lines C and D was measured (Beta angle) (Figure 5) (5).

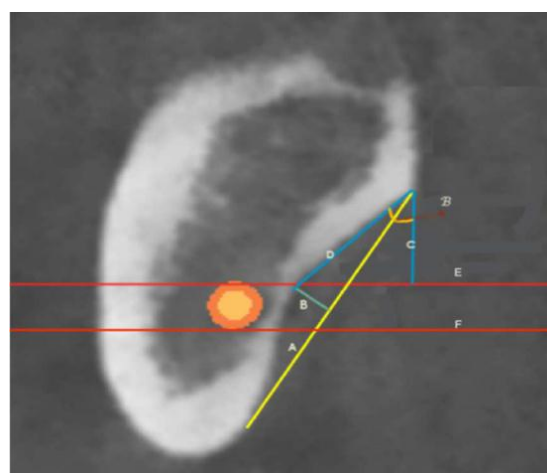


Figure 5. A cross-sectional view of the submandibular gland fossa A) Connecting the upper and lower points of the submandibular gland fossa. B) The deepest point of the submandibular gland fossa is perpendicular to Line A. C) The line is perpendicular to the horizon and tangential to the upper point of the submandibular gland fossa. D) Connecting the upper and deeper points of the submandibular gland fossa. E) The line is tangential to the upper wall of the canal, and parallel to the horizon F) The line is tangential to the lower wall of the canal, and parallel to the horizon

To determine the starting point of the fossa undercut, another line was drawn parallel to the E line and tangentially to the alveolar crest (Line G). This line was divided into coronal one third, middle, and apical one third regions based on the distance between the E and G lines (Figure 6) (5).

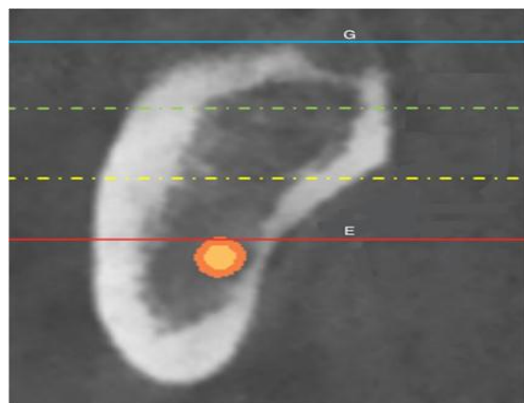


Figure 6. Categorizing the starting point of the undercut. G) The line is tangential to the Alveolar crest, and parallel to the horizon.

After collecting the data, the depth and height of the fossa and the relationship between the deepest point of the fossa to mandibular canal, and the angle of the fossa were evaluated. The starting point of the undercut was also determined.

Statistical analysis was conducted using independent t-tests, Fisher's exact test, chi-square, and Pearson's correlation coefficient in SPSS ver. 26. A $P < 0.05$ was considered the statistically significant.

Results

The study showed that the mean height and depth of the submandibular concavity in men were significantly higher than women ($p < 0.001$) (Table 1).

Table 1. The mean height and depth of the submandibular fossa (mm) between men and Female

	Gender	No	Mean \pm SD	Min	Max	P value
height	male	60	12.98 ± 2.00	8.85	18.45	<0.001
	Female	70	11.48 ± 1.97	8.00	15.91	
	total	130	12.17 ± 2.11	8.00	18.45	
depth	male	60	1.65 ± 0.57	0.81	3.12	<0.001
	Female	70	1.30 ± 0.39	0.58	2.32	
	total	130	1.46 ± 0.51	0.58	3.12	

Submandibular fossa depth less than 2 mm was seen in women more frequently than in men, and the concavity depth of 2-3 mm was observed in men more frequently than in women ($p = 0.008$) (Table 2).

Table 2. Frequency distribution depth of the submandibular 15 to 20 ° in men and Female

depth of submandibular	male No (%)	Female No (%)	total No (%)	P value
less than 2 mm (type I)	44 (73.3)	65 (92.9)	109 (83.8)	0.008
2-3 mm (type II)	14 (23.3)	5 (7.1)	19 (14.6)	

more than 3 mm (type III)	2 (3.3)	0 (0.0)	2 (1.5)
total	60 (100.0)	70 (100.0)	130 (100.0)

The Pearson correlation coefficient test revealed a significant relationship moderate positive correlation) between the height and depth of the submandibular fossa ($p < 0.001$, $r = 0.417$). This means that as the concavity deepens, the amount of height also increases.

Furthermore, there was a positive and significant relationship between the depth and height of the submandibular fossa in men (weak correlation) ($p = 0.050$, $r = 0.254$) and women (moderate positive correlation) ($p < 0.001$, $r = 0.462$) (Table 3).

Table 3. The relationship between the height and depth of the submandibular fossa

Gender	No	Pearson correlation coefficient	P value
male	60	0.254	0.050
Female	70	0.462	<0.001
total	130	0.417	<0.001

There was no significant difference between men and women in terms of the mean angle of the submandibular fossa ($p = 0.187$) (Table 4). However, there was a positive and significant relationship between the depth and angle of the submandibular fossa (moderate positive correlation) ($p < 0.001$, $r = 0.529$). This means that the angle was greater with increasing concavity depth. This positive and significant relationship (moderate positive correlation) between the depth and angle of the submandibular fossa was observed both in men ($r = 0.558$, $p < 0.001$) and women ($r = 0.491$, $p < 0.001$) (Table 5).

Table 4. The mean angle of the submandibular fossa (in degrees) in men and women

Gender	No	Mean \pm SD	min	Max	P value
male	60	32.84 ± 8.27	15.90	53.10	0.187
Female	70	31.01 ± 7.51	15.00	48.90	
total	130	31.86 ± 7.89	15.00	53.10	

Table 5. The Relationship between depth and angle of submandibular fossa

Gender	No	Pearson correlation coefficient	P value
male	60	0.558	<0.001
Female	70	0.491	<0.001
total	130	0.529	<0.001

The study also revealed that the deepest point of submandibular gland fossa on both sexes were located above the canal, and there was no significant difference between the sexes ($p = 0.858$) (Table 6)

Table 6. The position of the mandibular canal with the deepest part of the submandibular fossa in men and women

position	Male	Female	total	P value
	No (%)	No (%)	No (%)	
parallel	25 (41.7)	26(37.1)	51(39.2)	0.858
lower	34(56.7)	43(61.4)	77(59.2)	
upper	1(1.7)	1(1.4)	2(1.5)	
Total	60(100.0)	70(100.0)	130(100.0)	

The most common starting point of the concavity was the middle one-third in both male and female patients. The frequencies of the starting point of the concavity, based on the sex and side, are shown in (Table 7) (p=0.211).

Table 7. Distribution of starting point of undercut on CBCT cross-sections in men and women

concavity	Male	Female	total	P-value
	No (%)	No (%)	No (%)	
upper	8 (13.3)	16(22.9)	24(18.5)	0.211
middle	43(71.7)	40(57.1)	83(63.8)	
lower	9(15.0)	14(20.0)	23(17.7)	
Total	60(100.0)	70(100.0)	130(100.0)	

Discussion

In the present study, the anatomical variation of the submandibular fossa was investigated on CBCT images of implant candidates. Our findings showed that the average height of the submandibular fossa in men was significantly higher than that of women, and the height increased with an increase in the concavity depth. In Chan et al.'s study (9), the average height of the submandibular fossa was higher in male patients, although this study was conducted on African Americans and focused on the edentulous area of the first molar. While in the present study, the deepest edentulous area was measured in the molar area. Similarly, the average height of the submandibular fossa in the edentulous and dentulous area of the first molar was higher in male patients in a study performed by Kamburoglu et al. (8). In general, it is ideal to place implants in the direction of the longitudinal axis of the occlusal forces in the posterior region of the mandible, at a low submandibular fossa height and depth (type I). However, in cases where the height of the submandibular fossa is high (type II, III) the implant should be placed with 15 to 20 ° of lingual angle (Figure 7).

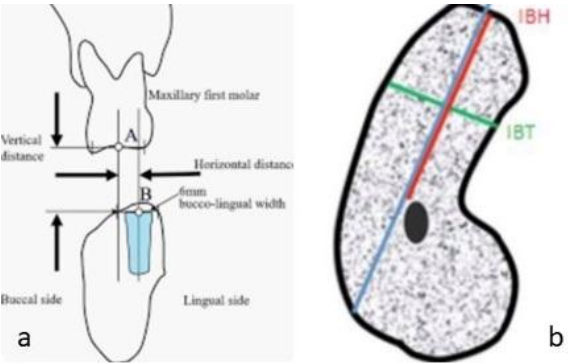


Figure 7. Insertion of implants in the direction of the longitudinal axis of occlusal forces. Placement of implants with maximum 20 degrees of lingual angle, more than this amount is associated with the risk of perforation of the buccal cortex (blue line)

Based on the findings of this study, the mean depth of the submandibular fossa was significantly greater in men compared to women. Additionally, women were more likely to have a concavity depth of less than 2 mm (type I) while men were more likely to have a concavity depth of 2-3 mm (type II) These results align with previous research (4-10) and suggest that hormonal differences may play a role in the increased concavity depth in men. Therefore, when placing implants, it's important to carefully evaluate the thickness of the alveolar bone in male patients (9). It should be noted that, the average submandibular concavity depth both in male and female patients in the present study was lower than the study by Parnia et al. (11) and Kamburoglu et al. (8), which could be due to different measurement methods, imaging techniques, sample selection and mainly different anatomical features in among different populations. The mean depth of the submandibular concavity was similar in male and female patients of the studies by Chan et al. (10) and Nilsun et al. (12). In a study conducted by Saraswathi Gopal & Sushmith (13), woman had a significantly higher mean depth of the submandibular concavity than men, which contradicts the findings of present study. This inconsistency may be explained by racial differences and anatomical features among different populations. According to the results of the present study, the most frequent submandibular gland fossa depth included type I (less than 2 mm), type II (2-3 mm) and type III (more than 3 mm), which is consistent with the results of studies by Panjnoush et al. (6), Sumer et al. (14) and Borahan et al. (7). However, in Rajput et al.'s study (1), the most frequent submandibular gland fossa depth was type II followed by type III, while in Parnia et al.'s study (11), it was type II and type I.

According to the findings of the present study, there was no significant difference between men and women in terms of mean angle of the submandibular fossa, and the angle increased with an increase in concavity depth, which is consistent with the results of the study by Panjnoush et al. (6). However, in Haghanifar et al.'s study (5), the concavity angle of the submandibular fossa was higher in male patients than in female patients, that is, it increased with an increase in the depth of the submandibular fossa. Chan et al.'s study found that (10), although the mean submandibular fossa depth was similar in male and female patients, the mean concavity angle was greater in male patients. The studies by Saraswathi Gopal & Sushmith (13), showed that the angle of the submandibular fossa in women was significantly larger. The difference in the results could be related to racial differences and anatomical variations in different populations.

The reasons for the difference in the results of the studies can be attributed to various factors, including differences in races: Japanese in the study by Watanabe et al. (15), African Americans in the study by Chan et al. (10), a population from India in the study by Saraswathi Gopal & Sushmith (13), examination of dentulous areas and partial or complete edentulous areas in the study by Watanabe et al. (15), dentulous and edentulous areas in the study by Kamburoglu et al. (8), partial edentulous patients in the study by Chan et al. (10), both partial and complete edentulous groups in the study by Haghanifar et al. (5), and only partial edentulous area where all molars are missing in the present study. various imaging methods (medical CT scan in the study by Parnia et al. (11) and Watanabe et al. (15) versus CBCT in other groups and differences in measurement methods and the duration of toothlessness (it should not exceed 2 years in the present study and the one by Rajput et al. (1), different age groups (the 40-70-year-old-year age group in the present study, 16-70-year-old-year age group in the study by Ramaswamy et al. (4), 19-71-year-old-year age group in the study by Kamburoglu et al. (8), and 23-70-year-old-year age group in the study by Chan et al. (10). According to the results of the present study, there was no significant correlation between the location of the mandibular canal with the deepest part of the mandibular fossa and gender, and the point of the submandibular fossa was above the dentoalveolar canal (inferior relation) in most cases, which is consistent with the studies by Chan et al. (10), Haghanifar et al. (5) and Saraswathi Gopal &

Sushmith (13). Since most implant surgeries are performed about 2 mm above the alveolar canal, the inferior relation that was present in most individuals is less challenging for implant surgery. However, the distance to the nerve canal during implant surgery is challenging in the medial and superior relations, in addition to the depth of the submandibular gland fossa. However, in the study of Ramaswamy et al. (4), the medial and inferior relations were more common in women and men, respectively.

According to the results of the present study, there was no significant relationship between the starting point of the undercut on CBCT cross-sections and gender. It was also found that the starting point of the undercut on CBCT cross-sections was in the middle 1.3, which was consistent with previous research. (4, 5). The starting point of the inferior undercut is less challenging for implant surgery because it allows higher implant placement, but when it is medial and superior, the risk of perforation is higher.

Conclusion

According to the results of the present study, the average submandibular gland fossa depths is greater in men compared to women, which is associated with an increased risk of lingual perforation. Also, with the increase in the depth of the submandibular concavity, the angle and height of the concavity increased. Therefore, it is important to measure bone thickness and evaluate the submandibular gland fossa concavity in the posterior regions of the mandible, particularly in men, during implant treatment. The dimensions and anatomy of the submandibular gland fossa can be evaluated best through cross-sectional imaging. Hence, adequate information about the morphological and anatomical characteristics of this area is crucial in preventing cortical perforation of the lingual plate during implant treatment.

Conflict of Interests: The authors of this manuscript declare that they have no conflicts of interest, real or perceived, financial or non-financial in this article.

References

1. Rajput BS, Merita S, Parihar AS, Vyas T, Kaur P, Chansoria S. Assessment of Lingual Concavities in Submandibular Fossa Region in Patients requiring Dental Implants-A Cone Beam Computed Tomography Study. *J Contemp Dent Pract.* 2018;19(11):1329-1333.

2. Nickenig HJ, Wichmann M, Eitner S, Zöller JE, Kreppe M. Lingual concavities in the mandible: a morphological study using cross-sectional analysis determined by CBCT. *J Craniomaxillofac Surg*. 2015;43(2):254-9.
3. Kalpidis CD, Konstantinidis AB. Critical hemorrhage in the floor of the mouth during implant placement in the first mandibular premolar position: a case report. *Implant Dent*. 2005;14(2):117-124.
4. Ramaswamy P, Saikiran C, Raju BM, Swathi M, Teja DD. Evaluation of the depth of submandibular gland fossa and its correlation with mandibular canal in vertical and horizontal locations using CBCT. *J Indian Acad Oral Med Radiol* 2020;32:22-6.
5. Haghanifar S, Arbabzadegan N, Moudi E, Bijani A, Nozari F. Evaluation of Lingual Mandibular Depression of the Submandibular Salivary Glands Using Cone-Beam Computed Tomography. *J Res Med Dent Sci*, 2018;6(2):563-567.
6. Panjnoush M, Eil N, Kheirandish Y, Mofidi N, Shamsiri AR. Evaluation of the concavity depth and inclination in jaws using CBCT. *Caspian Journal of Dental Research*. 2016;5(2):17-23.
7. Borahan O, Dönmez FG, Ulay G, Sadıkoğlu ANY, Pekiner FN. Assessment of submandibular fossa depth using cone beam computed tomography. *Yeditepe Dental Journal*. 2018;14(2):51-56.
8. Kamburoglu K, Acar B, Yuksel S, Paksoy CS. CBCT quantitative evaluation of mandibular lingual concavities in dental implant patients. *Surg Radio Anat*. 2015; 37 (10): 1209-15.
9. Koushal D, Tangotra A. Evaluation of the depth of submandibular gland fossa and its correlation with mandibular canal in vertical and horizontal locations using CBCT. *International Journal of Radiology and Diagnostic Imaging*. 2022;5(4):04-11.
10. Chan HL, Benavides E, Yeh CY, Fu JH, Rudek IE, Wang HL. Risk assessment of lingual plate perforation in posterior mandibular region: a virtual implant placement study using cone-beam computed tomography. *J Periodontol*. 2011;82(1):129-35.
11. Parnia F, Fard EM, Mahboub F, Hafezeqoran A, Gavvani FE. Tomographic volume evaluation of submandibular fossa in patients requiring dental implants. *Oral Surg Oral Med Oral Pathol Oral Radiol Endod*. 2010;109(1):e32-6.
12. Nilsun B, Canan B, Evren H, Kaan O. Cone-Beam Computed Tomography Evaluation of the Submandibular Fossa in a Group of Dental Implant Patients. *Implant Dent*. 2019;28(4):329-339.
13. Saraswathi Gopal K, Sushmith.S. Assessment of Submandibular Fossa for Dental Implants – A Retrospective 3 Dimensional Cone Beam Computed Tomographic Study. *International Journal of Current Advanced Research*. 2018;7(12):16632-35.
14. Sumer AP, Zengin AZ, Uzun C, Karoz TB, Sumer M, Danaci M. Evaluation of submandibular fossa using computed tomography and panoramic radiography. *Oral Radiol* 2015;31:23-7.
15. Watanabe H, Mohammad Abdul M, Kurabayashi T, Aoki H. Mandible size and morphology determined with CT on a premise of dental implant operation. *Surg Radiol Anat* 2010; 32: 343-349.