



Oral Lichen Planus-induced Fibrotic Changes. A pilot Retrospective Study

Ali Foroughi¹, Maryam Kamranzadeh², Atousa Aminzadeh^{3*}

Received: 2024-08-13/ Accepted: 2025-01-04 / First publication date: 2025-05-20

© The Author(s) 2025

Abstract

Background: Limited research has assessed the severity of fibrotic connective tissue in oral lichen planus (OLP) and its potential correlation with trismus, a clinical manifestation observed in some patients. Therefore, the objective of this study was to evaluate the presence of fibrosis in individuals diagnosed with OLP.

Materials and methods: This retrospective cross-sectional study evaluated 26 biopsy samples of oral lichen planus (OLP), focusing on the reticular and erosive forms. Only lesions from the buccal mucosa were included to avoid histological variability. Densities of collagen, inflammation, and blood vessels were assessed by light microscopy of hematoxylin and eosin (H&E)- stained slides. Measurements of the fibrotic band were obtained from photographs. Data analysis utilized the Mann-Whitney test, chi-square test, and Fisher's exact test in SPSS software version 27, with a significance level set at $\alpha = 0.05$

Results: The mean thickness of the subepithelial fibrotic band in samples of reticular oral lichen planus was 957.11 ± 588.71 micrometers. The mean thickness of subepithelial fibrotic tissue in samples of erosive oral lichen planus was 1155.75 ± 810.41 micrometers. No significant difference in the thickness of subepithelial fibrotic tissue was observed between reticular and erosive oral lichen planus samples ($p = 0.426$).

Conclusion: Fibrotic changes associated with oral lichen planus are not related to clinical subtype, inflammation, or blood vessel density. It is recommended to conduct additional studies, particularly involving OLP patients presenting with clinical trismus, to enhance the understanding of this phenomenon.

Key words: oral lichen planus, myofibroblast, fibrosis, lymphocyte

Introduction

Oral lichen planus (OLP) is a chronic inflammatory condition that affects the oral mucosa with or without skin involvement (1). It is primarily characterized by T-cell infiltration, although the exact cause of this disease remains unclear (2,3). Among the various forms of OLP, the reticular type is the most commonly encountered. This variant presents as a network of white keratotic lines known as Wickham's striae,

bordered by an area of erythema. These characteristic white lines are usually asymptomatic, observed bilaterally on the buccal mucosa, within mucosal folds, and along the gums, though they can also appear less frequently on the tongue, palate, and lips (4, 5). Erosive lichen planus, the second most common type of disease, is distinguished by the presence of erythematous and ulcerated areas encircled by fine radiating keratotic lines (1). Fibrosis is usually characterized by an excessive buildup of collagen in the connective tissue. It can result from various factors, including chronic infections, autoimmune reactions, allergic responses, radiation exposure, tissue damage, and natural aging (6). Various mechanisms are involved in this process, including a

Corresponding author: Atousa Aminzadeh

Department of Oral & maxillofacial pathology, Faculty of Dentistry, Isf.C, Islamic Azad University, Isfahan, Iran.
Email:aminzadeh@iau.ac.ir

1 Faculty of Dentistry, Isf.C, Islamic Azad University, Isfahan, Iran.

2 Department of Oral & maxillofacial pathology, Faculty of Dentistry, Isf.C, Islamic Azad University, Isfahan, Iran.

3 Department of Oral & maxillofacial pathology, Faculty of Dentistry, Isf.C, Islamic Azad University, Isfahan, Iran.

group of connective tissue cells known as myofibroblasts. Myofibroblasts are specialized cells that contain actin and play an essential role in the body's response to injury. They can also play a pathological role in inflammatory conditions, such as fibrosis and cancer. Upon activation, myofibroblasts serve as the primary cells responsible for collagen production. These cells can arise from mesenchymal, epithelial, and endothelial cells. The transformation of these cells into myofibroblasts can be triggered by lymphocytes and macrophages (6, 7). Another possible factor contributing to tissue fibrosis is a type of cell known as a Mast cell. These cells play a significant role in initiating fibrosis across various organs. According to studies, mast cells are involved in the pathogenesis of OLP (2). Tryptase, a substance released by mast cells, induces processes such as proliferation, chemotaxis, collagen synthesis, and migration in human fibroblasts. Collectively, these processes might contribute to the development of fibrosis in oral lichen planus (8). OLP is recognized as a chronic condition characterized by mucosal inflammation, which can persist for many years and may lead to mucosal fibrosis. However, Steiner et al. suggest that this phenomenon has not yet been clearly documented in cases of oral lichen planus. (8). Recent research has identified several cytokines and chemokines produced in OLP as significant regulators of fibrosis in some clinical subtypes of OLP, commonly referred to as Oral Lichen Planus-induced Fibrotic Changes (OLPFCs). Patients with oral lichen planus (OLP) often experience severe trismus, defined as a mouth opening of less than 35 mm. This condition can lead to a lower quality of life, and some patients may require treatment. A key finding from prior studies is that approximately one-third of OLP patients eventually develop clinically palpable fibrous bands. Besides restricting mouth opening, these fibrotic bands, resulting from OLP, can lead to diminished

vestibule depth and gingival erosion around the bands. Additionally, fibrosis might have a role in the development of malignancy associated with OLP. (8-10) The present study aimed to histologically investigate and compare the thickness of fibrotic connective tissue in reticular and erosive OLP lesions.

Material and methods

In this cross-sectional retrospective study with ethical code IR.IAU.KHUISF.REC.1403.093, 26 biopsy samples with clinicohistopathologic diagnosis of erosive and reticular OLP were extracted from the oral pathology archive. To minimize histological bias across oral sites, only lesions from the buccal mucosa were included in the study, while lesions from other sites were excluded. H&E-stained slides were assessed at 10x magnification using a Nikon Eclipse optical microscope (Japan). An image was taken from each slide using a Nikon Digital Sight microscope. To eliminate observer bias, one pathologist performed the microscopic evaluation.

The thickness of the subepithelial fibrotic layer was assessed by measuring the distance from the basement membrane of the epithelium to the upper boundary of the adipose layer at three distinct locations on each slide, expressed in micrometers (Figure. 1).

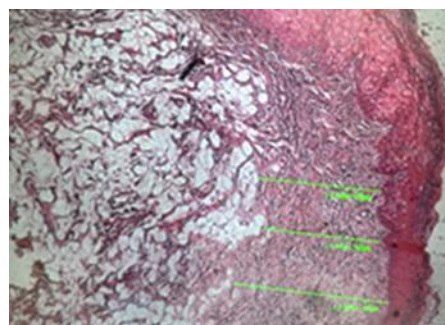


Figure1. Green lines show the distance measured for evaluation of the subepithelial fibrotic band, to show the connective tissue better. This picture was taken from a region without an inflammatory infiltrate. (H&E 100)

The evaluation of lymphocytic infiltration was conducted in three consecutive high-power fields without overlap as follows: infiltration composed of fewer than 20 lymphocytes was assigned grade 1, infiltration between 20 and 50 lymphocytes was assigned grade 2, and infiltration exceeding 50 lymphocytes was assigned grade 3 (11). The grading for collagen types was as follows: loose collagen, 1; medium collagen, 2; and hyalinized collagen, 3. The density of blood vessels was assessed in three consecutive high-power fields without overlap, with fewer than 10 vessels rated as grade 1 and more than 10 vessels rated as grade 2 (11). Data were analyzed using Mann-Whitney, chi-square, and Fisher's exact tests in SPSS software version 27 ($\alpha=0.05$).

Results

The mean thickness of subepithelial fibrotic tissue in reticular oral lichen planus samples was 957.11 ± 588.71 micrometers. The mean thickness of subepithelial fibrotic tissue in erosive oral lichen planus samples was 1155.75 ± 810.41 micrometers. According to the Mann-Whitney test, there was no significant difference in the thickness of the subepithelial fibrotic tissue between reticular and erosive oral lichen planus samples ($p=0.426$). (Table 1)

Table 1. Comparing the thickness of sub-epithelial fibrotic tissue between groups

Type	N	Mean \pm SD	Min.	Max.	P value
Reticular	13	957.11 ± 588.71	444.90	2746.98	0.426
Erosive	13	1155.75 ± 810.41	546.30	3545.71	

Collagen density in reticular oral lichen planus samples was reported loose in 4 samples (30.8%), moderate in 8 samples (61.5%), and hyalinized in one sample (7.7%) and in erosive oral lichen planus samples collagen density was reported loose in 5 samples (38.5%), moderate in 6 samples (46.2%), and hyalinized in 2 samples (15.4%) as shown in Fig 2.

There was no significant difference in collagen density between reticular and erosive oral lichen planus samples ($p=0.751$).

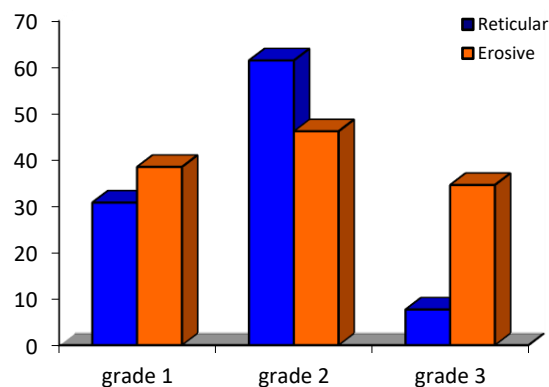


Figure 2 . Comparing the collagen density of sub-epithelial fibrotic tissue between groups

The density of blood vessels in reticular oral lichen planus samples was less than 10 vessels in 6 samples (2.46%) and more than 10 vessels in 7 samples (8.53%). The density of blood vessels in erosive oral lichen planus samples was less than 10 vessels in 7 samples (8.53%) and more than 10 vessels in 6 samples (2.46%). A significant difference in the number of blood vessels between reticular and erosive OLPs was not observed ($p=0.695$).

In terms of lymphocyte density in reticular oral lichen planus samples, infiltration was composed of less than 20 lymphocytes in 4 samples (30.8%), infiltration was between 20 and 50 lymphocytes in 4 samples (30.8%), and infiltration was greater than 50 lymphocytes in 5 samples (38.5%). In the samples of erosive oral lichen planus, in 2 samples (15.1 %) infiltration was less than 20 lymphocytes, in 2 samples (15.1%) infiltration was between 20 and 50, and in 9 samples (69.2 %) infiltration was more than 50 lymphocytes. Based on the result, there was no significant difference in lymphocyte density between reticular and erosive oral lichen planus samples ($p=0.373$). Statistical tests showed a significant relationship between collagen density and blood vessels in erosive lichen planus

samples ($p=0.008$). However, a significant relationship between collagen density and blood vessels in reticular lichen planus samples was not seen ($p=0.559$). Based on the results of the study, no significant relationship between collagen density and lymphocyte density was observed in erosive ($p=0.860$) and reticular ($p=1.00$) OLP samples.

Discussion

The purpose of this study was to investigate fibrotic changes in tissue samples induced by oral lichen planus. Fibrosis usually results from chronic inflammation, an immune response that persists for several months, during which inflammation, tissue remodeling, and repair processes occur simultaneously (8,9). According to a 2018 study by Mo et al. (12), damage to epithelial cells can lead to the release of a series of inflammatory mediators, including fibrogenic cytokines. On the other hand, lymphocytes also secrete factors that promote fibrosis, such as TGF- β and interleukin 13, which activate macrophages and fibroblasts. According to a study by Hasegawa et al. (13), B lymphocytes are among the key cells that drive fibrosis in inflammatory lesions by producing fibroblast growth-stimulating factors. In the study by Conti et al. (14), it was reported that mast cells stimulate fibroblasts to produce more collagen fibers. In our study, no relationship was found between fibrosis and the inflammatory infiltrate. In the present study, significant fibrotic tissue was seen in all cases of oral lichen planus. Based on the obtained results, there was no significant difference in the thickness (distance from the subepithelium to the submucosa) of this fibrotic tissue and the density of collagen fibers (loose and hyalinized) between reticular and erosive oral lichen planus samples. These results support the study's hypothesis, which found that the thickness of the fibrotic layer is greater in the erosive type than in the reticular type.

Statistical analysis revealed a significant relationship between collagen density and blood vessel prevalence in samples of erosive lichen planus. Although in reticular lichen planus, this relationship was not statistically significant. The statistical analysis of data from samples of erosive and reticular lichen planus did not reveal a significant correlation between collagen density and lymphocyte density. Although no previous studies have examined this, it is worth noting that a decrease in blood vessel density often accompanies an increase in collagen density. This reduction in blood flow may help explain the lower lymphocyte density observed in advanced cases of lichen planus.

The research findings suggest that fibrosis is likely present in patients with oral lichen planus; however, it does not appear to be directly linked to inflammatory density or the number of blood vessels. This indicates that the development of fibrosis in lichen planus is more complex than merely being associated with inflammation, particularly in relation to the types of inflammatory cells involved in fibrosis (B cells) and OLP (T cells). The results of the present study suggest that fibrosis and subsequent trismus in patients with Oral Lichen Planus (OLP) may be associated with mast cells and myofibroblasts, as reported by Wang et al. (7) OLP fibroblasts exhibit significantly higher levels of α -smooth muscle actin, a marker indicating the presence of myofibroblasts. These cells secrete pro-inflammatory cytokines, such as Interleukin (IL)-6, IL-8, and tumor necrosis factor-alpha (TNF- α), in response to stimuli such as *Porphyromonas gingivalis* lipopolysaccharide. Therefore, if we consider myofibroblasts responsible for tissue fibrosis, it can be concluded that this condition, along with trismus, may occur more frequently in OLP patients with poor oral hygiene, and this should be emphasized in OLP patients (7,2,13,15).

Conclusion

The thickness of subepithelial fibrosis in oral lichen planus (OLP) was unrelated to the clinical subtype. There were no significant differences in the intensity of lymphocytic infiltration or the number of blood vessels among the studied groups. This was a retrospective archival study, so the authors did not have access to patients. Further research, including clinical evaluations and studies on the role of myofibroblasts, is strongly recommended to understand this phenomenon better. Meanwhile, patients should be advised to maintain proper oral hygiene and gingival health.

Conflict of Interests: The authors of this manuscript declare that they have no conflicts of interest, real or perceived, financial, or non-financial in this article

References

1. Aminzadeh A, Jahanshahi G, Ahmadi M. A retrospective comparative study on clinico-pathologic features of oral lichen planus and oral lichenoid lesions. *Dent Res J (Isfahan)*. 2013;10(2):168-72.
2. Jahanshahi G, Aminzadeh A. A histochemical and immunohistochemical study of mast cells in differentiating oral lichen planus from oral lichenoid reactions. *Quintessence Int*. 2010;41(3):221-7.
3. Zoodashena P, Hoveida L, Aminzadeh A. A Comparative Study on the Prevalence of HPV16 Virus in Oral Lichen Planus and Oral Lichenoid Lesions Using PCR Technique. *Jundishapur Scientific Medical Journal*, 2022; 21(5): 628-637.
4. Saharkhiz A, Aminzadeh A, Yahyaabady R. A Histomorphology Comparison of Saw-Tooth Shaped Rete Ridge Between Oral and Cutaneous Lichen Planus. *Enviro Dental Journal* 2022; 4(1):20-24
5. Aminzadeh A, Razavi S.M, Sabeti S.A. Immunohistochemical Evaluation of Expression of CK19 Premalignant Indicator in Oral Lichenoid Reaction (OLR) Compared to Oral Lichen Planus (OLP), Oral Squamous Cell Carcinoma (OSCC) and Normal Oral Mucosa. *J Isfahan Dent Sch*. 2018; 14(1): 17-28.
6. Wynn TA. Cellular and molecular mechanisms of fibrosis. *J Pathol*. 2008;214(2):199-210.
7. Wang L, Yang Y, Xiong X, Yu T, Wang X, Meng W, et al. Oral lichen-planus-associated fibroblasts acquire myofibroblast characteristics and secrete pro-inflammatory cytokines in response to *Porphyromonas gingivalis* lipopolysaccharide stimulation. *BMC Oral Health*. 2018 ;18(1):197.
8. Shteiner M, Kleinman S, Shuster A, Raiser V, Ianculovici C, Rachima H, et al. Submucosal Fibrotic Bands in Oral Lichen Planus: A Clinico-Pathological Investigation of a Newly Described Phenomenon. *Head Neck Pathol*. 2021;15(2):395-401.
9. Shudo A. Histopathological specialized staining of oral lichen planus-induced fibrotic changes and surgical treatment of associated restricted mouth opening: a case report. *Shudo Bull Natl Res Cent* 2021; 45(56):1-6.
10. Shen YW, Shih YH, Fuh LJ, Shieh TM. Oral Submucous Fibrosis: A Review on Biomarkers, Pathogenic Mechanisms, and Treatments. *Int J Mol Sci*. 2020;21(19):7231
11. Yadegari A, Aminzadeh A, Seyyedkhamesi S, Aminian M. The effect of melatonin on prevention of bisphosphonate-related osteonecrosis of the jaw: an animal study in rats. *J Korean Assoc Oral Maxillofac Surg*. 2020; 46(4):266-274.
12. Li MO, Wan YY, Sanjabi S, Robertson AK, Flavell RA. Transforming growth factor-beta regulation of immune responses. *Annu Rev Immunol*. 2006;24:99-146.
13. Hasegawa M, Fujimoto M, Takehara K, Sato S. Pathogenesis of systemic sclerosis: altered B cell function is the key linking systemic autoimmunity and tissue fibrosis. *J Dermatol Sci*. 2005 Jul;39(1):1-7.
14. Conti P, Caraffa A, Mastrangelo F, Tettamanti L, Ronconi G, Frydas I, et al. Critical role of inflammatory mast cell in fibrosis: Potential therapeutic effect of IL-37. *Cell Prolif*. 2018;51(5):e12475.
15. Faraji Z, Shirani AM, Rezaei Mirghayed N. Evaluation of Factors Associated with the Onset or Aggravation of Oral Lichenoid Reactions in Isfahan City of Iran. *cofs* 2025;3 (2):1-5.